



**PATIENT**

Ahsoka Kor

**SPECIES**

Canine

**BREED**

Mini Aussie

**SEX**

Female

**AGE**

8 Months

**WEIGHT**

28 Pounds

**INTERPRETED BY**

Eric Lindquist, DMV  
DABVP, Cert. IVUSS

**IMAGING PERFORMED BY**

Dr. Petrina Patete

**HOSPITAL NAME**

Mountain View VH

**REFERRING VET**

Dr. Petrina Patete

**INVOICE**

26595

**DATE**

10/21/21

**PRESENTING CLINICAL SIGNS**

Practice SDEP US. Currently in estrus. When she was 16wk old she had a bout of pollakiuria and had "ghosts" on US of bladder. Cultured negative but had pyuria and was treated for vaginitis and signs resolved. Recheck UMIC / UA by cysto was WNL after Amoxicillin. No further urinary signs. Abnormal PE/Chem/CBC/UA Results: Currently in heat (2 weeks)

**ULTRASONOGRAPHIC EXAMINATION OF THE ABDOMEN**

**Urinary System**

The **urinary bladder**, trigone, and pelvic urethra presented normal thicknesses and normal tone. The ureters were not visible which is normal. No uroliths or sediment were visualized and anechoic urine was present. No evidence of inflammatory or neoplastic changes were noted. Ureteral papillae were normal.

The **kidneys** revealed normal size and structure, corticomedullary definition and ratio for this age. The cortices presented largely uniform texture with normal echogenic relationship to liver and spleen. Medullary structure differed distinctly from the cortex and no evidence of pelvic dilation was present. The capsules were acceptably uniform without significant irregularities. The left kidney measured 4.0 cm. The right kidney measured 4.5 cm.

**Adrenal Glands**

The **adrenal glands** were not visualized.

**Spleen**

The **spleen** presented a smooth homogeneous parenchyma hyperechoic to liver and renal cortical parenchyma. The capsule was smooth without noticeable expansion or deviation from within the spleen or adjacent pathology. The splenic vasculature demonstrated normal volume without signs of congestion or thrombosis. No sonographic evidence of acute or chronic inflammatory, neoplastic, or infarctual changes were noted.

**Liver**

The **liver** images submitted revealed subjectively normal liver size, contour, and structure. Parenchymal echogenicity was naturally coarse and hypoechoic to the spleen. Vascular and biliary tracts were of normal volume with no evidence of congestion. The gallbladder presented acceptably thin walls with primarily anechoic content. The cystic and common bile ducts were normal. No pathological hepatic lymphadenopathy was evident. No overt structural evidence of inflammatory, infiltrative or regenerative pathology was evident.

**Gastrointestinal**

Some retention of ingesta was noted in the **stomach**. The small intestine and colon were unremarkable.

**Pancreas**

The base and limbs of the **pancreas** were observed to be largely isoechoic to surrounding omental fat. Pancreatic duct and capsular contour were acceptably normal and parenchyma respected normal curvilinear patterns. No overt evidence of active inflammatory or neoplastic disease was noted.

**Other**

The uterus was uniformly thickened in this patient, consistent with active heat cycle. The left ovary was uniform at 1.0 cm.



**PATIENT**

Ahsoka Kor

**ULTRASONOGRAPHIC FINDINGS**

- Uterus in active estrus
- Unremarkable abdomen otherwise

**SPECIES**

Canine

**INTERPRETATION OF THE FINDINGS & FURTHER RECOMMENDATIONS**

No evidence of pathology. No evidence of ectopic ureters.

**BREED**

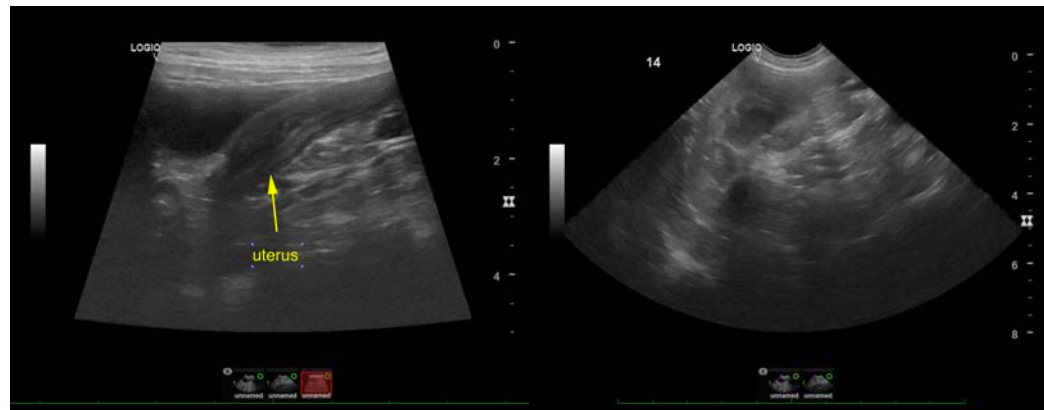
Mini Aussie

**SEX**

Female

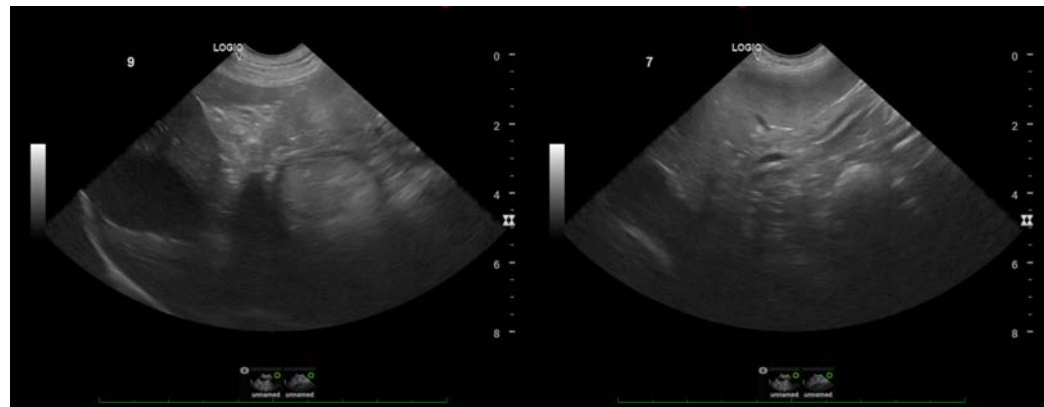
**AGE**

8 Months



**WEIGHT**

28 Pounds



**INTERPRETED BY**

Eric Lindquist, DMV  
DABVP, Cert. IVUSS

**IMAGING PERFORMED BY**

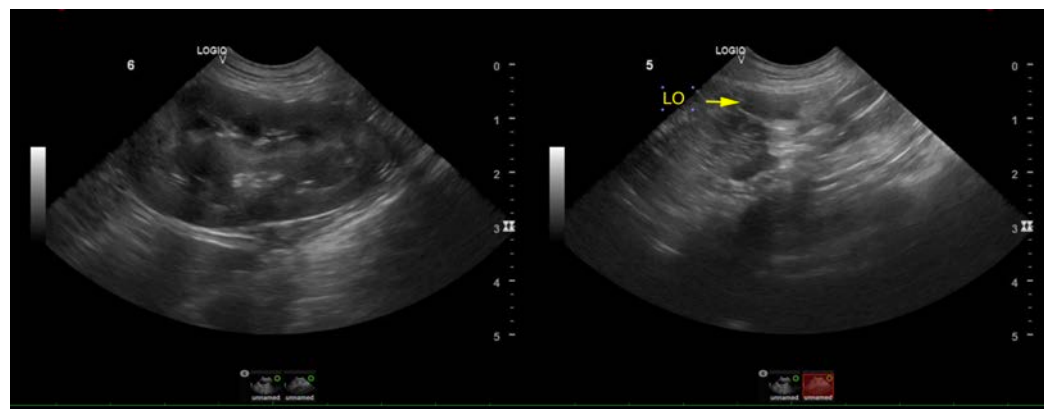
Dr. Petrina Patete

**HOSPITAL NAME**

Mountain View VH

**REFERRING VET**

Dr. Petrina Patete



**INVOICE**

26595

**DATE**

10/21/21



**PATIENT**

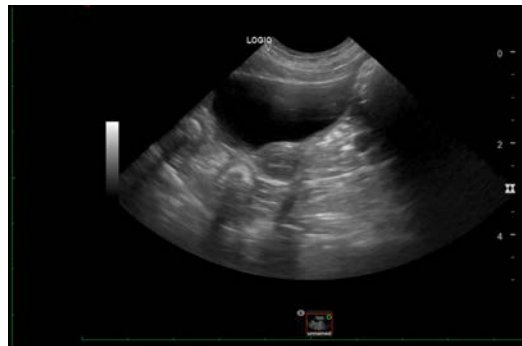
Ahsoka Kor

**SPECIES**

Canine

**BREED**

Mini Aussie



**SEX**

Female

**AGE**

8 Months

**WEIGHT**

28 Pounds

**INTERPRETED BY**

Eric Lindquist, DMV  
DABVP, Cert. IVUSS

**IMAGING  
PERFORMED BY**

Dr. Petrina Patete

**HOSPITAL NAME**

Mountain View VH

**REFERRING VET**

Dr. Petrina Patete

**INVOICE**

26595

**DATE**

10/21/21

The information and recommendations provided are based on the images presented by the referring veterinarian. No evaluation can be communicated regarding pathology that was not visible in the image/video clips provided.

Thank you for this referral. If the clinical or image interpretation does not parallel your findings or if I can be of any further assistance please contact me.

**Eric Lindquist**, DMV, DABVP, Cert. IVUSS, CEO of SonoPath.com  
[info@SonoPath.com](mailto:info@SonoPath.com)