



PATIENT

Morgen Constance

SPECIES

Canine

BREED

Mix

SEX

Neutered male

AGE

11 years

WEIGHT

22.6 lbs

PRESENTING CLINICAL SIGNS

History: recheck from yesterday showed shadowing material within the gastric lumen grass/cloth
Dog has not eaten

ULTRASONOGRAPHIC EXAMINATION

Gastrointestinal

The stomach was empty in this patient. The prior material appears to have transited from the stomach to likely the colon. The upper gastrointestinal tract was empty. There was no evidence of pathology.

ULTRASONOGRAPHIC FINDINGS

Upper gastrointestinal tract was empty.

INTERPRETATION OF THE FINDINGS & FURTHER RECOMMENDATIONS

There was no evidence of pathology.

INTERPRETED BY

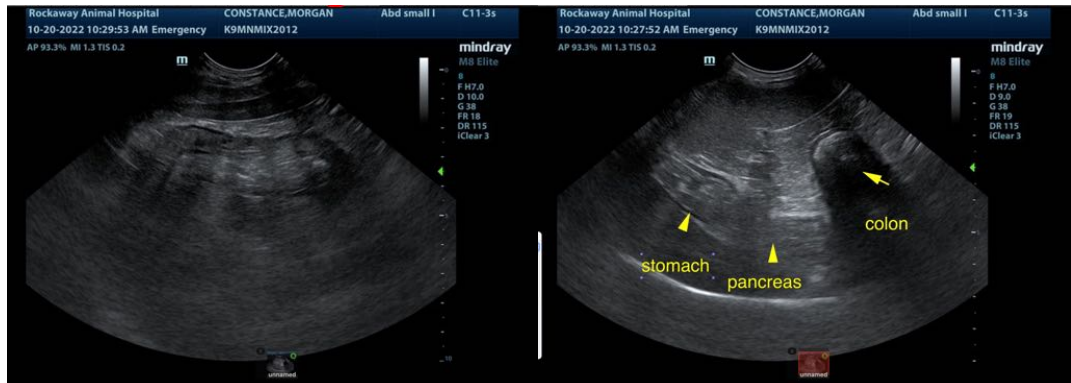
Eric Lindquist, DMV
DABVP, Cert. IVUSS

IMAGING PERFORMED BY

Jenn

HOSPITAL NAME

Rockaway AH



REFERRING VET

Dr. Maniar

The information and recommendations provided are based on the images presented by the referring veterinarian/sonographer. No evaluation can be communicated regarding pathology that was not visible in the image/video clips provided.

INVOICE

40182

Thank you for this referral. If the clinical or image interpretation does not parallel your findings or if I can be of any further assistance please contact me.

DATE

10/20/22

Eric Lindquist, DMV, DABVP, Cert. IVUSS, CEO of SonoPath.com
info@SonoPath.com