



PATIENT

Lilly Mustacchio

PRESENTING CLINICAL SIGNS

History: vomiting/coughing blood

SPECIES

Canine

ULTRASONOGRAPHIC EXAMINATION OF THE ABDOMEN

Urinary System

BREED

Shih Tzu mix

The **urinary bladder**, trigone, and pelvic urethra presented normal thicknesses and normal tone. The ureters were not visible which is normal. No uroliths or sediment were visualized and anechoic urine was present. No evidence of inflammatory or neoplastic changes was noted. Ureteral papillae were normal.

SEX

Spayed female

The **kidneys** revealed largely normal size and structure, corticomedullary definition and ratio (cortex 1/3 of medulla) were essentially maintained with some age-related loss of curvilinear patterns regarding the capsule and C/M junction. The cortices presented largely uniform texture with some increased echogenicity expected for his age patient. Medullary structure differed distinctly from that of the cortex and no evidence of pelvic dilation was present. Mineralization was noted, yet non-obstructive. The right kidney measured 3.8 cm. The left kidney measured 4.07 cm.

AGE

8 years

WEIGHT

9 lbs

Adrenal Glands

Both **adrenal glands** were visualized and recognized as having normal shape, size, position and echogenicity for this breed. The phrenic vasculature, glandular echogenicity and detail were unremarkable. Capsule, cortex, and medullary definition were normal for this age patient. The left adrenal gland measured 1.39 x 0.38 cm at the caudal pole and 0.48 cm at the cranial pole. The right adrenal gland measured 1.2 x 0.99 cm at the cranial pole and 0.45 cm at the caudal pole.

INTERPRETED BY

Eric Lindquist, DMV
DABVP, Cert. IVUSS

IMAGING PERFORMED BY

Jenn

Spleen

The **spleen** presented a smooth homogeneous parenchyma hyperechoic to liver and renal cortical parenchyma. The capsule was smooth without noticeable expansion or deviation from within the spleen or adjacent pathology. The splenic vasculature demonstrated normal volume without signs of congestion or thrombosis. No sonographic evidence of acute or chronic inflammatory, neoplastic, or infarctual changes was noted.

HOSPITAL NAME

Rockaway AH

REFERRING VET

Dr. Maniar

Liver

The **liver** images submitted revealed subjectively normal liver size, contour, and structure. Parenchymal echogenicity was naturally coarse and hypoechoic to the spleen. Vascular and biliary tracts were of normal volume with no evidence of congestion. The gallbladder presented acceptably thin walls with primarily anechoic content. The cystic and common bile ducts were normal. No pathological hepatic lymphadenopathy was evident. No overt structural evidence of inflammatory, infiltrative or regenerative pathology was evident.

INVOICE

40188

DATE

10/20/22



PATIENT *Gastrointestinal*

Lilly Mustacchio The **stomach** was mildly edematous with anechoic fluid in the lumen. This is consistent with gastritis. The small intestine and colon were unremarkable.

SPECIES

Canine *Pancreas*

BREED

Shih Tzu mix The base and limbs of the **pancreas** were observed to be largely isoechoic to surrounding omental fat. Pancreatic duct and capsular contour were acceptably normal and parenchyma respected normal curvilinear patterns. No overt evidence of active inflammatory or neoplastic disease was noted.

SEX

Spayed female

AGE

8 years

WEIGHT

9 lbs

INTERPRETED BY

Eric Lindquist, DMV
DABVP, Cert. IVUSS

IMAGING PERFORMED BY

Jenn

HOSPITAL NAME

Rockaway AH

REFERRING VET

Dr. Maniar

INVOICE

40188

DATE

10/20/22

ULTRASONOGRAPHIC EXAMINATION OF THE HEART

The **echocardiogram** presented a prominent **right heart** with mild **right ventricular** hypertrophy, with minor **tricuspid** regurgitation, but normal **right atrial** size. No evidence of neoplasia was noted in the right auricle, or elsewhere in the heart. The **pulmonary artery** was uniformly prominent with mildly depressed pulmonic velocity measured on PW Doppler. No overt heartworms were noted in the main or visible deep pulmonary arteries. Yet, theoretically heartworms could be present in the deep pulmonary vasculature out of visible sonographic range. More likely, however, this prominent right heart is due to excessive intra-thoracic pressures caused by chronic respiratory disease or potentially excessive intra-thoracic fat (Pickiwickian syndrome). The **left heart** demonstrated a linear **ventricular septum**. Contractility was functionally adequate demonstrated by the FS% measurement. The **mitral valve** was not significantly insufficient and no significant **left atrial** dilation was noted. The **left ventricular outflow** demonstrated normal flow patterns and velocities through the aortic valve. No evidence of tumor, pericardial or pleural effusion was noted. The visible **extra-cardiac** tissues were uniformly linear without evidence of masses, infiltrative or inflammatory mediastinal tissue. No evident arrhythmic activity was noted during the exam.

CANINE	MR	TR	LA/AO	LA/AO	FS	EF	EPSS
CARDIAC PARAMETERS	VMAX (m/s)	VMAX (m/s)	(Boon method)	(Heart Base; Swe)	(%)	(%)	(cm)
NORMAL PARAMETER	4.5-5.5	<2.7	1.3	<1.6	28-40	40-100	<0.6
PATIENT	NM	NM	1.15	1.3	50	90	NM
CANINE	HR	AV	PV	BODY WEIGHT	LA	LVIDd	LVIDs
CARDIAC PARAMETERS	(BPM)	VMAX (m/s)	MAX (m/s)		2D short axis Base view (cm)	Avg; 2D and m-mode short axis (cm)	Avg; 2D and m-mode short axis (cm)
NORMAL PARAMETER	50-100	0.7-1.7	0.7-1.6	BELOW	BELOW	BELOW	BELOW
PATIENT		NM	NM	9 lbs	2.0 max	2.0	



PATIENT

Lilly Mustacchio

SPECIES

Canine

BREED

Shih Tzu mix

SEX

Spayed female

AGE

8 years

WEIGHT

9 lbs

INTERPRETED BY

Eric Lindquist, DMV
DABVP, Cert. IVUS

IMAGING PERFORMED BY

Jenn

HOSPITAL NAME

Rockaway AH

REFERRING VET

Dr. Maniar

INVOICE

40188

DATE

10/20/22

ULTRASONOGRAPHIC FINDINGS

Moderate degenerative renal disease with non-obstructive nephrolithiasis.

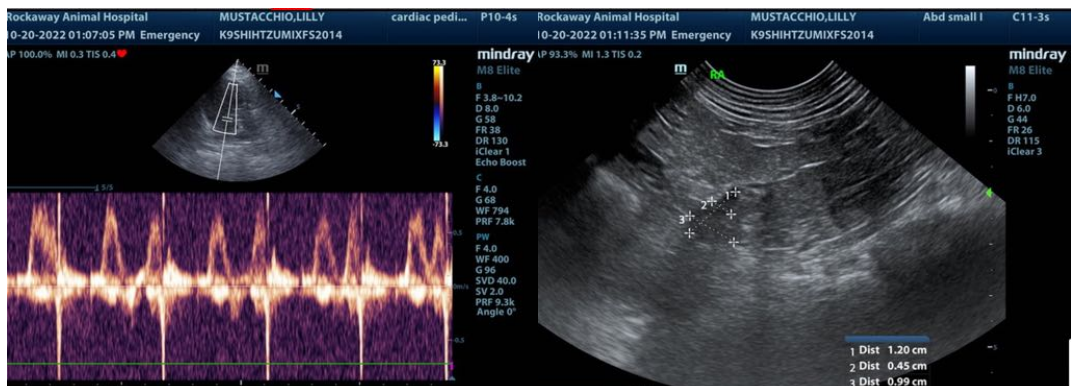
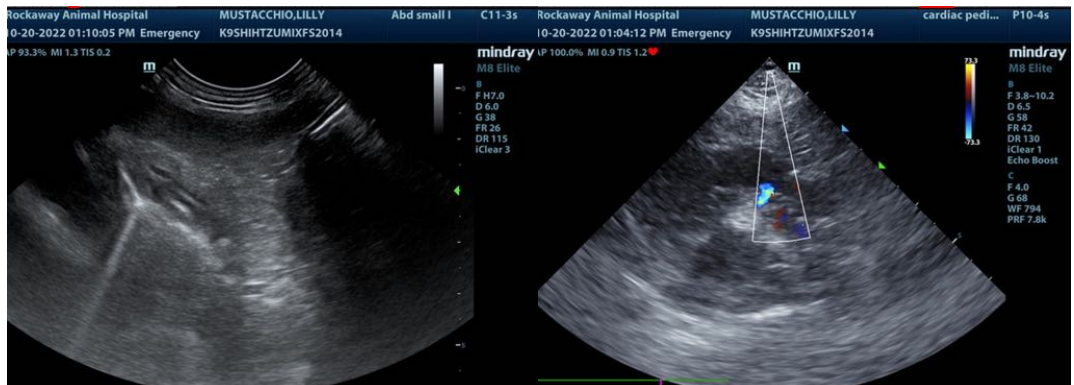
Age related abdominal changes otherwise.

Minor tricuspid insufficiency, compensated.

Minor cor pulmonale cardiac presentation.

INTERPRETATION OF THE FINDINGS & FURTHER RECOMMENDATIONS

No cardiac therapy is recommended at this time.





PATIENT

Lilly Mustacchio

SPECIES

Canine

BREED

Shih Tzu mix

SEX

Spayed female

AGE

8 years

WEIGHT

9 lbs

INTERPRETED BY

Eric Lindquist, DMV
DABVP, Cert. IVUSS

IMAGING PERFORMED BY

Jenn

HOSPITAL NAME

Rockaway AH

REFERRING VET

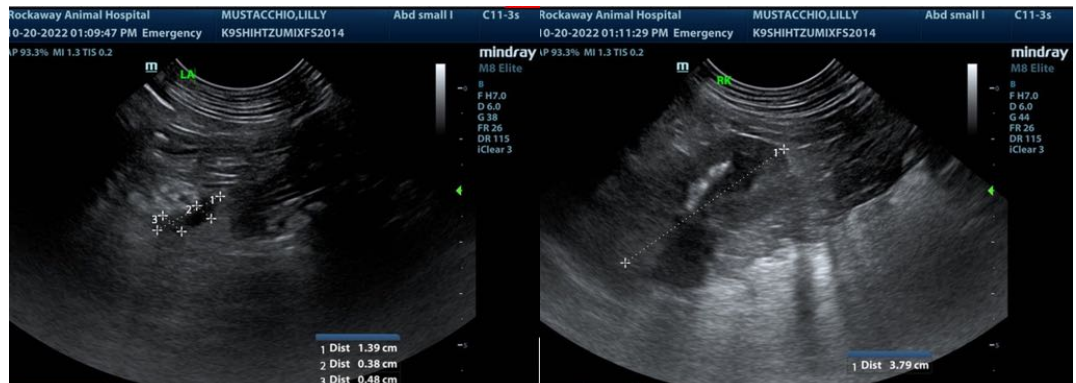
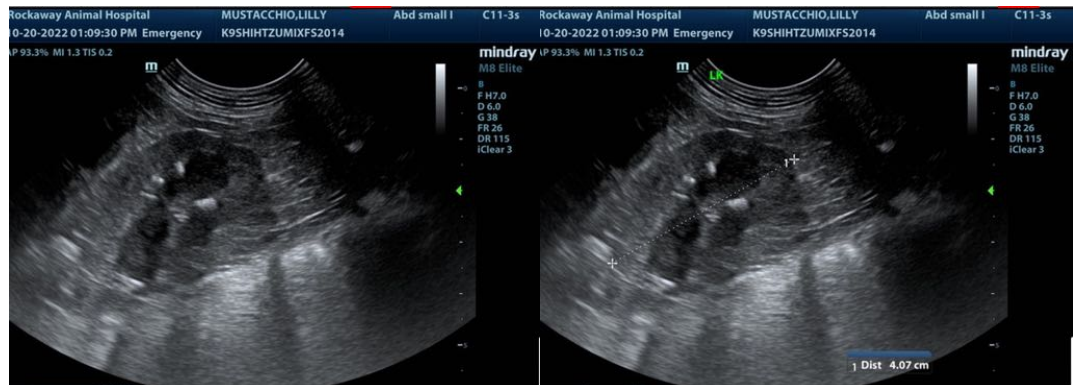
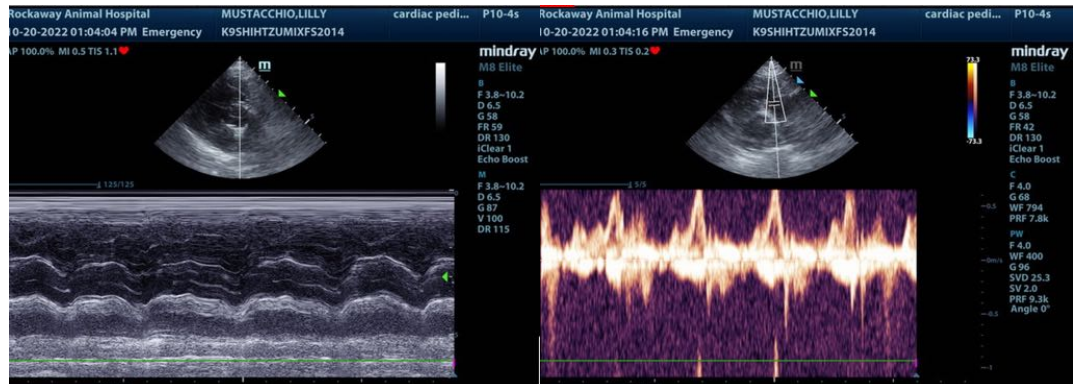
Dr. Maniar

INVOICE

40188

DATE

10/20/22



The information and recommendations provided are based on the images presented by the referring veterinarian/sonographer. No evaluation can be communicated regarding pathology that was not visible in the image/video clips provided.

Thank you for this referral. If the clinical or image interpretation does not parallel your findings or if I can be of any further assistance please contact me.

Eric Lindquist, DMV, DABVP, Cert. IVUSS, CEO of SonoPath.com
info@SonoPath.com