



PATIENT

Diesel Mathew

PRESENTING CLINICAL SIGNS

History: syncope . weakness for almost 24 hours radiographs revealed enlarged spleen and globoid heart

SPECIES

Canine

ULTRASONOGRAPHIC EXAMINATION OF THE ABDOMEN

Urinary System

BREED

Labrador

The **urinary bladder**, trigone, and pelvic urethra presented normal thicknesses and normal tone. The ureters were not visible which is normal. No uroliths or sediment were visualized and anechoic urine was present. No evidence of inflammatory or neoplastic changes was noted. Ureteral papillae were normal.

SEX

Netuered male

The **kidneys** revealed normal size and structure, corticomedullary definition and ratio for this age. The cortices presented largely uniform texture with normal echogenic relationship to liver and spleen. Medullary structure differed distinctly from the cortex and no evidence of pelvic dilation was present. The capsules were acceptably uniform without significant irregularities. The left kidney measured 5.19 cm. The right kidney measured 6.0 cm.

AGE

11 years

WEIGHT

38 lbs

Adrenal Glands

The **adrenal glands** were not visualized.

INTERPRETED BY

Eric Lindquist, DMV
DABVP, Cert. IVUSS

Spleen

The **spleen** presented a smooth homogeneous parenchyma hyperechoic to liver and renal cortical parenchyma. The capsule was smooth without noticeable expansion or deviation from within the spleen or adjacent pathology. The splenic vasculature demonstrated normal volume without signs of congestion or thrombosis. No sonographic evidence of acute or chronic inflammatory, neoplastic, or infarctual changes was noted.

IMAGING PERFORMED BY

Dr. Fresta

HOSPITAL NAME

The Veterinary Surgery

Liver

The visible **liver** was unremarkable. The gallbladder was not visualized.

REFERRING VET

Dr. Fresta

Gastrointestinal

Examination of the **gastrointestinal tract** revealed a stomach and intestine free of stasis, of normal wall thickness, acceptable curvilinear mural detail, and peristaltic activity. Small and large intestine demonstrated normal luminal chyme and stool consistency respectively. No obstructive or overt infiltrative disease was noted. No associated abnormal lymphatic activity was noted.

INVOICE

40216

DATE

10/20/22



PATIENT

Pancreas

Diesel Mathew

The base and limbs of the **pancreas** were observed to be largely isoechoic to surrounding omental fat. Pancreatic duct and capsular contour were acceptably normal and parenchyma respected normal curvilinear patterns. No overt evidence of active inflammatory or neoplastic disease was noted.

SPECIES

Canine

ULTRASONOGRAPHIC FINDINGS

BREED

Normal abdomen.

Labrador

INTERPRETATION OF THE FINDINGS & FURTHER RECOMMENDATIONS

SEX

There was no evidence of obvious pathology.

Netuered male

AGE

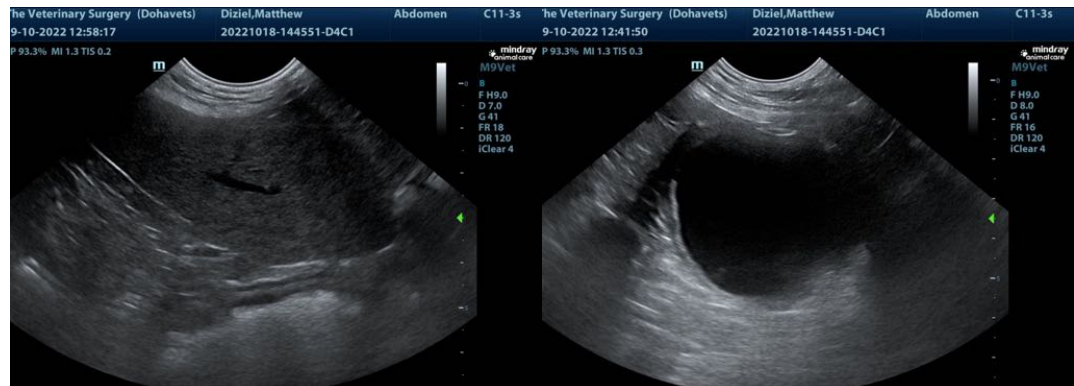
11 years

WEIGHT

38 lbs

INTERPRETED BY

Eric Lindquist, DMV
DABVP, Cert. IVUSS

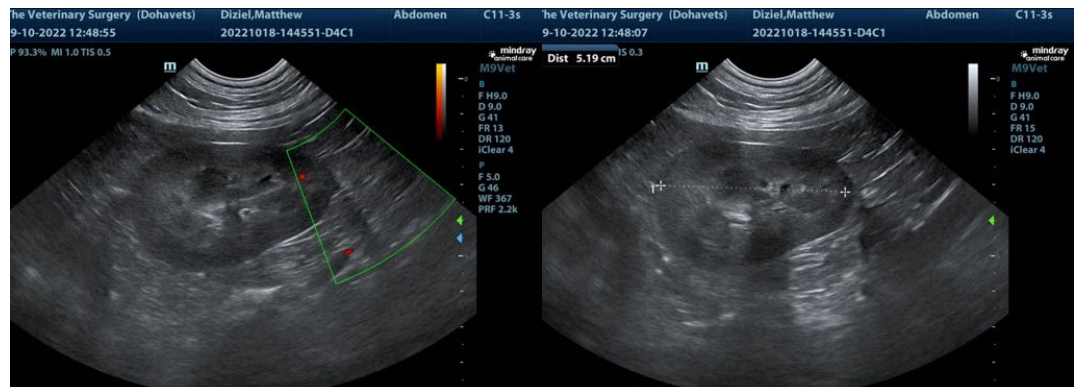


IMAGING PERFORMED BY

Dr. Fresta

HOSPITAL NAME

The Veterinary Surgery



REFERRING VET

Dr. Fresta

INVOICE

40216

DATE

10/20/22

The information and recommendations provided are based on the images presented by the referring veterinarian/sonographer. No evaluation can be communicated regarding pathology that was not visible in the image/video clips provided.

Thank you for this referral. If the clinical or image interpretation does not parallel your findings or if I can be of any further assistance please contact me.

Eric Lindquist, DMV, DABVP, Cert. IVUSS, CEO of SonoPath.com



PATIENT

info@SonoPath.com

Diesel Mathew

SPECIES

Canine

BREED

Labrador

SEX

Netuered male

AGE

11 years

WEIGHT

38 lbs

INTERPRETED BY

Eric Lindquist, DMV
DABVP, Cert. IVUSS

**IMAGING
PERFORMED BY**

Dr. Fresta

HOSPITAL NAME

The Veterinary Surgery

REFERRING VET

Dr. Fresta

INVOICE

40216

DATE

10/20/22