



PATIENT

Tasha McDonald

PRESENTING CLINICAL SIGNS

History: Chronic wt loss
Hyperthyroid but weight loss continues while being tx

SPECIES

Feline

ULTRASONOGRAPHIC EXAMINATION OF THE ABDOMEN

Urinary System

The **urinary bladder**, trigone, and pelvic urethra presented normal thicknesses and normal tone. The ureters were not visible which is normal. No uroliths or sediment were visualized and anechoic urine was present. No evidence of inflammatory or neoplastic changes was noted. Ureteral papillae were normal.

BREED

Domestic Shorthair

SEX

Spayed Female

AGE

13 years

The **kidneys** revealed largely normal size and structure, corticomedullary definition and ratio (cortex 1/3 of medulla) were essentially maintained with some age-related loss of curvilinear patterns regarding the capsule and C/M junction. The cortices presented largely uniform texture with some increased echogenicity expected for this age patient. Medullary structure differed distinctly from that of the cortex and no evidence of pelvic dilation was present. The left kidney measured 3.15 cm. The right kidney measured 3.25 cm.

WEIGHT

5.5 lbs

Adrenal Glands

Both **adrenal glands** were visualized and recognized as having normal shape, size, position and echogenicity for this breed. The phrenic vasculature, glandular echogenicity and detail were unremarkable. Capsule, cortex, and medullary definition were normal for this age patient. The left adrenal gland measured 0.47 cm.

INTERPRETED BY

Eric Lindquist, DMV
DABVP, Cert. IVUSS

IMAGING PERFORMED BY

Dr. Rodriguez

Spleen

The **spleen** presented a smooth homogeneous parenchyma hyperechoic to liver and renal cortical parenchyma. The capsule was smooth without noticeable expansion or deviation from within the spleen or adjacent pathology. The splenic vasculature demonstrated normal volume without signs of congestion or thrombosis. No sonographic evidence of acute or chronic inflammatory, neoplastic, or infarctual changes was noted.

HOSPITAL NAME

Foxfield VS

REFERRING VET

Dr. Rodriguez

Liver

The **liver** images from right and left intercostal as well as subcostal views revealed subjectively normal liver size, contour, and structure. Increased portal markings were noted. This is suggestive for history of inflammatory disease. Some age-related parenchymal remodeling was noted but likely not clinically significant at this time. Vascular and biliary tracts were of normal volume and no evidence of congestion was noted. The gallbladder presented some dependent debris with essentially normal contour. The cystic and common bile ducts were normal. No overt evidence of active inflammatory, infiltrative or regenerative pathology was noted but should be paired with current or past LE elevations regarding any clinical significance to this presentation. The hepatic lymph nodes were unremarkable.

INVOICE

92529

DATE

10/20/21



PATIENT

Gastrointestinal

Tasha McDonald

The **gastrointestinal tract** revealed minor variable thickening and echogenic submucosal changes most consistent with low grade end result of chronic GI disease such as IBD and may be related to malassimilation of nutrients if any weight loss is present. No obvious neoplastic patterns were noted and luminal content as unremarkable.

SPECIES

Feline

BREED

Domestic Shorthair

Pancreas

The base and limbs of the **pancreas** were observed to be largely isoechoic to surrounding omental fat. Pancreatic duct and capsular contour were acceptably normal and parenchyma respected normal curvilinear patterns. No overt evidence of active inflammatory or neoplastic disease was noted.

SEX

Spayed Female

Free Abdomen

Slight free fluid was noted. Reactive mesentery was noted in the mesenteric root.

AGE

13 years

ULTRASONOGRAPHIC FINDINGS

WEIGHT

5.5 lbs

Chronic triad presentation.

Slight free fluid and mesenteric lymphadenopathy.

INTERPRETED BY

Eric Lindquist, DMV
DABVP, Cert. IVUSS

INTERPRETATION OF THE FINDINGS & FURTHER RECOMMENDATIONS

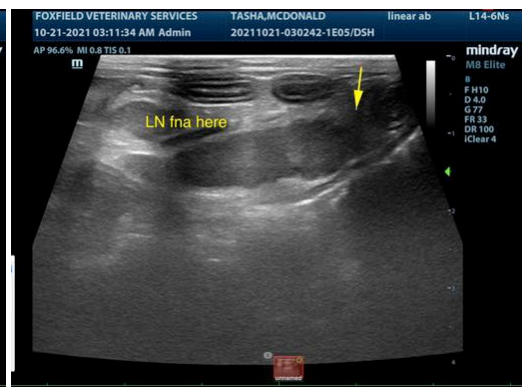
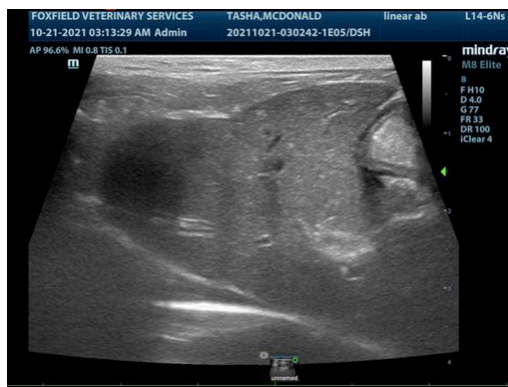There is a potential for emerging round cell neoplasia. Ultrasound-guided FNA of the mesenteric lymph node is recommended with cytology and culture in case underlying emerging round cell neoplasia is an issue.

IMAGING PERFORMED BY

Dr. Rodriguez

HOSPITAL NAME

Foxfield VS



REFERRING VET

Dr. Rodriguez

INVOICE

92529

DATE

10/20/21



PATIENT

Tasha McDonald

SPECIES

Feline

BREED

Domestic Shorthair

SEX

Spayed Female

AGE

13 years

WEIGHT

5.5 lbs

INTERPRETED BY

Eric Lindquist, DMV
DABVP, Cert. IVUSS

IMAGING PERFORMED BY

Dr. Rodriguez

HOSPITAL NAME

Foxfield VS

REFERRING VET

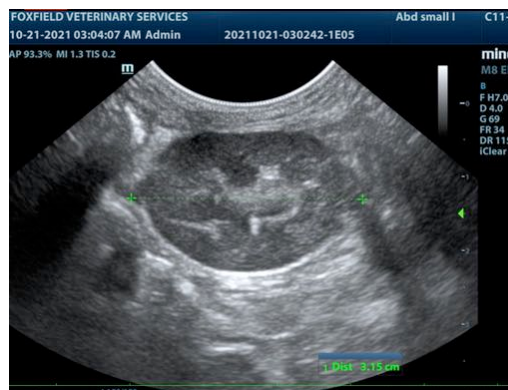
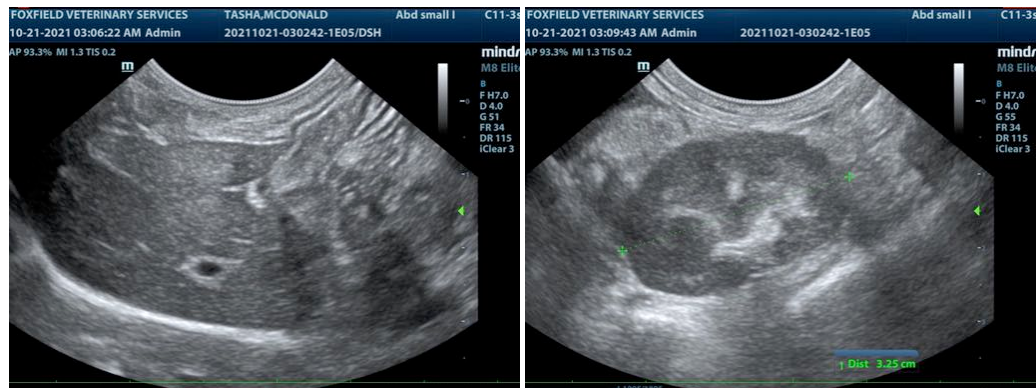
Dr. Rodriguez

INVOICE

92529

DATE

10/20/21



The information and recommendations provided are based on the images presented by the referring veterinarian. No evaluation can be communicated regarding pathology that was not visible in the image/video clips provided.

Thank you for this referral. If the clinical or image interpretation does not parallel your findings or if I can be of any further assistance please contact me.

Eric Lindquist, DMV, DABVP, Cert. IVUSS, CEO of SonoPath.com
info@SonoPath.com