



## PATIENT

Della Lindborg

## SPECIES

Feline

## BREED

DSH

## SEX

Spayed Female

## AGE

17 Weeks

## WEIGHT

2.8 Pounds

## INTERPRETED BY

Eric Lindquist, DMV  
DABVP, Cert. IVUSS

## IMAGING PERFORMED BY

Meg Schneck

## HOSPITAL NAME

Willamette VH

## REFERRING VET

Meg Schneck

## INVOICE

17541

## DATE

10/2/22

## PRESENTING CLINICAL SIGNS

History: Presented 10/1 as transfer from Santa Clara for suspect AKI vs severe dehydration. There is a lily in both houses (peace lily). Client takes ibuprofen periodically and some times a single tablet will drop. P not eating worsening over the week, lots of potential stressors. O also noticed discharge from eyes. Lethargic the past few days D+ one incident, no bm yesterday night. V+ one incident on Tuesday no coughing or sneezing.

Abnormal PE/Chem/CBC/UA Results: Santa Clara testing: BUN 115, creatinine 2.9, Na 138, Cl 95, CBC: Hct 23.5%, normal wbc 16.11, normal platlets 531. Oral ulceration, Marked dehydration. X-rays : 2 view . Clear lungs. Normal cardiac silhouette. Abdomen: mild renomegaly v. normal for age. 10-1 8p EPOC = Crea 3.36, BUN >120, lactate 4.28, moderate to severe metabolic acidosis with resp compensation pH 7.071, Bicarb 7.4, iCa 0.65, Cl 101, K 3.5, Na 128, UA (via cysto) = USG 1.012, protein 1+, WBCs 5/hpf, suspect rods and cocci, no casts bacterial confirmation kit = none seen Urine C&S Antech, pending 10-2 4:30a EPOC = Crea 3.29, BUN >120, iCa 0.47, Cl 105, Glu 145, K 2.8, Na 130, pH wnl 7.37, Bicarb 12.5 5:45p EPOC = CREA 2.28, BUN 104, Ca 0.66, Cl 108, Na 133, PCO2 28.8, TCO2 13.2, pH wnl 7.26

## LIMITED ULTRASONOGRAPHIC EXAMINATION

The **urinary bladder**, trigone, and pelvic urethra presented normal thicknesses and normal tone. The ureters were not visible which is normal. No uroliths or sediment were visualized, and anechoic urine was present. No evidence of inflammatory or neoplastic changes were noted. Ureteral papillae were normal.

The **kidneys** revealed normal size and structure, corticomedullary definition and ratio for this age. The cortices presented largely uniform texture with normal echogenic relationship to liver and spleen. Medullary structure differed distinctly from the cortex and no evidence of pelvic dilation was present. The capsules were acceptably uniform without significant irregularities. The left kidney measured 3.53 cm. The right kidney measured 3.65 cm.

## ULTRASONOGRAPHIC FINDINGS

- Structurally unremarkable kidneys, which given the clinical history, would support acute renal insult (infectious or toxic origin).

## INTERPRETATION OF THE FINDINGS & FURTHER RECOMMENDATIONS

72-hour IV fluid protocol and reassessment of the clinical status is indicated.

For an additional charge, internal medicine consult can be utilized through SonoPath.com. You can select the internal medicine drop down at <http://spa.sonopath.com/>.

One of the world's top internists & SonoPath associate Dr. Remo Lobetti BVSc, MMedVet, PhD, DECVIM can evaluate your case through SonoPath. <https://sonopath.com/resources/sonopath-services/internal-medicine-teleconsultation-services>



**PATIENT**

Della Lindborg

**SPECIES**

Feline

**BREED**

DSH

**SEX**

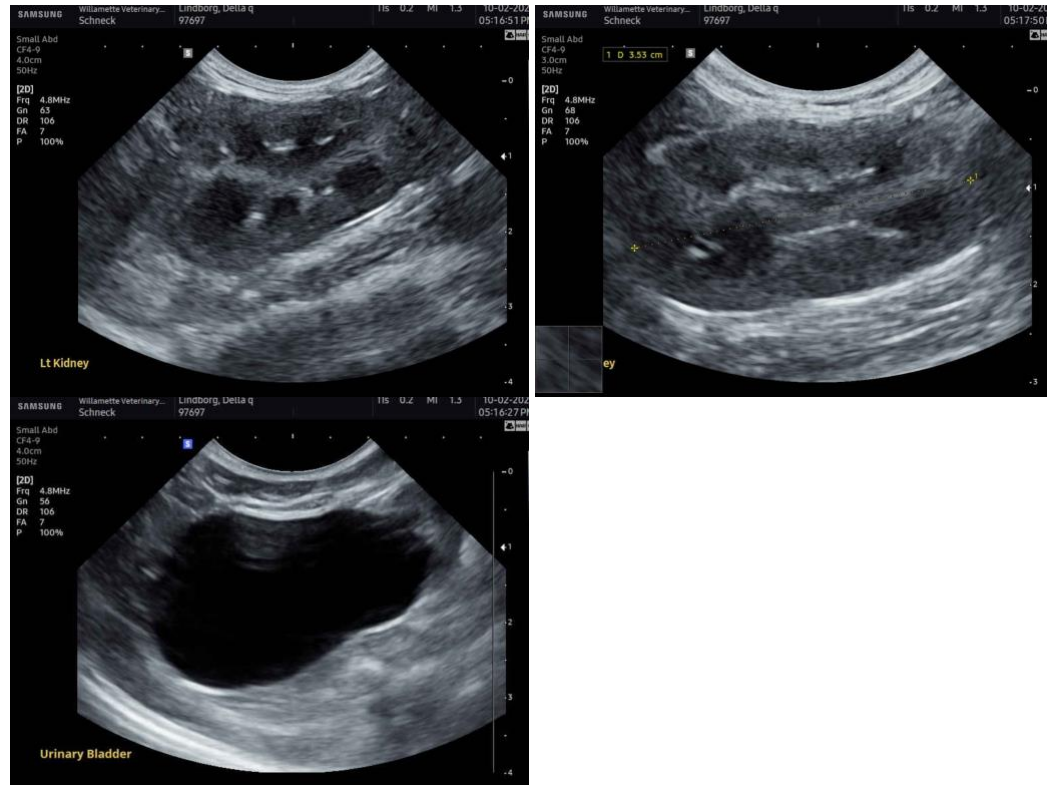
Spayed Female

**AGE**

17 Weeks

**WEIGHT**

2.8 Pounds



**INTERPRETED BY**

Eric Lindquist, DMV  
DABVP, Cert. IVUSS

**IMAGING PERFORMED BY**

Meg Schneck

**HOSPITAL NAME**

Willamette VH

**REFERRING VET**

Meg Schneck

**INVOICE**

17541

**DATE**

10/2/22

The information and recommendations provided are based on the images presented by the referring veterinarian. No evaluation can be communicated regarding pathology that was not visible in the image/video clips provided.

Thank you for this referral. If the clinical or image interpretation does not parallel your findings or if I can be of any further assistance please contact me.

**Eric Lindquist**, DMV, DABVP, Cert. IVUSS, CEO of SonoPath.com  
info@SonoPath.com

**Acute Renal Failure**

<http://www.sonopath.com/ARF>

**Description:** Acute renal failure (ARF)—also referred to as acute kidney injury—is defined as a rapid deterioration in renal function that results in the accumulation of metabolic waste in the body. It is characterized by an impaired regulation of water and solute balances, and may be due to prerenal, postrenal, and/or primary renal causes. Prerenal azotemia reflects a reduced glomerular filtration rate (GFR), which is a consequence of renal hypoperfusion; it is not the result of structural renal damage. Immediate restoration of renal blood flow will reverse the azotemia over a period of time; however, if the hypoperfusion is severe or prolonged, or if there is



**PATIENT**

Della Lindborg

**SPECIES**

Feline

**BREED**

DSH

**SEX**

Spayed Female

**AGE**

17 Weeks

**WEIGHT**

2.8 Pounds

**INTERPRETED BY**

Eric Lindquist, DMV  
DABVP, Cert. IVUSS

**IMAGING PERFORMED BY**

Meg Schneck

**HOSPITAL NAME**

Willamette VH

**REFERRING VET**

Meg Schneck

**INVOICE**

17541

**DATE**

10/2/22

prior renal dysfunction, acute primary renal failure due to ischemic acute tubular necrosis will be induced. Postrenal azotemia occurs when urine flow is obstructed or the excretory pathway is ruptured and there is subsequent urine resorption. Persistent urinary obstruction may cause irreversible renal damage. Early detection of postrenal azotemia will result in complete restoration of renal function. Acute tubular necrosis accounts for the majority of acute primary renal failure cases and is characterized by an abrupt and sustained reduction in GFR due to an ischemic or toxic renal insult. The conditions that incite ischemia are the same as those for prerenal azotemia; however, the duration of the ischemia is important. Nephrotoxins are a frequent cause of tubular necrosis. The high rates of blood flow and metabolic activity in the kidneys as well as their excretory function predispose dogs and cats to the toxic effects of drugs as well as endogenous or exogenous toxins.

**Clinical Signs:** The clinical course in acute tubular necrosis can be divided into three phases: an initiating phase, a maintenance phase, and a recovery phase. The initiating phase, which is marked by the onset of renal injury, is the period in which there is the greatest potential for preventing or reversing tubular damage and the progression to overt renal failure because it is during this period that renal cell damage develops. The challenge, however, is that the initiating phase may only become evident in retrospect as it generally lacks characteristic signs. The maintenance phase is characterized by the onset of oliguria (i.e., urine production is less than 1ml/kg/hour). The onset of this phase typically occurs during the first 24 hours, but may be delayed for up to 1 week. The duration of this phase is highly variable, but usually persists for up to 2 weeks. It is characterized by: fluid and electrolyte imbalances, including an alteration in hydration; hyponatremia; hyperkalemia; high anion gap metabolic acidosis; hypocalcemia; hyperphosphatemia; and azotemia. Clinical signs include gastrointestinal, hematological, and neurological manifestations of renal failure. The recovery phase commences when the GFR increases, which consequently slows down and reverses the azotemia. There is a progressive increase in urine volume, and although the tubular function begins to improve, it nevertheless remains impaired. Diuresis persists because of the diminished ability of the tubules to reabsorb sodium and respond to vasopressin. Clinical manifestations observed in the maintenance phase persist into the recovery phase. In some patients, infections and/or gastrointestinal bleeding may occur. Sites of infection include the respiratory tract, operative sites, and the urinary tract. Septicemia may also occur and is sometimes the result of intravenous and urinary indwelling catheters.

**Diagnostics:** Extraordinary disorders that produce prerenal azotemia are associated with concentrated, hypersthenuric urine, which contains a relatively low concentration of sodium and high concentration of creatinine. ARF is typically characterized by enlarged or swollen kidneys, elevated hematocrit, and azotemia. Urine is isosthenuric or minimally concentrated, and contains high concentrations of creatinine. Proteinuria or glycosuria may also accompany this condition. The sediment will show casts and RTE cells. Complete anuria is usually associated with postrenal azotemia. Features that are typical for acute tubular necrosis include: anuria in the absence of a urinary tract obstruction or rupture; severe proteinuria; significant hematuria with red cell casts; and prolonged oliguria. In these cases, a diagnostic renal biopsy is indicated.

**Treatment:** Most patients with ARF are volume depleted. Fluid therapy is indicated to correct dehydration, which will restore adequate renal perfusion and may prevent further renal damage. If the etiology was prerenal in origin, then urine volume will increase. In the maintenance phase, fluid therapy should be directed toward maintaining fluid balance and preventing both overhydration and dehydration. In cases of renal disease it is



**PATIENT**

Della Lindborg

**SPECIES**

Feline

**BREED**

DSH

**SEX**

Spayed Female

**AGE**

17 Weeks

**WEIGHT**

2.8 Pounds

**INTERPRETED BY**

Eric Lindquist, DMV  
DABVP, Cert. IVUSS

**IMAGING PERFORMED BY**

Meg Schneck

**HOSPITAL NAME**

Willamette VH

**REFERRING VET**

Meg Schneck

**INVOICE**

17541

**DATE**

10/2/22

important that only maintenance needs and ongoing losses are attended to as overhydration can develop if there is reduced renal function. Insensible losses are calculated at 20 ml/kg/day. Aggressive fluid therapy during the recovery phase may perpetuate polyuria. As the urine volume stabilizes, the volume of fluid administered should be reduced correspondingly. Because dehydration may occur during this phase, one should monitor body weight and clinically assess the hydration status as fluid therapy is being reduced. Oliguric patients who are unresponsive to fluid volume replacement can be treated with mannitol, furosemide, and/or dopamine in an attempt to increase GFR and urine volume. Hyperkalemia is commonly associated with the maintenance phase of ARF. Concentrations greater than 6 mmol/l may require treatment with sodium bicarbonate, dextrose, insulin and/or calcium gluconate. Hemodialysis should be considered in patients with severe, persistent uremia, acidosis, or hyperkalemia. It may also be used to treat overhydration and hasten the elimination of nephrotoxins.

**Conclusion:** Because ARF is frequently iatrogenic and associated with nephrotoxic drugs or inadequate fluid therapy, prevention is the best therapy.

**References:**

Acierno MJ, Maeckelbergh V. Continuous renal replacement therapy. *Compend Contin Educ Vet* 2008;30:264-72.

Grauer GF. Early detection of renal damage and disease in dogs and cats. *Vet Clin North Am Small Anim Pract* 2005;35:581-96.

Labato MA. Strategies for management of acute renal failure. *Vet Clin North Am Small Anim Pract* 2001;31:1265-87.

Ross L. Acute kidney injury in dogs and cats. *Vet Clin North Am Small Anim Pract* 2011;41:1-14.