



PATIENT

Wee Lass Orr

SPECIES

Canine

BREED

Poodle

SEX

Spayed Female

AGE

14 Years

WEIGHT

18.2 Pounds

INTERPRETED BY

Eric Lindquist, DMV
DABVP, Cert. IVUSS

IMAGING PERFORMED BY

Dr. Mychajlonka

HOSPITAL NAME

Craig Road AH

REFERRING VET

Dr. Mychajlonka

INVOICE

26029

DATE

10/2/21

PRESENTING CLINICAL SIGNS

Hypercalcemia. Abnormal thyroid.
Abnormal PE/Chem/CBC/UA Results: Lab work 9/2/2021 Ionized Calcium -1.54 HIGH (1.25-1.45 mmol/L) CALCIUM -11.8 HIGH (8.9-11.4 mg/dL) BUN/CREAT RATIO-30 HIGH (4-27) TRIGLYCERIDE-487 HIGH (29-291 mg/dL) HGB-22.3 HIGH (12.1-20.3 g/dL) HCT-69 HIGH (36-60 %) MCV-83 HIGH (58-79 fL) Platelet Count- 411 HIGH

ULTRASONOGRAPHIC EXAMINATION OF THE ABDOMEN

Urinary System

The **urinary bladder**, trigone, and pelvic urethra presented normal thicknesses and normal tone. The ureters were not visible which is normal. No uroliths or sediment were visualized and anechoic urine was present. No evidence of inflammatory or neoplastic changes were noted. Ureteral papillae were normal. Urethral calculi noted, embedded within the first 1.5-2.0 cm.

The **kidneys** revealed largely normal size and structure, corticomedullary definition and ratio (cortex 1/3 of medulla) were essentially maintained with some age-related loss of curvilinear patterns regarding the capsule and C/M junction. The cortices presented largely uniform texture with some increased echogenicity expected for his age patient. Medullary structure differed distinctly from that of the cortex and no evidence of pelvic dilation was present. Mineralization noted in both kidneys. The left kidney measured 5.0 cm. The right kidney measured 4.5 cm.

Adrenal Glands

The **left adrenal gland** was uniform at 0.6 cm. The **right adrenal gland** was normal and measured 0.8 cm at the cranial pole and 0.5 cm at the caudal pole.

Spleen

The **spleen** presented a smooth homogeneous parenchyma hyperechoic to liver and renal cortical parenchyma. The capsule was smooth without noticeable expansion or deviation from within the spleen or adjacent pathology. The splenic vasculature demonstrated normal volume without signs of congestion or thrombosis. No sonographic evidence of acute or chronic inflammatory, neoplastic, or infarctual changes were noted.

Liver

The **liver** was uniformly swollen with minor, excessive gallbladder debris and over distension with dependent and suspended bile without evidence of overt mucocele formation. However, excessive sludge was present. The liver presented coarse architecture with mildly increased portal markings and subtle, mixed echogenic changes. This is consistent with vacuolar hepatopathy and some level of remodeling and history of inflammatory component. There was no overt suspicion of neoplasia.

Gastrointestinal

Examination of the **gastrointestinal tract** revealed a stomach and intestine free of stasis, of normal wall thickness, acceptable curvilinear mural detail, and peristaltic activity. Small and large intestine demonstrated normal luminal chyme and stool consistency respectively. No obstructive or overt infiltrative disease was noted. No associated abnormal lymphatic activity was noted.



PATIENT

Pancreas

Wee Lass Orr

The base and limbs of the **pancreas** were observed to be largely isoechoic to surrounding omental fat. Pancreatic duct and capsular contour were acceptably normal and parenchyma respected normal curvilinear patterns. No overt evidence of active inflammatory or neoplastic disease was noted.

SPECIES

Thyroid

Canine

Left parathyroid nodule noted measuring 0.66 cm, expansive, disruptive architecture. The nodule appeared to be at the mid cranial body of the thyroid. The right thyroid lobe revealed normal parenchyma and normal parathyroid measuring 0.2 cm.

BREED

ULTRASONOGRAPHIC FINDINGS

Poodle

SEX

- Urethral calculi
- Age related renal changes with mineralization
- Excessive gallbladder debris
- Left parathyroid nodule

Spayed Female

AGE

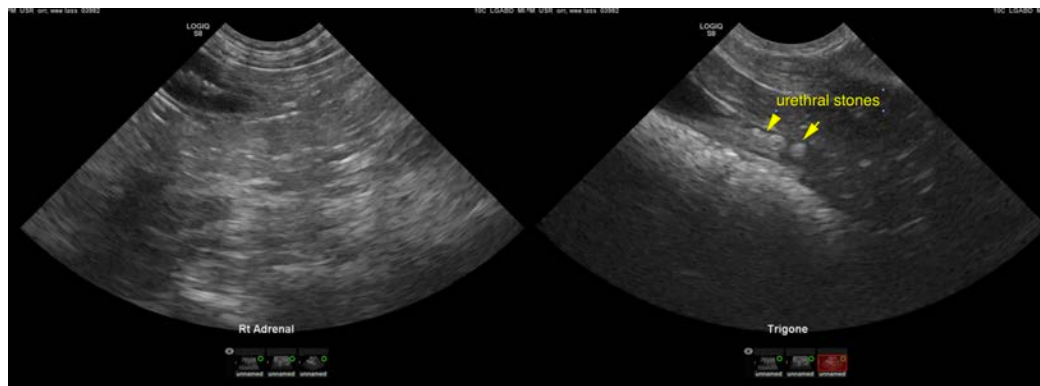
INTERPRETATION OF THE FINDINGS & FURTHER RECOMMENDATIONS

14 Years

No evidence of significant disease in the abdomen other than urethral calculi. These may pass. However, assessment for urethral obstruction is recommended. Left parathyroidectomy recommended.

WEIGHT

18.2 Pounds



INTERPRETED BY

Eric Lindquist, DMV
DABVP, Cert. IVUSS

IMAGING PERFORMED BY

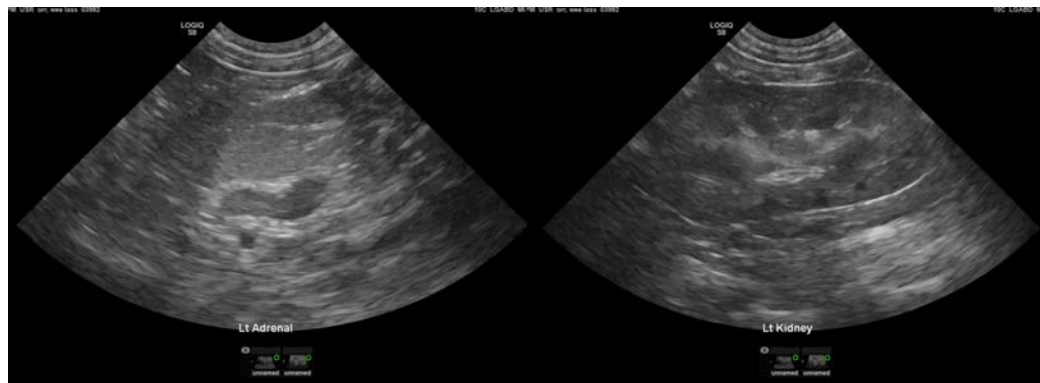
Dr. Mychajlonka

HOSPITAL NAME

Craig Road AH

REFERRING VET

Dr. Mychajlonka



INVOICE

26029

DATE

10/2/21



PATIENT

Wee Lass Orr

SPECIES

Canine

BREED

Poodle

SEX

Spayed Female

AGE

14 Years

WEIGHT

18.2 Pounds

INTERPRETED BY

Eric Lindquist, DMV
DABVP, Cert. IVUSS

IMAGING PERFORMED BY

Dr. Mychajlonka

HOSPITAL NAME

Craig Road AH

REFERRING VET

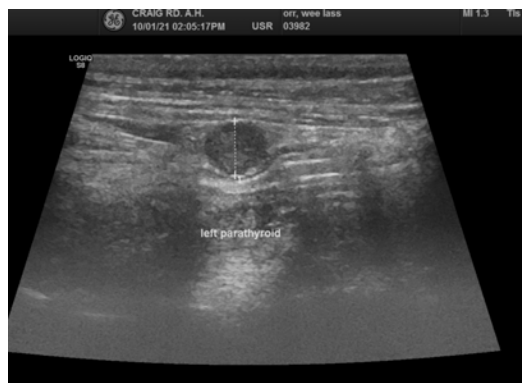
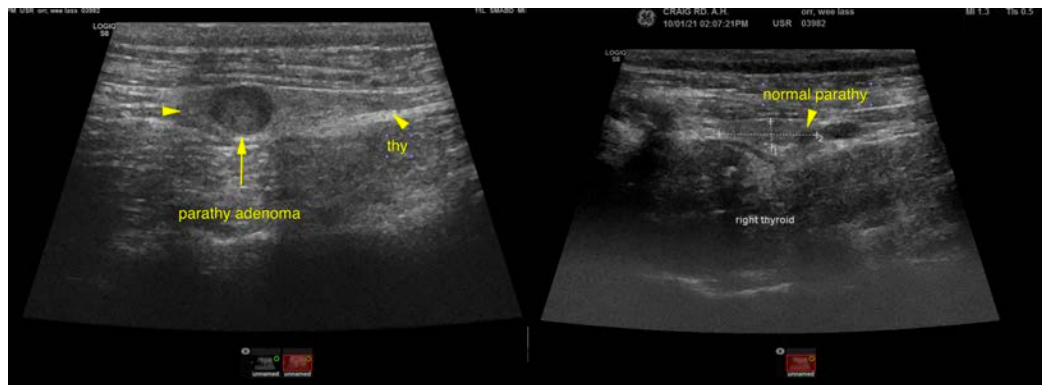
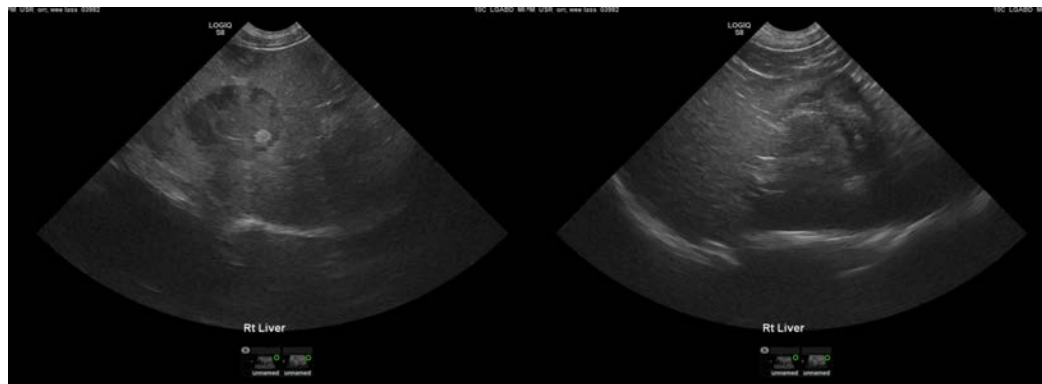
Dr. Mychajlonka

INVOICE

26029

DATE

10/2/21



The information and recommendations provided are based on the images presented by the referring veterinarian. No evaluation can be communicated regarding pathology that was not visible in the image/video clips provided.

Thank you for this referral. If the clinical or image interpretation does not parallel your findings or if I can be of any further assistance please contact me.

Eric Lindquist, DMV, DABVP, Cert. IVUSS, CEO of SonoPath.com
info@SonoPath.com



PATIENT

Wee Lass Orr

SPECIES

Canine

BREED

Poodle

SEX

Spayed Female

AGE

14 Years

WEIGHT

18.2 Pounds

INTERPRETED BY

Eric Lindquist, DMV
DABVP, Cert. IVUSS

IMAGING PERFORMED BY

Dr. Mychajlonka

HOSPITAL NAME

Craig Road AH

REFERRING VET


Dr. Mychajlonka

INVOICE

26029

DATE

10/2/21



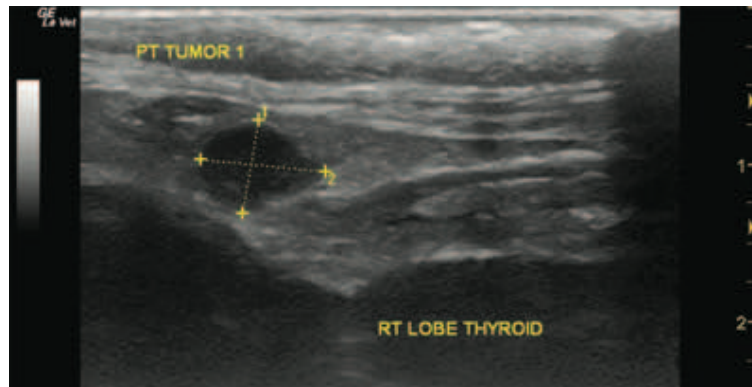
The following is an applicable excerpt from the *Curbside Guide to Diagnosis & Treatment of Sonographic Disease* offered by [SonoPath.com](http://sonopath.com) Lindquist, Frank, Lobetti, and Modler.

An essential quick guide for every general practitioner and sonographer.

<https://sonopath.com/products/curbside-guide-editing-due-release-12012015>

CANINE HYPERCALCEMIA

<http://www.sonopath.com/CanineHypercalcemia>



Long axis of the right thyroid lobe in a dog with a parathyroid adenoma. The right internal parathyroid gland (between calipers) shows severe uniform enlargement of more than 7mm.

Description: Hypercalcemia is defined as either a persistently elevated total calcium serum (> 12 mg/dl) or ionized calcium (> 1.45 mmol/l) concentration. Clinical signs are often absent with mild hypercalcemia (< 13 mg/dl). In fact, hypercalcemia is often only discovered when serum biochemistry is done for unrelated reasons. Clinical signs are usually mild when the serum calcium concentration is less than 14 mg/dl; however, signs become more readily apparent when the concentration exceeds 15 mg/dl. Life-threatening cardiac arrhythmias can develop when the serum calcium exceeds 18 mg/dl.

Common etiologies of hypercalcemia include humoral hypercalcemia of malignancy (HHM), hypoadrenocorticism, chronic kidney disease (CKD), hypervitaminosis D, and primary hyperparathyroidism. Less common etiologies include bone neoplasia, osteomyelitis, hypertrophic osteodystrophy, granulomatous disease, calcium supplementation, and oral phosphate binders.

Clinical Signs: Common clinical signs include polyuria, polydipsia, lethargy, inappetence, and weakness. With chronic hypercalcemia, calcium oxalate and calcium phosphate uroliths can form, resulting in clinical signs suggestive of lower urinary tract disease. Systemic signs of illness are suggestive of HHM.



PATIENT

Wee Lass Orr

SPECIES

Canine

BREED

Poodle

SEX

Spayed Female

AGE

14 Years

WEIGHT

18.2 Pounds

INTERPRETED BY

Eric Lindquist, DMV
DABVP, Cert. IVUSS

IMAGING PERFORMED BY

Dr. Mychajlonka

HOSPITAL NAME

Craig Road AH

REFERRING VET

Dr. Mychajlonka

INVOICE

26029

DATE

10/2/21

Diagnostics: One important etiology of hypercalcemia is laboratory error; therefore, hypercalcemia should always be confirmed before embarking on any further diagnostic evaluation. Results of a CBC, serum biochemistry panel, and urinalysis, in conjunction with a patient history and findings from a physical examination, can often provide enough information to arrive at a diagnosis. The appendicular skeleton, peripheral lymph nodes, abdominal cavity, and rectum should all be carefully palpated for masses, lymphadenopathy, hepatomegaly, splenomegaly, and/or pain in the long bones. The following diagnostic tests are helpful for identifying an underlying malignancy: thoracic and abdominal radiographs; abdominal ultrasound; cytological evaluation of aspirates of the liver, spleen, lymph nodes, and bone marrow; determination of serum ionized calcium, parathyroid hormone (PTH), and parathyroid hormone-related protein concentration (PTHrP); and ultrasound of the neck. Ascertaining the concentrations of serum ionized calcium, PTH, and PTHrP helps differentiate primary hyperparathyroidism from HHM. The finding of one or more enlarged parathyroid glands upon conducting an ultrasound of the neck supports a diagnosis of primary hyperparathyroidism.

Hypoadrenocorticism-induced hypercalcemia usually occurs in conjunction with hyponatremia, hyperkalemia, and prerenal azotemia. With HHM and primary hyperparathyroidism, serum phosphorus concentration is often in the low to low-normal reference range. If the serum phosphorus concentration is high but kidney function is normal, hypervitaminosis D or osteolysis should be suspected.

It can be difficult to determine whether kidney failure is primary or secondary to hypercalcemia when hyperphosphatemia and hypercalcemia coexist with azotemia. Serum ionized calcium concentrations are typically normal or decreased in cases of renal failure and increased in cases of hypercalcemia caused by other disorders.

Sternal and hilar lymphadenopathy is common with lymphoma-induced hypercalcemia and can be readily identified on thoracic radiographs. In cases of multiple myeloma, discrete lytic lesions in the vertebrae or long bones, hyperproteinemia, proteinuria, and plasma cell infiltration in the bone marrow may be present. Cytological evaluation of the peripheral lymph nodes, bone marrow, and spleen can be helpful in identifying lymphoma.

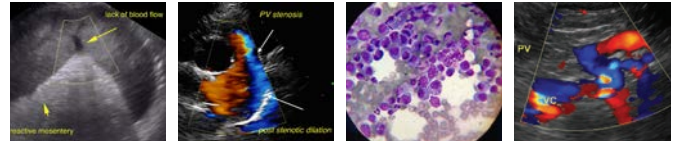
Increased serum ionized calcium concentrations, detectable serum PTHrP concentrations, and non-detectable serum PTH concentrations are all diagnostic for HHM. Lymphoma is the most common etiology of HHM, but other tumors, such as apocrine gland adenocarcinoma and various carcinomas (e.g. mammary gland, squamous cell, bronchogenic), can all give rise to hypercalcemia. Increased serum ionized calcium, normal to increased serum PTH, and non-detectable PTHrP concentrations are diagnostic of primary hyperparathyroidism.

Differentials for Hypercalcemia: "HARD IONS"

Hyperparathyroid

Addison's

Renal



PATIENT

D-toxicity

Wee Lass Orr

Idiopathic

SPECIES

Osteolytic

Canine

Neoplastic

Spurious

BREED

Poodle

PTH tumor: Elevated total and ionized Ca, low PTHrP, and normal/high PTH. Keeshonds, German Shepherds, and Golden Retrievers are all predisposed.

SEX

Addison's disease: Elevated total and normal ionized Ca, elevated BUN, hypoalbuminemia and hyperkalemia.

Spayed Female

Renal failure: Elevated to normal total Ca, low ionized Ca, low PTHrP, elevated PTH, azotemia, and low urine specific gravity.

AGE

14 Years

Vitamin D toxicity: Elevated total and ionized Ca, low PTHrP, and normal/low PTH.

Hypercalcemia of malignancy (HHM): Elevated total and ionized Ca, high PTHrP, and low PTH.

WEIGHT

18.2 Pounds

Granulomatous disease: Elevated total and ionized Ca, low PTHrP, and low PTH.

Renal failure: Elevated to normal total Ca, low ionized Ca, low PTHrP, elevated PTH, azotemia, and low urine specific gravity.

INTERPRETED BY

Eric Lindquist, DMV
DABVP, Cert. IVUSS

Treatment: Therapies for hypercalcemia are aimed at correcting the underlying etiology; however, because prolonged hypercalcemia can result in kidney damage, the use of fluid therapy, furosemide, and possibly prednisone is indicated in all cases to reduce serum calcium levels. Suggested dosages include saline (0.9% 120-180 ml/kg day IV), furosemide (1-4 mg/kg PO TID), and prednisone (0.25 mg/kg PO Q24hr).

IMAGING PERFORMED BY

Dr. Mychajlonka

HOSPITAL NAME

Craig Road AH

REFERRING VET

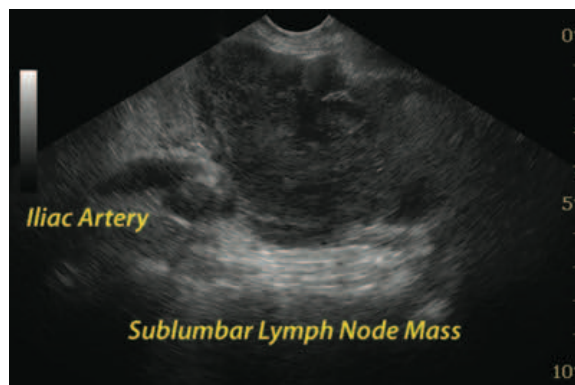
Dr. Mychajlonka

INVOICE

26029

DATE

10/2/21



Long axis of the left hypogastric lymph node in a hypercalcemic dog with lymphoma and hypercalcemia of malignancy. The lymph node is severely enlarged and rounded with a short-to-long-axis ratio > 0.5 indicating malignant infiltration. The regular echoarchitecture is lost, the hilus is not recognized, lymph node parenchyma is hypoechoic and heterogenous. Also note the mass effect on the external iliac artery. In light of hypercalcemia, lymphadenopathy in this region could also be owing to anal gland adenocarcinoma which can also be imaged sonographically.



PATIENT

Wee Lass Orr

SPECIES

Canine

BREED

Poodle

SEX

Spayed Female

AGE

14 Years

WEIGHT

18.2 Pounds

INTERPRETED BY

Eric Lindquist, DMV
DABVP, Cert. IVUSS

**IMAGING
PERFORMED BY**

Dr. Mychajlonka

HOSPITAL NAME

Craig Road AH

REFERRING VET

Dr. Mychajlonka

INVOICE

26029

DATE

10/2/21

References:

Chew DJ, Schenck PA, Jaeger JQ. Clinical disorders of hypercalcemia and hypocalcemia in dogs and cats. Proceedings from the American College of Veterinary Internal Medicine, Charlotte, NC, June 4-7, 2003.

Feldman EC. Disorders of the parathyroid glands. In: Ettinger SJ, Feldman EC, ed. *Textbook of Veterinary Internal Medicine, 7th ed.* St. Louis, MO: Saunders Elsevier; 2010:1722-50.

Peterson ME. Hypercalcemia in dogs & cats: differential diagnosis & treatment. Proceedings from the Western Veterinary Conference, Las Vegas, NV, February 19-23, 2012.