



**PATIENT**

Miles Moreno

**SPECIES**

Feline

**BREED**

DSH

**SEX**

Nuetered Male

**AGE**

14 Years

**WEIGHT**

7 pounds

**INTERPRETED BY**

Eric Lindquist, DMV  
DABVP, Cert. IVUSS

**IMAGING  
PERFORMED BY**

Kristin Peterson

**HOSPITAL NAME**

Wilvet Salem

**REFERRING VET**

Sequoia VC

**INVOICE**

13463

**DATE**

10/2/21

**PRESENTING CLINICAL SIGNS**

History: lethargic/inappetant x 3-4 days, radiographs completed at rDVM suggested possible mass in abd

Abnormal PE/Chem/CBC/UA Results:

**ULTRASONOGRAPHIC EXAMINATION OF THE ABDOMEN**

**Urinary System**

The **urinary bladder**, trigone, and pelvic urethra presented normal thicknesses and normal tone. The ureters were not visible which is normal. No uroliths or sediment were visualized and anechoic urine was present. No evidence of inflammatory or neoplastic changes were noted. Ureteral papillae were normal.

The **kidneys** revealed largely normal size and structure, corticomedullary definition and ratio (cortex 1/3 of medulla) were essentially maintained with some minor age-related loss of curvilinear patterns regarding the capsule and C/M junction. The cortices presented largely uniform texture with some increased echogenicity expected for his age patient. Medullary structure differed distinctly from that of the cortex and no evidence of pelvic dilation was present. The left kidney measured 3.0 cm. The right kidney measured 3.0 cm.

**Adrenal Glands**

The regions of the **adrenal glands** revealed no evident pathology.

**Spleen**

The **spleen** presented a smooth homogeneous parenchyma hyperechoic to liver and renal cortical parenchyma. The capsule was smooth without noticeable expansion or deviation from within the spleen or adjacent pathology. The splenic vasculature demonstrated normal volume without signs of congestion or thrombosis. No sonographic evidence of acute or chronic inflammatory, neoplastic, or infarctual changes were noted.

**Liver**

The visible **liver** was unremarkable. The gallbladder was not visualized.

**Gastrointestinal**

Examination of the **gastrointestinal tract** revealed a stomach and intestine free of stasis, of normal wall thickness, acceptable curvilinear mural detail, and peristaltic activity. Small and large intestine demonstrated normal luminal chyme and stool consistency respectively. No overt infiltrative disease was noted. No associated abnormal lymphatic activity was noted. No evidence of foreign body.

**Pancreas**

The base and limbs of the **pancreas** were observed to be largely isoechoic to surrounding omental fat. Pancreatic duct and capsular contour were acceptably normal and parenchyma respected normal curvilinear patterns. No overt evidence of active inflammatory or neoplastic disease was noted.

**ULTRASONOGRAPHIC FINDINGS**



**PATIENT**

- Unremarkable abdomen based on the image set provided
- Age-related renal changes

Miles Moreno

**INTERPRETATION OF THE FINDINGS & FURTHER RECOMMENDATIONS**

**SPECIES**

Supportive care should prove effective.

Feline

**BREED**

DSH

**SEX**

Nuetered Male

**AGE**

14 Years

**WEIGHT**

7 pounds

**INTERPRETED BY**

Eric Lindquist, DMV  
DABVP, Cert. IVUSS

**IMAGING PERFORMED BY**

Kristin Peterson

**HOSPITAL NAME**

Wilvet Salem

**REFERRING VET**

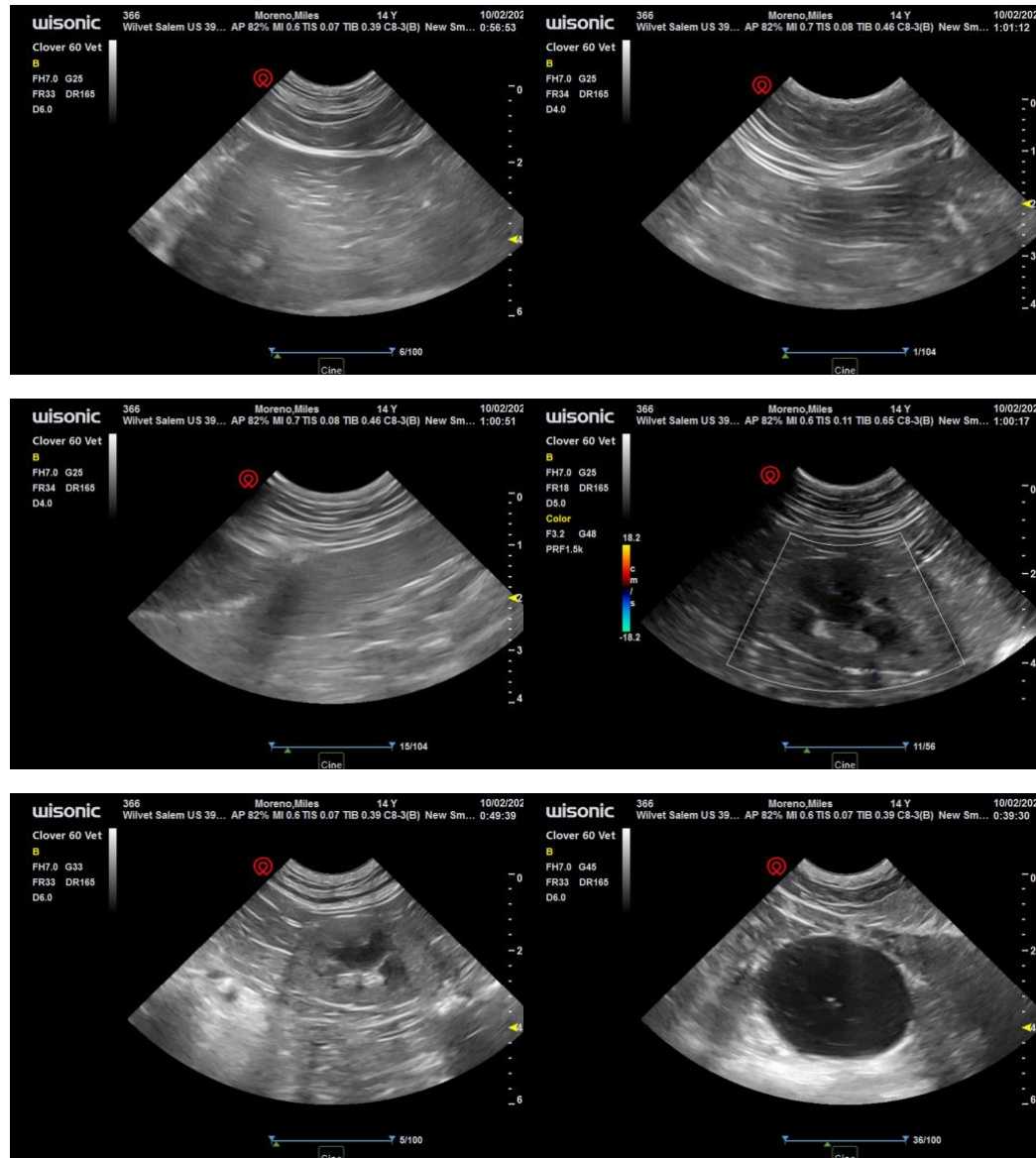
Sequoia VC

**INVOICE**

13463

**DATE**

10/2/21



The information and recommendations provided are based on the images presented by the referring veterinarian. No evaluation can be communicated regarding pathology that was not visible in the image/video clips provided.

Thank you for this referral. If the clinical or image interpretation does not parallel your findings or if I can be of any further assistance please contact me.

**Eric Lindquist**, DMV, DABVP, Cert. IVUSS, CEO of SonoPath.com



**PATIENT**

info@SonoPath.com

Miles Moreno

**SPECIES**

Feline

**BREED**

DSH

**SEX**

Nuetered Male

**AGE**

14 Years

**WEIGHT**

7 pounds

**INTERPRETED BY**

Eric Lindquist, DMV  
DABVP, Cert. IVUSS

**IMAGING  
PERFORMED BY**

Kristin Peterson

**HOSPITAL NAME**

Wilvet Salem

**REFERRING VET**

Sequoia VC

**INVOICE**

13463

**DATE**

10/2/21