



PATIENT

Cassie Krueger

SPECIES

Canine

BREED

Maltese

SEX

Spayed Female

AGE

2 Years

WEIGHT

6.9 Pounds

INTERPRETED BY

Eric Lindquist, DMV
DABVP, Cert. IVUSS

**IMAGING
PERFORMED BY**

Mayra Sanchez

HOSPITAL NAME

Sunset AH

REFERRING VET

Cristina Polit

INVOICE

13452

DATE

10/2/21

PRESENTING CLINICAL SIGNS

History: Two-day history of vomiting Owner unsure of FB ingestion

Abnormal PE/Chem/CBC/UA Results: CBC/Chem: NSF Fecal: Coccidiosis

ULTRASONOGRAPHIC EXAMINATION OF THE ABDOMEN

Urinary System

The **urinary bladder**, trigone, and pelvic urethra presented normal thicknesses and normal tone. The ureters were not visible which is normal. No uroliths or sediment were visualized and anechoic urine was present. No evidence of inflammatory or neoplastic changes were noted. Ureteral papillae were normal. The pelvic urethra was imaged 3.0 cm beyond the cystourethral junction. Iliac trifurcation was unremarkable.

The **kidneys** revealed normal size and structure, corticomedullary definition and ratio for this age. The cortices presented largely uniform texture with normal echogenic relationship to liver and spleen. Medullary structure differed distinctly from the cortex and no evidence of pelvic dilation was present. The capsules were acceptably uniform without significant irregularities. The left kidney measured 3.0 cm. The right kidney measured 3.0 cm.

Adrenal Glands

The regions of the **adrenal glands** were imaged and revealed no evident pathology.

Spleen

The **spleen** presented a smooth homogeneous parenchyma hyperechoic to liver and renal cortical parenchyma. The capsule was smooth without noticeable expansion or deviation from within the spleen or adjacent pathology. The splenic vasculature demonstrated normal volume without signs of congestion or thrombosis. No sonographic evidence of acute or chronic inflammatory, neoplastic, or infarctual changes were noted.

Liver

The **liver** images submitted revealed subjectively normal liver size, contour, and structure. Parenchymal echogenicity was naturally coarse and hypoechoic to the spleen. Vascular and biliary tracts were of normal volume with no evidence of congestion. The gallbladder presented acceptably thin walls with primarily anechoic content. The cystic and common bile ducts were normal. No pathological hepatic lymphadenopathy was evident. No overt structural evidence of inflammatory, infiltrative or regenerative pathology was evident.

Gastrointestinal

The **pylorus** was mildly thickened. Some minor loss of mural detail noted. No evidence of foreign body. The small intestine and colon were unremarkable.

Pancreas

Slight heterogeneous parenchymal changes noted in the right **pancreatic limb**.

ULTRASONOGRAPHIC FINDINGS

- Mild gastritis, pyloric hypertrophy



PATIENT

- Possible very low-grade pancreatitis

Cassie Krueger

INTERPRETATION OF THE FINDINGS & FURTHER RECOMMENDATIONS

No evidence of foreign body. A clinical trial of the following may prove effective.

SPECIES

Helicobacter/Gastritis protocol

Canine

A clinical trial of **Zithromax (Dogs: 5-10 mg/kg p.o. q24h. May increase dosing interval to q48h after 3-5 days of treatment), Metronidazole (10-20 mg/kg p.o. b.i.d.), Pepcid (0.5-1 mg/kg s.i.d.) and Sucralfate (0.5-2 g/dog PO) or Omeprazole (1 mg/kg p.o. s.i.d.)** over the next 3 weeks along with a **novel-protein or hydrolyzed diet** with slurry feeding b.i.d./t.i.d. over the next 2-4 days and then increase to canned diet bid. Dry food should be avoided over the next 4 weeks. A recheck sonogram to assess GI improvement or progression would be ideal in 4 weeks.

BREED

Maltese

SEX

Spayed Female

AGE

2 Years

WEIGHT

6.9 Pounds

INTERPRETED BY

Eric Lindquist, DMV
DABVP, Cert. IVUSS

IMAGING PERFORMED BY

Mayra Sanchez

HOSPITAL NAME

Sunset AH

REFERRING VET

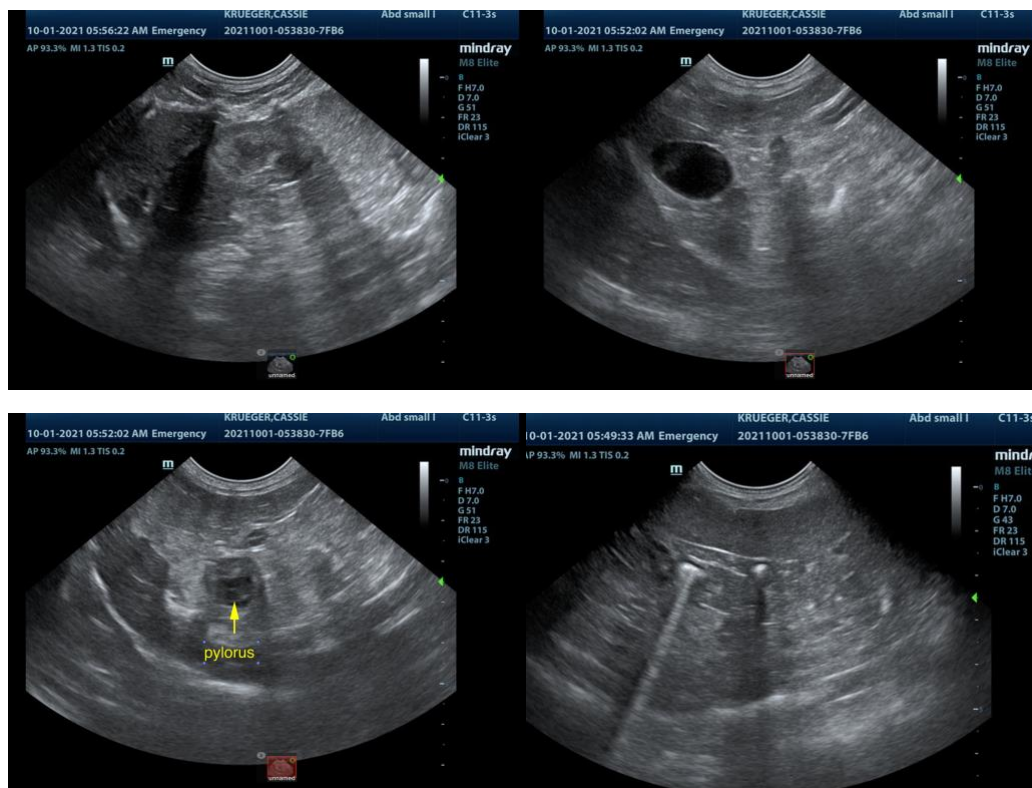
Cristina Polit

INVOICE

13452

DATE

10/2/21





PATIENT

Cassie Krueger

SPECIES

Canine

BREED

Maltese

SEX

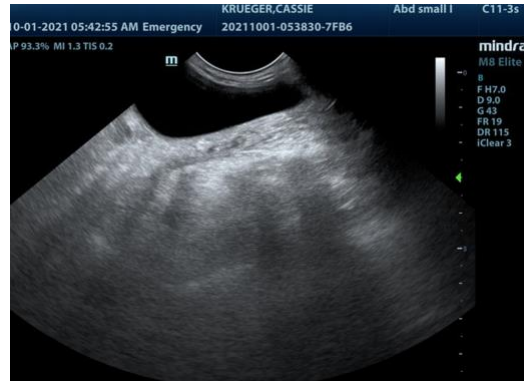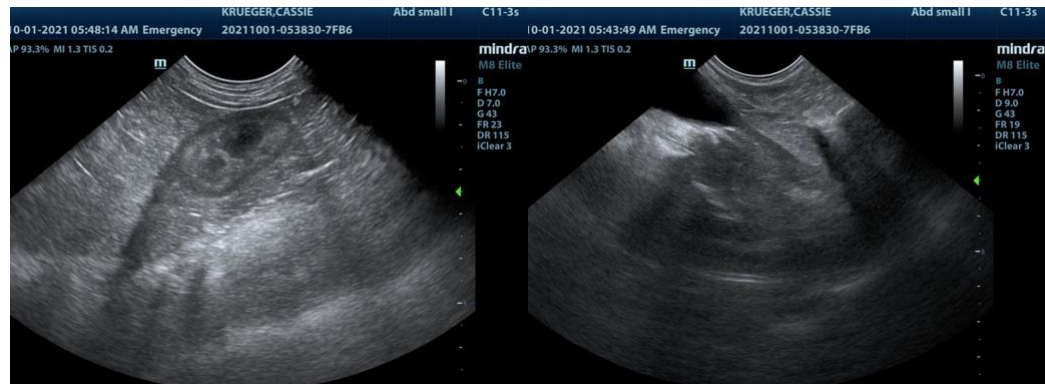
Spayed Female

AGE

2 Years

WEIGHT

6.9 Pounds



INTERPRETED BY

Eric Lindquist, DMV
DABVP, Cert. IVUSS

The information and recommendations provided are based on the images presented by the referring veterinarian. No evaluation can be communicated regarding pathology that was not visible in the image/video clips provided.

IMAGING PERFORMED BY

Mayra Sanchez

Thank you for this referral. If the clinical or image interpretation does not parallel your findings or if I can be of any further assistance please contact me.

Eric Lindquist, DMV, DABVP, Cert. IVUSS, CEO of SonoPath.com
info@SonoPath.com

HOSPITAL NAME

Sunset AH

REFERRING VET

Cristina Polit

INVOICE

13452

DATE

10/2/21