



PATIENT

Shayde Tazoi

SPECIES

Canine

BREED

Thailand Ridgeback

SEX

Neutered male

AGE

4 years

WEIGHT

60.8 lbs

INTERPRETED BY

Eric Lindquist, DMV
DABVP, Cert. IVUSS

IMAGING PERFORMED BY

Dr. Rupley

HOSPITAL NAME

All Pets Medical Center

REFERRING VET

Dr. Rupley

INVOICE

40176

DATE

10/19/22

PRESENTING CLINICAL SIGNS

History: Two dermal masses were excised 9/15/22: An approx 3x3 mm raised mass is present on the craniomedial proximal left stifle, and an approx 3x3 mm raised red or pigmented mass is present on the craniomedial distal left stifle. They were submitted for histopathology. Histologic diagnosis for both: Cutaneous hemangiosarcoma - completely excised. The pathologist made the following statement and the owners wished to pursue the recommendation: "Diagnostic imaging could also be considered to investigate the possibility of internal hemangiosarcoma." The full report is attached.

Abnormal PE/Chem/CBC/UA Results:

ULTRASONOGRAPHIC EXAMINATION OF THE ABDOMEN

Urinary System

The **urinary bladder**, trigone, and pelvic urethra presented normal thicknesses and normal tone. The ureters were not visible which is normal. No uroliths or sediment were visualized and anechoic urine was present. No evidence of inflammatory or neoplastic changes was noted. Ureteral papillae were normal.

The **kidneys** revealed normal size and structure, corticomedullary definition and ratio for this age. The cortices presented largely uniform texture with normal echogenic relationship to liver and spleen. Medullary structure differed distinctly from the cortex and no evidence of pelvic dilation was present. The capsules were acceptably uniform without significant irregularities. The left kidney measured 5.13 cm and the right kidney measured 6.15 cm.

Adrenal Glands

Both **adrenal glands** were visualized and recognized as having normal shape, size, position and echogenicity for this breed. The phrenic vasculature, glandular echogenicity and detail were unremarkable. Capsule, cortex, and medullary definition were normal for this age patient.

Spleen

The **spleen** in this patient was mildly enlarged with uniform parenchyma and was folded upon itself caudally. This is a positional variant and is not pathological. There was no evidence of significant disease.

Liver

The **liver** images submitted revealed subjectively normal liver size, contour, and structure. Parenchymal echogenicity was naturally coarse and hypoechoic to the spleen. Vascular and biliary tracts were of normal volume with no evidence of congestion. The gallbladder presented acceptably thin walls with primarily anechoic content. The cystic and common bile ducts were normal. No pathological hepatic lymphadenopathy was evident. No overt structural evidence of inflammatory, infiltrative or regenerative pathology was evident.



PATIENT

Shayde Tazoi

SPECIES

Canine

BREED

Thailand Ridgeback

SEX

Neutered male

AGE

4 years

WEIGHT

60.8 lbs

INTERPRETED BY

Eric Lindquist, DMV
DABVP, Cert. IVUSS

IMAGING PERFORMED BY

Dr. Rupley

HOSPITAL NAME

All Pets Medical Center

REFERRING VET

Dr. Rupley

INVOICE

40176

DATE

10/19/22

Gastrointestinal

Examination of the **gastrointestinal tract** revealed a stomach and intestine free of stasis, of normal wall thickness, acceptable curvilinear mural detail, and peristaltic activity. Small and large intestine demonstrated normal luminal chyme and stool consistency respectively. No obstructive or overt infiltrative disease was noted. No associated abnormal lymphatic activity was noted.

Pancreas

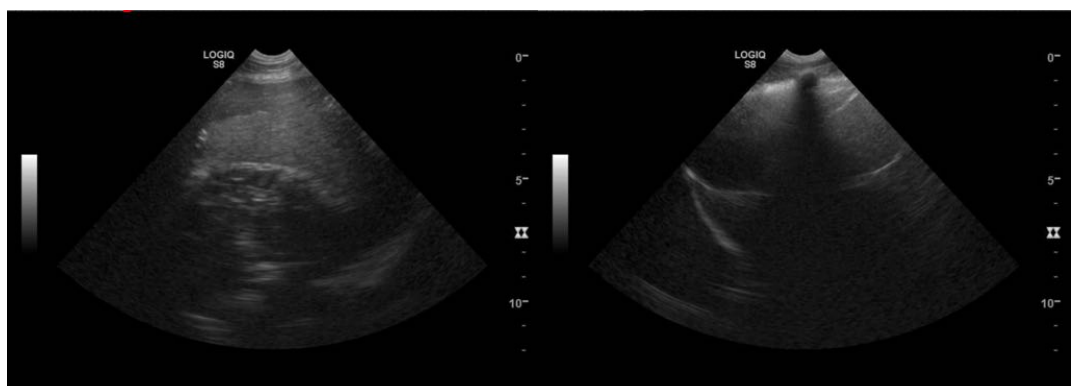
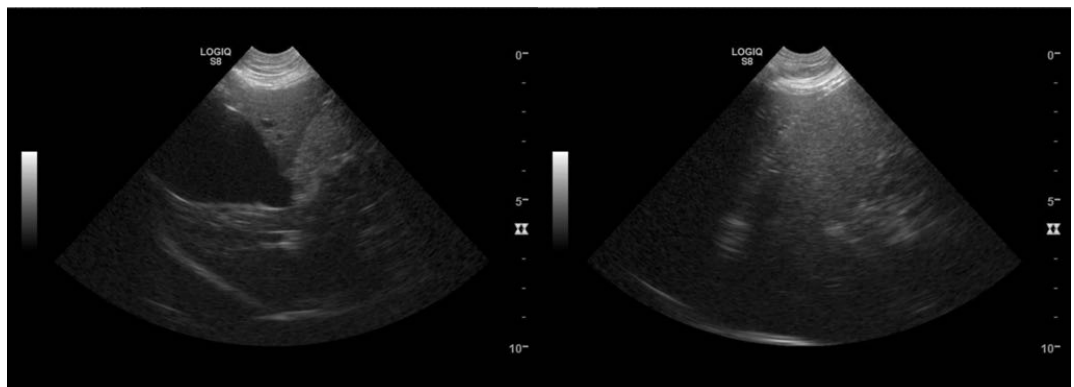
The base and limbs of the **pancreas** were observed to be largely isoechoic to surrounding omental fat. Pancreatic duct and capsular contour were acceptably normal and parenchyma respected normal curvilinear patterns. No overt evidence of active inflammatory or neoplastic disease was noted.

ULTRASONOGRAPHIC FINDINGS

Structurally unremarkable abdomen.

INTERPRETATION OF THE FINDINGS & FURTHER RECOMMENDATIONS

There was no evidence of metastatic or primary disease.





PATIENT

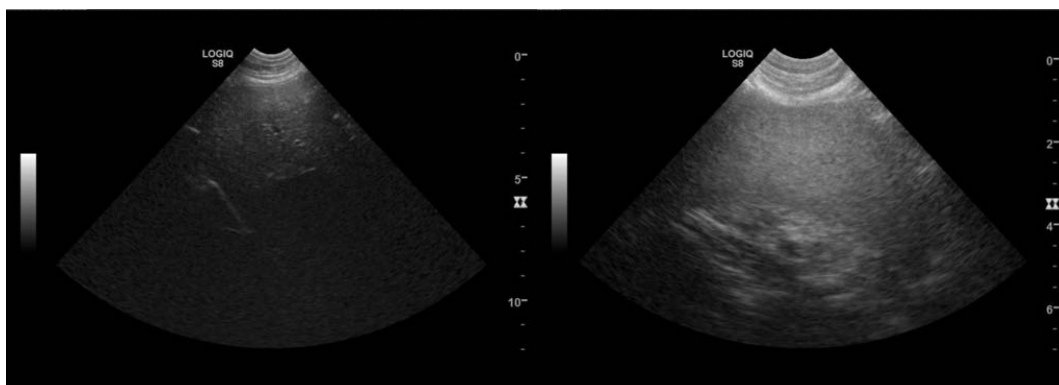
Shayde Tazoi

SPECIES

Canine

BREED

Thailand Ridgeback



SEX

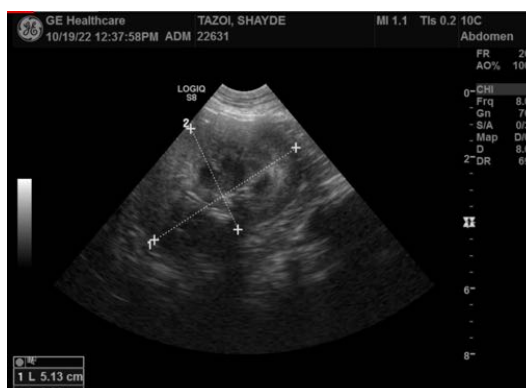Neutered male

AGE

4 years

WEIGHT

60.8 lbs



INTERPRETED BY

Eric Lindquist, DMV
DABVP, Cert. IVUSS

IMAGING PERFORMED BY

Dr. Rupley

HOSPITAL NAME

All Pets Medical Center

REFERRING VET

Dr. Rupley

INVOICE

40176

DATE

10/19/22

The information and recommendations provided are based on the images presented by the referring veterinarian/sonographer. No evaluation can be communicated regarding pathology that was not visible in the image/video clips provided.

Thank you for this referral. If the clinical or image interpretation does not parallel your findings or if I can be of any further assistance please contact me.

Eric Lindquist, DMV, DABVP, Cert. IVUSS, CEO of SonoPath.com
info@SonoPath.com