

**DATE PRESENTING CLINICAL SIGNS**

10/19/22

Urinary issues.
Current Medications: None.
Date of Previous IntraPet Ultrasound: No previous.

PATIENT

Dexter Barrett

Sedation: Not required to complete full diagnostic ultrasound.
Stat Report: Not requested.
Imaging Performed By: Rachel Brillhart, RDMS.

SPECIES

Canine

ULTRASONOGRAPHIC EXAMINATION OF THE ABDOMEN**Urinary System**

The **urinary bladder**, trigone, and pelvic urethra presented normal thicknesses and normal tone. The ureters were not visible which is normal. No uroliths or sediment were visualized and anechoic urine was present. No evidence of inflammatory or neoplastic changes was noted. Ureteral papillae were normal.

BREED

Pekingese

The **prostate** was uniformly enlarged with lobar swelling appeared to impinge upon the urethra and mildly deviate the descending colon. The prostatic tissue was hyperechoic containing focal areas of decreased echogenicity. Multi-focal, anechoic cysts were noted and measured up to 0.7 cm. Periprostatic cysts were noted as well in an early phase measuring approximately 1.0 cm.

SEX

Intact male

The testicles were imaged and found to be uniform.

AGE

10/5/14

The **kidneys** revealed normal size and structure, corticomedullary definition and ratio for this age. The cortices presented largely uniform texture with normal echogenic relationship to liver and spleen. Medullary structure differed distinctly from the cortex and no evidence of pelvic dilation was present. The capsules were acceptably uniform without significant irregularities. The left kidney measured 4.75 cm. The right kidney measured 4.81 cm.

WEIGHT

17 lbs

INTERPRETED BYEric Lindquist, DMV
DABVP, Cert. IVUSS**Adrenal Glands**

Both **adrenal glands** were visualized and recognized as having normal shape, size, position and echogenicity for this breed. The phrenic vasculature, glandular echogenicity and detail were unremarkable. Capsule, cortex, and medullary definition were normal for this age patient. The left adrenal gland measured 2.07 x 0.58 cm at the caudal pole and 0.59 cm at the cranial pole. The right adrenal gland measured 1.82 x 0.47 cm at the caudal pole and 0.56 cm at the cranial pole.

HOSPITAL NAME

Mount Airy AH

Spleen**REFERRING VET**

Dr. Riley

The **spleen** presented a smooth homogeneous parenchyma hyperechoic to liver and renal cortical parenchyma. The capsule was smooth without noticeable expansion or deviation from within the spleen or adjacent pathology. The splenic vasculature demonstrated normal volume without signs of congestion or thrombosis. No sonographic evidence of acute or chronic inflammatory, neoplastic, or infarctual changes was noted.

INVOICE

40160

Liver

The **liver** images submitted revealed subjectively normal liver contour and structure. Mild microhepatica was noted. Parenchymal echogenicity was naturally coarse and hypoechoic to the spleen. Vascular and biliary tracts were of normal volume with no evidence of congestion. The gallbladder presented acceptably thin walls with primarily anechoic content. The cystic and common bile ducts were normal. No pathological hepatic lymphadenopathy was evident. No overt structural evidence of inflammatory, infiltrative or regenerative pathology was evident.

Gastrointestinal

Examination of the **gastrointestinal tract** revealed a stomach and intestine free of stasis, of normal wall thickness, acceptable curvilinear mural detail, and peristaltic activity. Small and large intestine demonstrated normal luminal chyme and stool consistency respectively. No obstructive or overt infiltrative disease was noted. No associated abnormal lymphatic activity was noted.

Pancreas

The base and limbs of the **pancreas** were observed to be largely isoechoic to surrounding omental fat. Pancreatic duct and capsular contour were acceptably normal and parenchyma respected normal curvilinear patterns. No overt evidence of active inflammatory or neoplastic disease was noted.

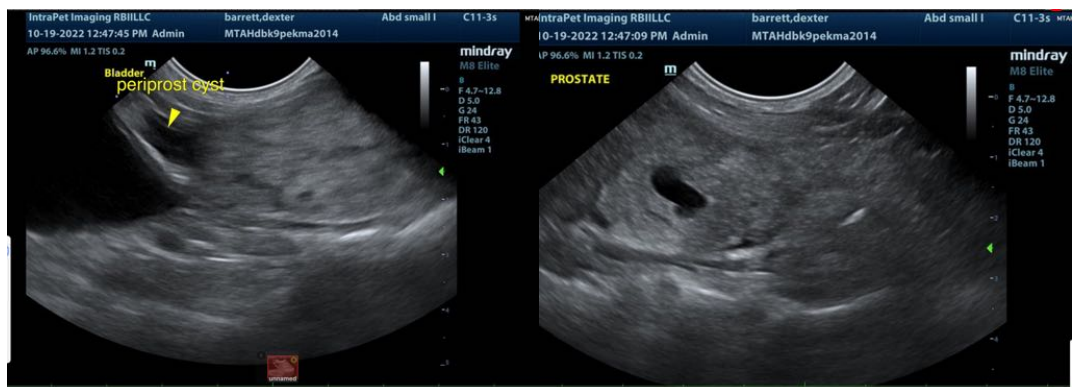
ULTRASONOGRAPHIC FINDINGS

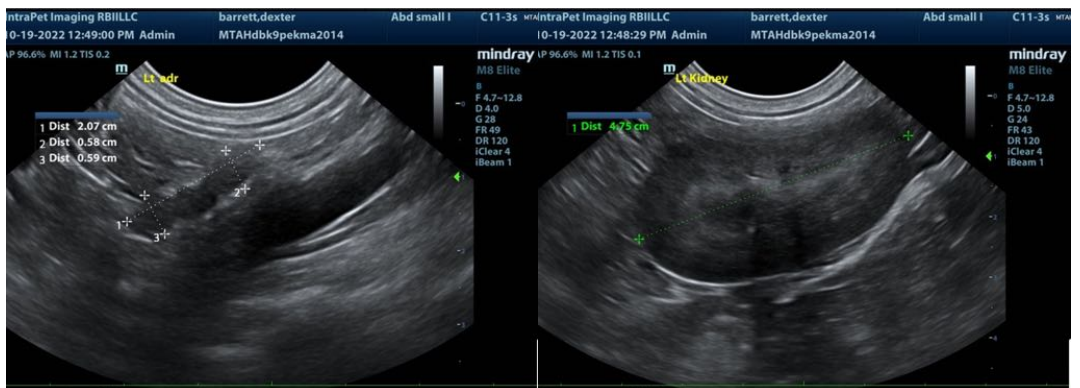
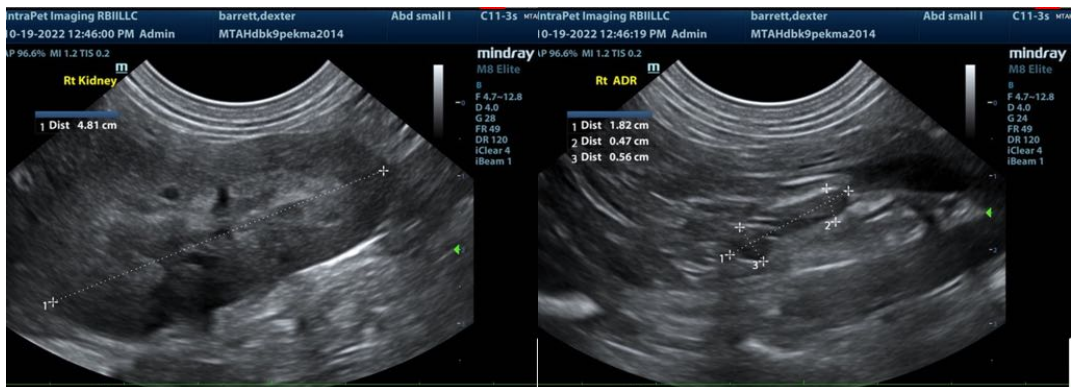
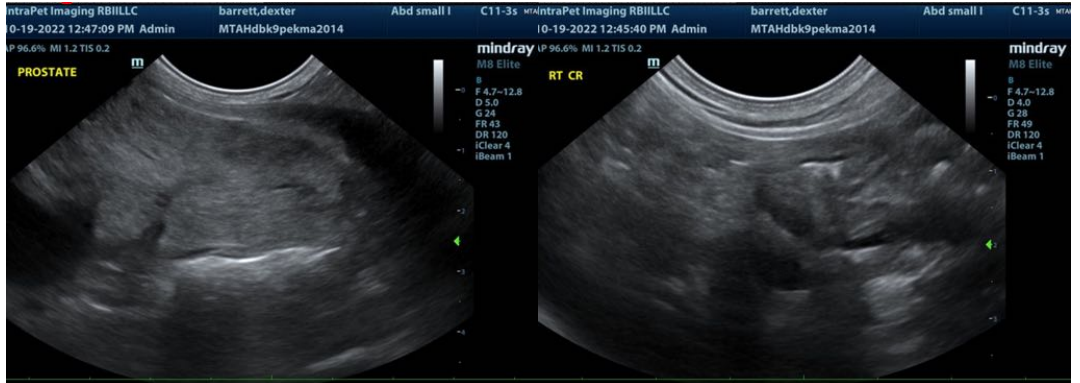
BPH prostate with cystic changes.
Early emerging paraprostatic cysts.
Mild microhepatica.

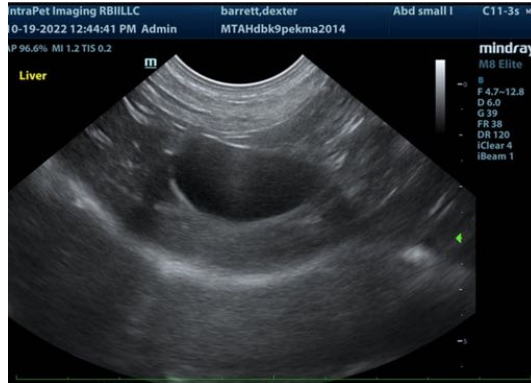
INTERPRETATION OF THE FINDINGS & FURTHER RECOMMENDATIONS

Neutering is strongly recommended in this patient then the following protocol can be considered. There was no evidence of portosystemic shunting.

Finasteride at 1 mg/kg/day can be utilized as an off-label approach to reducing prostatic size in BPH cases. Coverage for prostatitis would also likely be appropriate with Fluoroquinolone/Baytril or similar. A recheck sonogram is recommended in 3-4 weeks with reassessment of the urinalysis and evaluation of any inflammatory sediment.







The information and recommendations provided are based on the images presented by the referring veterinarian. No evaluation can be communicated regarding pathology that was not visible in the image/video clips provided.

Thank you for this referral. If the clinical or image interpretation does not parallel your findings or if I can be of any further assistance please contact me.

Eric Lindquist, DMV, DABVP, Cert. IVUSS, CEO of SonoPath.com
Eric.Lindquist@SonoPath.com