



PATIENT

Tommy Ma

SPECIES

Canine

BREED

Shiba Inu

SEX

Neutered Male

AGE

2009

WEIGHT

34 lbs

INTERPRETED BY

Eric Lindquist, DMV
DABVP, Cert IVUSS

**IMAGING
PERFORMED BY**

Denise Bruno, LVT,
RDMS

HOSPITAL NAME

Brooklyn Heights VH

REFERRING VET

Dr. Thomson

INVOICE

0000

DATE

10/19/21

PRESENTING CLINICAL SIGNS

History: Cough is currently on Temeril P + Doxycycline – improved

Hx hypertension, Proteinuria, ^ALP > 2000

Evaluate for early cushing's, hepatitis, neoplasia

Labs, Radiograph, + previous AUS attached

ULTRASONOGRAPHIC EXAMINATION OF THE ABDOMEN

Urinary System

The **urinary bladder**, trigone, and pelvic urethra presented normal thicknesses and normal tone. The ureters were not visible which is normal. No uroliths or sediment were visualized and anechoic urine was present. No evidence of inflammatory or neoplastic changes was noted. Ureteral papillae were normal.

The residual prostate measured 0.54 cm.

The **kidneys** revealed largely normal size and structure, corticomedullary definition and ratio (cortex 1/3 of medulla) were essentially maintained with some age-related loss of curvilinear patterns regarding the capsule and C/M junction. The cortices presented largely uniform texture with some increased echogenicity expected for this age patient. Medullary structure differed distinctly from that of the cortex and no evidence of pelvic dilation was present. The right kidney measured 4.62 cm. The left kidney measured 4.7 cm.

Adrenal Glands

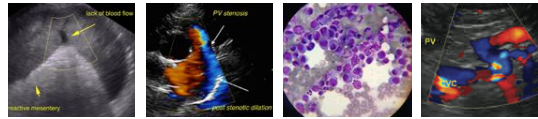
Both **adrenal glands** were visualized and recognized as having normal shape, size, position and echogenicity for this breed. The phrenic vasculature, glandular echogenicity and detail were unremarkable. Capsule, cortex, and medullary definition were normal for this age patient. The right adrenal gland measured 2.49 x 1.02 cm at the caudal pole and 0.92 cm at the cranial pole. The left adrenal gland measured 2.3 x 0.58 cm at the caudal pole and 0.54 cm at the cranial pole.

Spleen

The **spleen** presented a smooth homogeneous parenchyma hyperechoic to liver and renal cortical parenchyma. The capsule was smooth without noticeable expansion or deviation from within the spleen or adjacent pathology. The splenic vasculature demonstrated normal volume without signs of congestion or thrombosis. No sonographic evidence of acute or chronic inflammatory, neoplastic, or infarctual changes was noted.

Liver

The **liver** was uniformly swollen with minor, excessive gallbladder debris and over distension with dependent and suspended bile without evidence of overt mucocele formation. However, excessive sludge was present. The liver presented coarse architecture with mildly increased portal markings and subtle, mixed echogenic changes. This is consistent with vacuolar hepatopathy and some level of remodeling and history of inflammatory component. There was no overt suspicion of neoplasia.



PATIENT

Gastrointestinal

Tommy Ma

Examination of the **gastrointestinal tract** revealed a stomach and intestine free of stasis, of normal wall thickness, acceptable curvilinear mural detail, and peristaltic activity. Small and large intestine demonstrated normal luminal chyme and stool consistency respectively. No obstructive or overt infiltrative disease was noted. No associated abnormal lymphatic activity was noted.

SPECIES

Canine

BREED

Shiba Inu

Pancreas

The base and limbs of the **pancreas** were observed to be largely isoechoic to surrounding omental fat. Pancreatic duct and capsular contour were acceptably normal and parenchyma respected normal curvilinear patterns. No overt evidence of active inflammatory or neoplastic disease was noted.

SEX

Neutered Male

ULTRASONOGRAPHIC FINDINGS

Benign hepatopathy.

AGE

Age related renal changes.

2009

WEIGHT

34 lbs

INTERPRETATION OF THE FINDINGS & FURTHER RECOMMENDATIONS

The changes are largely expected for this age patient. Low-grade pancreatic inflammation cannot be completely ruled out, yet subjectively the abdomen appears benign.

INTERPRETED BY

Eric Lindquist, DMV
DABVP, Cert IVUSS

IMAGING PERFORMED BY

Denise Bruno, LVT,
RDMS

HOSPITAL NAME

Brooklyn Heights VH

REFERRING VET

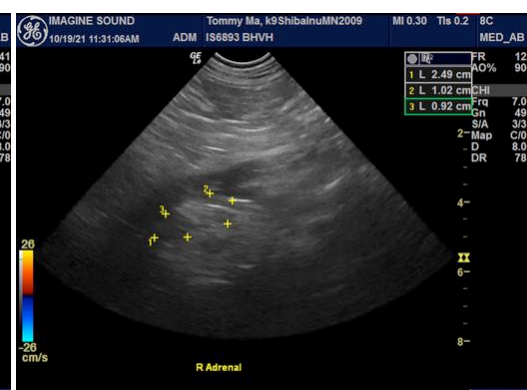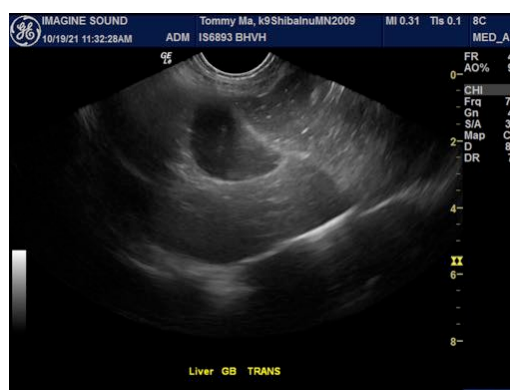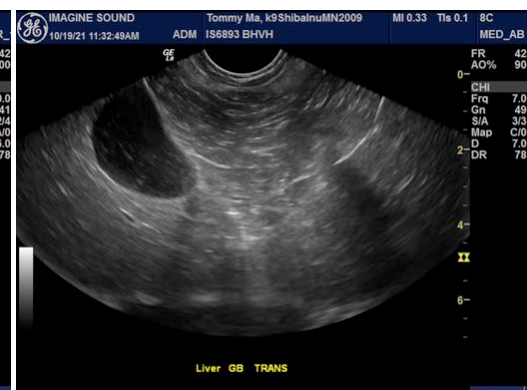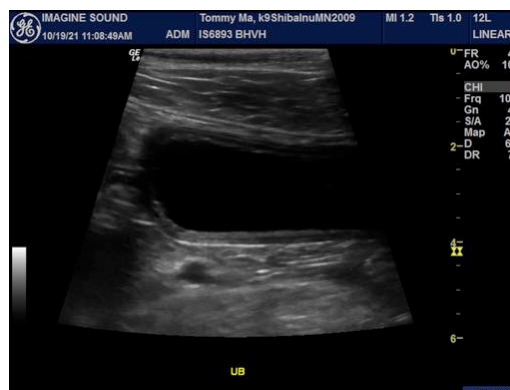Dr. Thomson

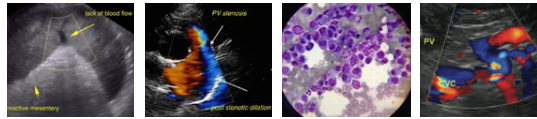
INVOICE

0000

DATE

10/19/21





PATIENT

Tommy Ma

SPECIES

Canine

BREED

Shiba Inu

SEX

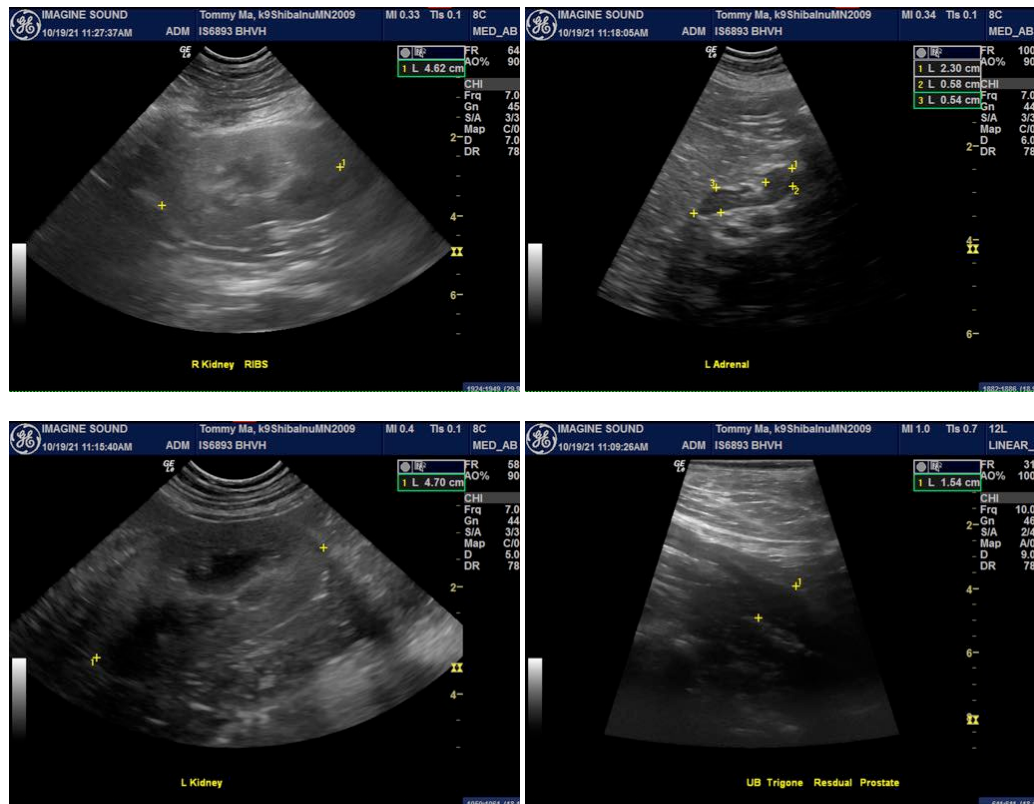
Neutered Male

AGE

2009

WEIGHT

34 lbs



INTERPRETED BY

Eric Lindquist, DMV
DABVP, Cert IVUSS

IMAGING PERFORMED BY

Denise Bruno, LVT,
RDMS

HOSPITAL NAME

Brooklyn Heights VH

REFERRING VET

Dr. Thomson

INVOICE

0000

DATE

10/19/21

The information and recommendations provided are based on the images presented by the referring veterinarian. No evaluation can be communicated regarding pathology that was not visible in the image/video clips provided.

Thank you for this referral. If the clinical or image interpretation does not parallel your findings or if I can be of any further assistance please contact me.

Eric Lindquist, DMV, DABVP, Cert. IVUSS, CEO of SonoPath.com
Eric.Lindquist@SonoPath.com