



PATIENT PRESENTING CLINICAL SIGNS

Patient: Pearl Stern
History: History of grade 3-4/6 left systolic murmur. Asymptomatic. Last echo Jan 2021. No current meds
Abnormal PE/Chem/CBC/UA Results: WNL

SPECIES

Canine

ULTRASONOGRAPHIC EXAMINATION OF THE HEART

BREED

Mix

SEX

Spayed Female

AGE

10 years

WEIGHT

14.5 lbs

The echocardiogram in this patient demonstrated normal **left atrial** size based on 3 different LA measurement methods. Chamber volumes and echogenicity were normal. The cranial and caudal **mitral** valve leaflets presented vegetative thickening consistent with endocarditis. Doppler indicated measurable insufficiency. The **left ventricle** presented thicknesses with linear contour and was not dilated nor restricted. The **myocardium** presented normal echogenicity without subjective evidence of significant fibrotic or ischemic disease. **Contractility** of the ventricular walls was adequate and in normal range for this patient evidenced by the fractional shortening measurement and subjective evaluation of the different regions of the myocardium. The **left ventricular outflow** tract demonstrated normal laminar flow and subjective structural integrity. The **right atrium** and auricle revealed normal size, structure and content. No evidence of masses was noted or chamber overload. **Tricuspid** insufficiency was noted. The **right ventricle** was of normal size (1/3 diameter of LV), chordae structure, myocardial echogenicity and thickness. **Pulmonic** tract assessment revealed normal valve structure, laminar flow, and diameter (approx. 1:1 pa/ao ratio). No visible **pericardial** or free pleura fluid was noted. No echographically detectable evidence of infiltrative disease was visible. The cranial **mediastinum** and **pericardial regions** were free of masses in the visible window.

INTERPRETED BY

Eric Lindquist, DMV
 DABVP, Cert. IVUSS

IMAGING PERFORMED BY

Jessica Miller, RDMS

HOSPITAL NAME

Milburn VH

REFERRING VET

Dr. Turowsky

CANINE CARDIAC PARAMETERS	MR VMAX (m/s)	TR VMAX (m/s)	LA/AO (Boon method)	LA/AO (Heart Base; Swe)	FS (%)	EF (%)	EPSS (cm)
NORMAL PARAMETER	4.5-5.5	<2.7	1.3	<1.6	28-40	40-100	<0.6
PATIENT	5.04	2.24	1.55	1.6	36	67	NM
CANINE CARDIAC PARAMETERS	HR (BPM)	AV VMAX (m/s)	PV MAX (m/s)	BODY WEIGHT	LA (2D short axis Base view) (cm)	LVIDd (Avg; 2D and m-mode short axis) (cm)	LVIDs (Avg; 2D and m-mode short axis) (cm)
NORMAL PARAMETER	50-100	0.7-1.7	0.7-1.6				
PATIENT	98	1.03	0.6	14.5 lbs	2.47	2.72	

ULTRASONOGRAPHIC FINDINGS

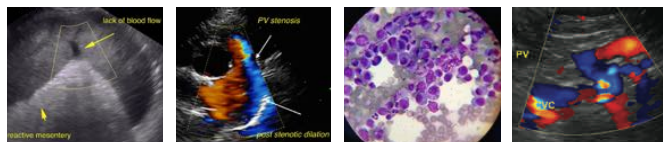
Persistent Stage B1 valvular disease.

INVOICE

92470

DATE

10/19/21



PATIENT

Pearl Stern

SPECIES

Canine

BREED

Mix

SEX

Spayed Female

AGE

10 years

WEIGHT

14.5 lbs

INTERPRETED BY

Eric Lindquist, DMV
DABVP, Cert. IVUSS

IMAGING PERFORMED BY

Jessica Miller, RDMS

HOSPITAL NAME

Milburn VH

REFERRING VET

Dr. Turowsky

INVOICE

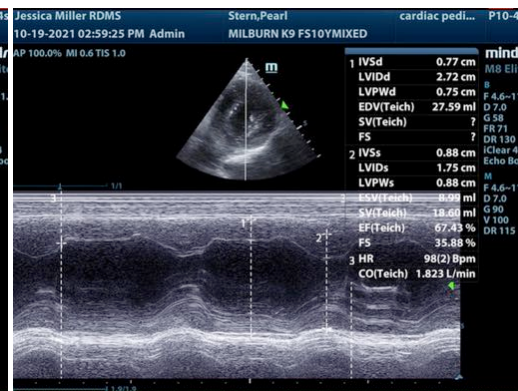
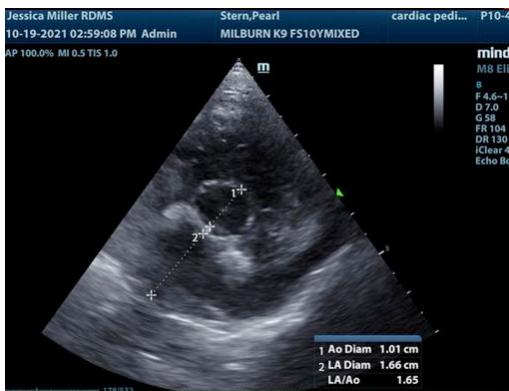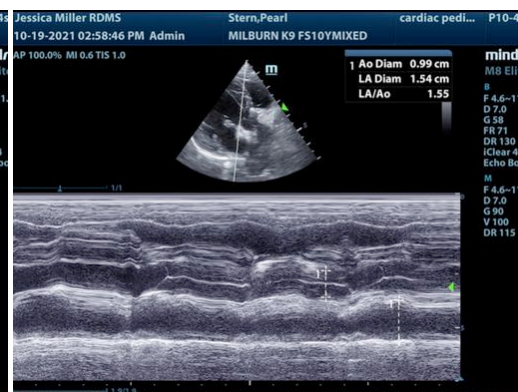
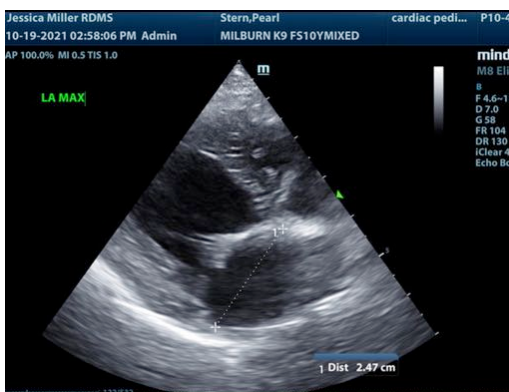
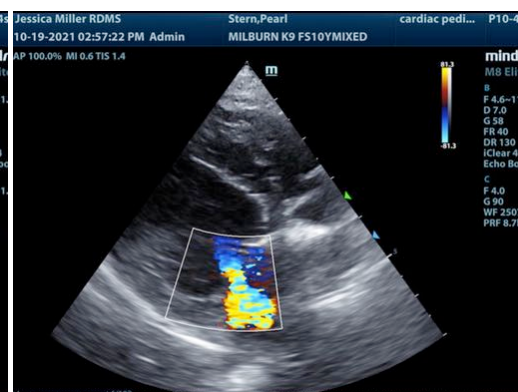
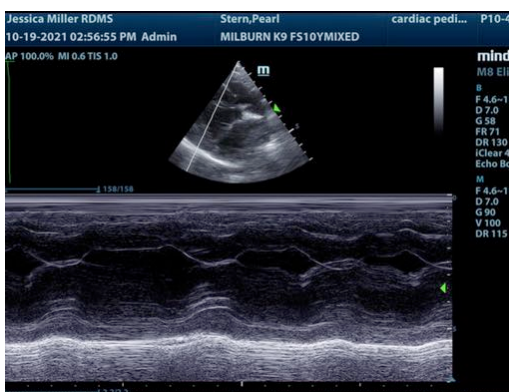
92470

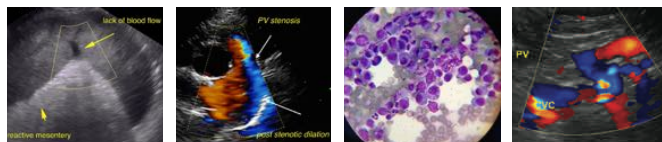
DATE

10/19/21

INTERPRETATION OF THE FINDINGS & FURTHER RECOMMENDATIONS

There is no significant change compared to the prior sonogram. If anesthesia is necessary, there is no overt contraindication to an anesthetic procedure. Suggested protocol includes Torbutrol premed, Propofol induction, and Isoflurane maintenance. Recheck echocardiogram in 6 months or earlier if murmur grade increases or clinical signs initiate.





PATIENT

Pearl Stern

SPECIES

Canine

BREED

Mix

SEX

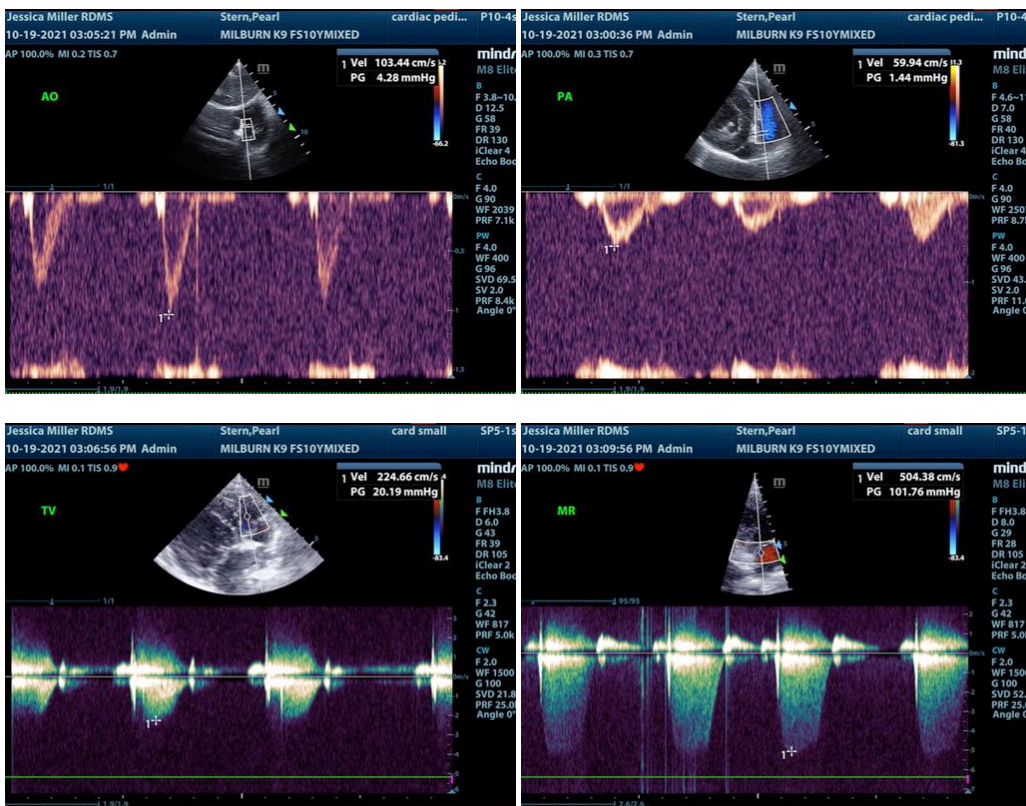
Spayed Female

AGE

10 years

WEIGHT

14.5 lbs



INTERPRETED BY

Eric Lindquist, DMV
DABVP, Cert. IVUSS

IMAGING PERFORMED BY

Jessica Miller, RDMS

HOSPITAL NAME

Milburn VH

REFERRING VET

Dr. Turowsky

INVOICE

92470

DATE

10/19/21

The information and recommendations provided are based on the images presented by the referring veterinarian. No evaluation can be communicated regarding pathology that was not visible in the image/video clips provided.

Thank you for this referral. If the clinical or image interpretation does not parallel your findings or if I can be of any further assistance please contact me.

Eric Lindquist, DMV, DABVP, Cert. IVUSS, CEO of SonoPath.com
info@SonoPath.com