**PATIENT**

Onyx Morales

**SPECIES**

Canine

**BREED**

Yorkie

**SEX**

Neutered Male

**AGE**

7 years

**WEIGHT**

13 Pounds

**INTERPRETED BY**Eric Lindquist, DMV  
DABVP, Cert. IVUSS**IMAGING PERFORMED BY**

Sarah Pender, CVT

**HOSPITAL NAME**

SVS Imaging QC

**REFERRING VET**

Dr. White

**INVOICE**

92502

**DATE**

10/19/21

**PRESENTING CLINICAL SIGNS**

History: 10/16/21 presented seizing. Glucose 84, gave Pentobarbital to effect, T106.5 hospitalized on IVF. 10/17/21 could not urinate. Rads: stone in urethra. Placed urinary catheter and continued IV Fluids. Catheters removed went home. 10/18/21 returned could not urinate. Placed another urinary catheter.

CREA 0.4, BUN 2, ALB 2.2, ALT 196, AMYL 303, PLT 83 PCT 0.12 Concern for shunt

**ULTRASONOGRAPHIC EXAMINATION OF THE ABDOMEN****Urinary System**

The **urinary bladder**, trigone, and pelvic urethra presented normal thicknesses and normal tone. The ureters were not visible which is normal. The bladder revealed small calculi, a grouping of which measured 1.0 cm with suspended debris and were present in the urethra. No evidence of inflammatory or neoplastic changes was noted. Ureteral papillae were normal.

The **kidneys** revealed normal size and structure, corticomedullary definition and ratio for this age. The cortices presented largely uniform texture with normal echogenic relationship to liver and spleen. Medullary structure differed distinctly from the cortex and no evidence of pelvic dilation was present. The capsules were acceptably uniform without significant irregularities. The right kidney measured 5.73 cm with pelvic and corticomedullary mineralization. The left kidney measured 5.41 cm.

**Adrenal Glands**

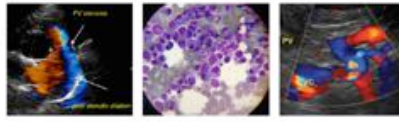
Both **adrenal glands** were visualized and recognized as having normal shape, size, position and echogenicity for this breed. The phrenic vasculature, glandular echogenicity and detail were unremarkable. Capsule, cortex, and medullary definition were normal for this age patient. The left adrenal gland measured 0.49 cm at the caudal pole and 0.48 cm at the cranial pole and 1.85 cm in length. The right adrenal gland measured 1.95 x 0.89 cm at the cranial pole and 0.3 cm at the caudal pole.

**Spleen**

The **spleen** presented a smooth homogeneous parenchyma hyperechoic to liver and renal cortical parenchyma. The capsule was smooth without noticeable expansion or deviation from within the spleen or adjacent pathology. The splenic vasculature demonstrated normal volume without signs of congestion or thrombosis. No sonographic evidence of acute or chronic inflammatory, neoplastic, or infarctual changes was noted.

**Liver**

The **liver** was mildly subnormal in size. The parenchyma was unremarkable and the liver was subjectively hypovascular. There was no overt evidence of intrahepatic shunts noted, yet full sedation would be necessary for visualization of the portal vein at the portal hilus with the vena cava and aortic ratio. The gallbladder presented acceptably thin walls with primarily anechoic content. The cystic and common bile ducts were normal. No pathological hepatic lymphadenopathy was evident. No overt structural evidence of inflammatory, infiltrative or regenerative pathology was evident.



**PATIENT**

Onyx Morales

**Gastrointestinal**

**SPECIES**

Canine

Examination of the **gastrointestinal tract** revealed a stomach and intestine free of stasis, of normal wall thickness, acceptable curvilinear mural detail, and peristaltic activity. Small and large intestine demonstrated normal luminal chyme and stool consistency respectively. No obstructive or overt infiltrative disease was noted. No associated abnormal lymphatic activity was noted.

**BREED**

Yorkie

**Pancreas**

The base and limbs of the **pancreas** were observed to be largely isoechoic to surrounding omental fat. Pancreatic duct and capsular contour were acceptably normal and parenchyma respected normal curvilinear patterns. No overt evidence of active inflammatory or neoplastic disease was noted.

**SEX**

Neutered Male

**AGE**

7 years

**ULTRASONOGRAPHIC FINDINGS**

Renal calculi.

Bladder calculi.

**WEIGHT**

13 Pounds

Subnormal hepatic size.

**INTERPRETATION OF THE FINDINGS & FURTHER RECOMMENDATIONS**

**INTERPRETED BY**

Eric Lindquist, DMV  
DABVP, Cert. IVUSS

The calculi were non-obstructive at the time of the sonogram. If bile acids are elevated then further imaging with full sedation would be recommended. The cause of fever is unknown. Eventual cystotomy would be necessary with stone analysis and culture. However, I do recommend further imaging of the portal hilus either with ultrasound under sedation or CT. CT of the brain would also be ideal given the seizure activity.

**IMAGING PERFORMED BY**

Sarah Pender, CVT

**HOSPITAL NAME**

SVS Imaging QC

**REFERRING VET**

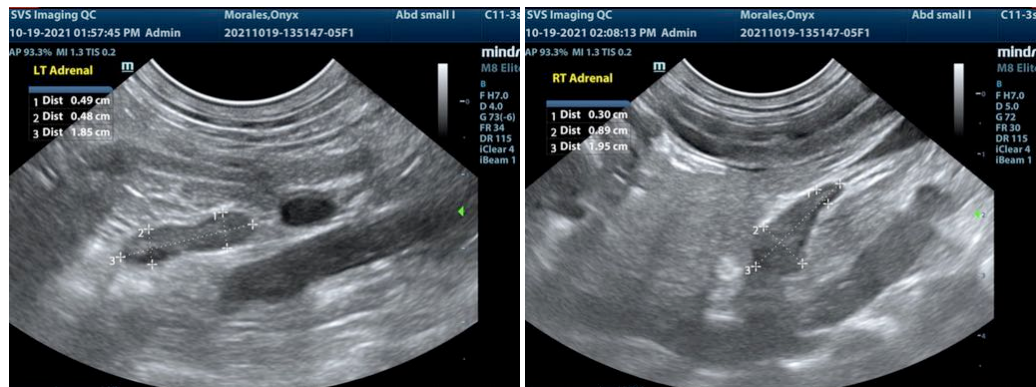
Dr. White

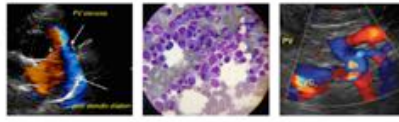
**INVOICE**

92502

**DATE**

10/19/21





**PATIENT**

Onyx Morales

**SPECIES**

Canine

**BREED**

Yorkie

**SEX**

Neutered Male

**AGE**

7 years

**WEIGHT**

13 Pounds

**INTERPRETED BY**

Eric Lindquist, DMV  
DABVP, Cert. IVUSS

**IMAGING  
PERFORMED BY**

Sarah Pender, CVT

**HOSPITAL NAME**

SVS Imaging QC

**REFERRING VET**

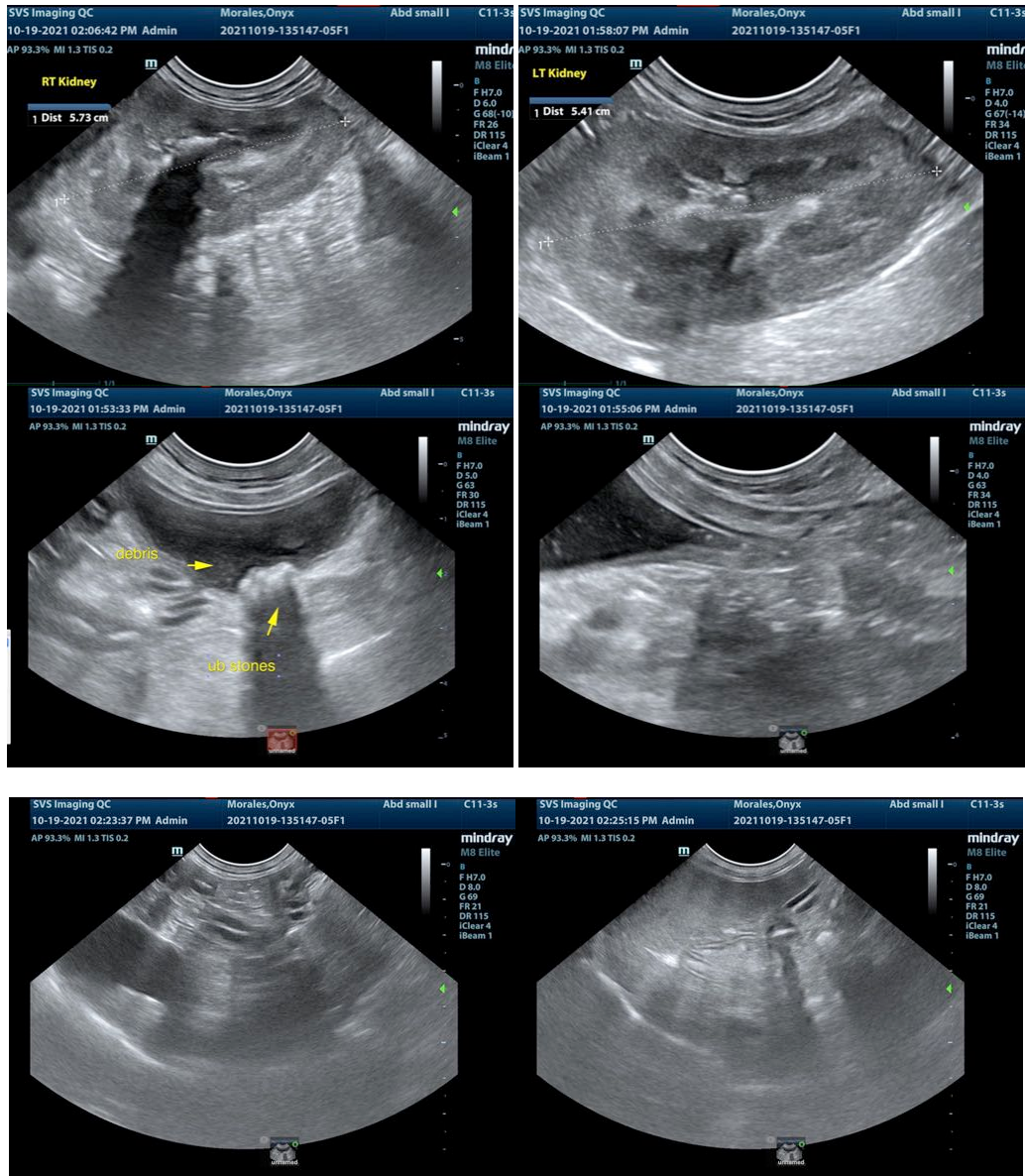
Dr. White

**INVOICE**

92502

**DATE**

10/19/21



The information and recommendations provided are based on the images presented by the referring veterinarian. No evaluation can be communicated regarding pathology that was not visible in the image/video clips provided.

Thank you for this referral. If the clinical or image interpretation does not parallel your findings or if I can be of any further assistance please contact me.

Eric Lindquist, DMV, DABVP, Cert. IVUSS, CEO of SonoPath.com  
Eric.Lindquist@SonoPath.com