



PATIENT

PRESENTING CLINICAL SIGNS

Double Stuffed Peters

History: Ultrasound performed to look for intestinal mass diagnosed from referring veterinary clinic. Inappetence, vomiting consistently. O hoping to go to surgery asap. Positive Murphy upper right quadrant. Bruising noticed over left mid abdomen.

SPECIES

Feline

BREED

Domestic Shorthair

SEX

Spayed Female

AGE

11 years

WEIGHT

11 lbs

ULTRASONOGRAPHIC EXAMINATION OF THE ABDOMEN

Urinary System

The **urinary bladder**, trigone, and pelvic urethra presented normal thicknesses and normal tone. The ureters were not visible which is normal. No uroliths or sediment were visualized and anechoic urine was present. No evidence of inflammatory or neoplastic changes was noted. Ureteral papillae were normal.

The **kidneys** revealed largely normal size and structure, corticomedullary definition and ratio (cortex 1/3 of medulla) were essentially maintained with some age-related loss of curvilinear patterns regarding the capsule and C/M junction. The cortices presented largely uniform texture with some increased echogenicity expected for this age patient. Medullary structure differed distinctly from that of the cortex and no evidence of pelvic dilation was present. Slight mineralization was noted. The kidneys measured 3.0 cm.

INTERPRETED BY

Eric Lindquist, DMV
DABVP, Cert. IVUSS

Adrenal Glands

Both **adrenal glands** were visualized and recognized as having normal shape, size, position and echogenicity for this breed. The phrenic vasculature, glandular echogenicity and detail were unremarkable. Capsule, cortex, and medullary definition were normal for this age patient. Both adrenal glands measured 0.5 cm.

IMAGING PERFORMED BY

Dr. Waffle

Spleen

HOSPITAL NAME

Torch Lake VC

The **spleen** presented a smooth homogeneous parenchyma hyperechoic to liver and renal cortical parenchyma. The capsule was smooth without noticeable expansion or deviation from within the spleen or adjacent pathology. The splenic vasculature demonstrated normal volume without signs of congestion or thrombosis. No sonographic evidence of acute or chronic inflammatory, neoplastic, or infarctual changes was noted.

REFERRING VET

Dr. Waffle

INVOICE

92432

Liver

The **liver** presented polycystic changes with mild remodeling. There is no evidence of suspicion of neoplasia. The largest cyst measured approximately 3.0 cm in the caudate process. The gallbladder was unremarkable.

DATE

10/18/21



PATIENT

Double Stuffed Peters

SPECIES

Feline

BREED

Domestic Shorthair

SEX

Spayed Female

AGE

11 years

WEIGHT

11 lbs

INTERPRETED BY

Eric Lindquist, DMV
DABVP, Cert. IVUSS

IMAGING PERFORMED BY

Dr. Waffle

HOSPITAL NAME

Torch Lake VC

REFERRING VET

Dr. Waffle

INVOICE

92432

DATE

10/18/21

Gastrointestinal

Examination of the **gastrointestinal tract** revealed a stomach and intestine free of stasis, of normal wall thickness, acceptable curvilinear mural detail, and peristaltic activity. There was a mild amount of gastric stasis present. Small and large intestine demonstrated normal luminal chyme and stool consistency respectively. No obstructive or overt infiltrative disease was noted. No associated abnormal lymphatic activity was noted.

Pancreas

The base and limbs of the **pancreas** were observed to be largely isoechoic to surrounding omental fat. Some parenchymal remodeling, however, with mild deviation from curvilinear normalcy was observed. Pancreatic duct and capsular irregularities were present consistent with age related changes. If pain upon imaging (+ Murphy sign) was present or if the patient is focally painful in subxiphoid palpation then low-grade smoldering chronic pancreatitis should be suspected.

Free Abdomen

A large amount of abdominal fat was noted in this patient.

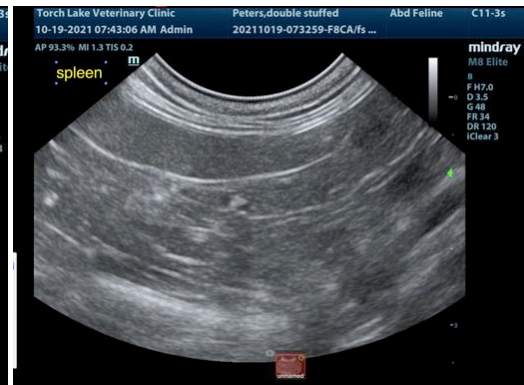
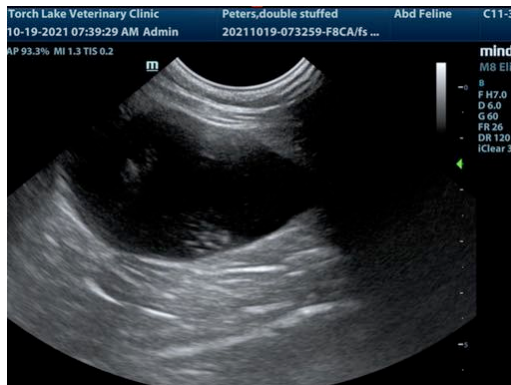
ULTRASONOGRAPHIC FINDINGS

Polycystic liver and excessive abdominal fat.

Moderate degenerative renal changes with mild to moderate degenerative hepatic changes mainly owing to the polycystic presentation.

INTERPRETATION OF THE FINDINGS & FURTHER RECOMMENDATIONS

There is no evidence of neoplasia.





PATIENT

Double Stuffed Peters

SPECIES

Feline

BREED

Domestic Shorthair

SEX

Spayed Female

AGE

11 years

WEIGHT

11 lbs

INTERPRETED BY

Eric Lindquist, DMV
DABVP, Cert. IVUSS

IMAGING PERFORMED BY

Dr. Waffle

HOSPITAL NAME

Torch Lake VC

REFERRING VET

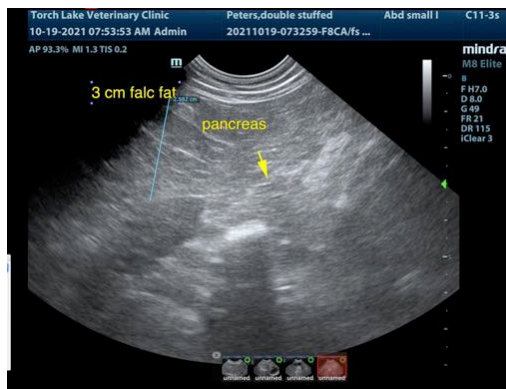
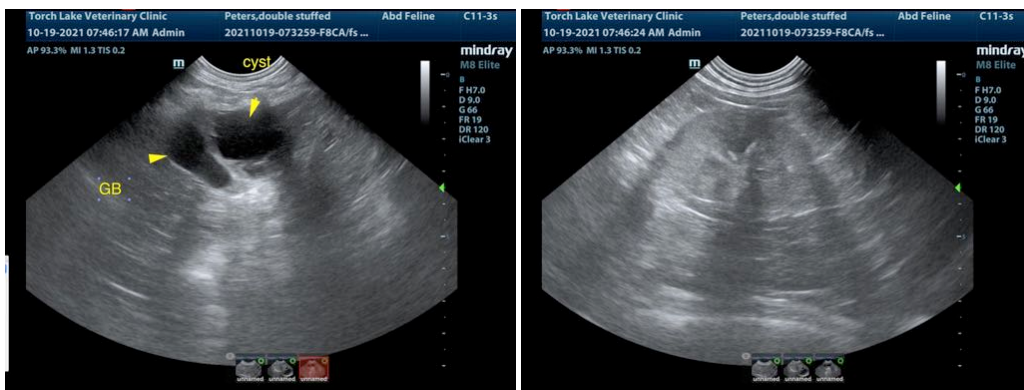
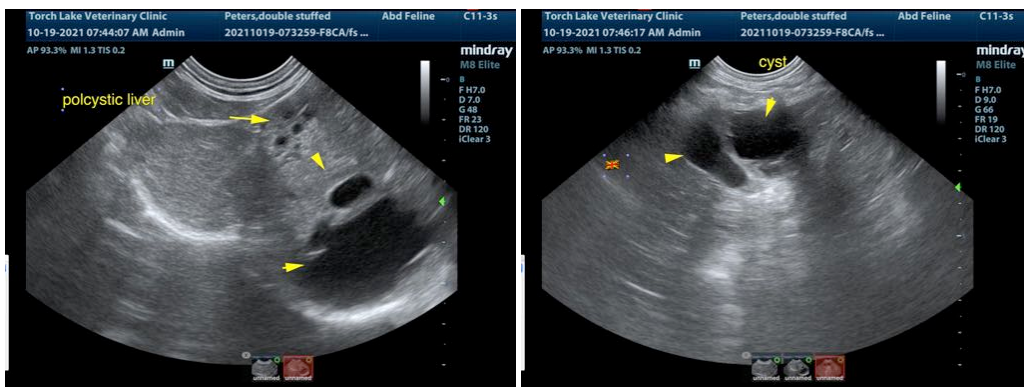
Dr. Waffle

INVOICE

92432

DATE

10/18/21



The information and recommendations provided are based on the images presented by the referring veterinarian. No evaluation can be communicated regarding pathology that was not visible in the image/video clips provided.

Thank you for this referral. If the clinical or image interpretation does not parallel your findings or if I can be of any further assistance please contact me.

Eric Lindquist, DMV, DABVP, Cert. IVUSS, CEO of SonoPath.com
info@SonoPath.com