



PATIENT

Collin Herig

PRESENTING CLINICAL SIGNS

History: recheck pyuria found on urine Cytology

SPECIES

Canine

ULTRASONOGRAPHIC EXAMINATION OF THE ABDOMEN

Urinary System

BREED

Collie Mix

The **urinary bladder** revealed a cystitis pattern with polypoid changes. A minimal amount of urine was present at the time of the sonogram. This presentation is most consistent with cystitis and secondary polyps. There is a mild potential for carcinoma.

SEX

Neutered male

The **kidneys** revealed largely normal size and structure, corticomedullary definition and ratio (cortex 1/3 of medulla) were essentially maintained with some age-related loss of curvilinear patterns regarding the capsule and C/M junction. The cortices presented largely uniform texture with some increased echogenicity expected for this age patient. Medullary structure differed distinctly from that of the cortex and no evidence of pelvic dilation was present. The left kidney measured 5.68 cm. The right kidney measured 4.0 cm.

AGE

10 years

WEIGHT

32.5 lbs

Adrenal Glands

Both **adrenal glands** were visualized and recognized as having normal shape, size, position and echogenicity for this breed. The phrenic vasculature, glandular echogenicity and detail were unremarkable. Capsule, cortex, and medullary definition were normal for this age patient. The right adrenal gland measured 2.35 x 1.34 cm at the cranial pole and 0.69 cm at the caudal pole. The left adrenal gland measured 1.84 x 0.82 cm.

INTERPRETED BY

Eric Lindquist, DMV
DABVP, Cert. IVUSS

IMAGING PERFORMED BY

Jenn

Spleen

The **spleen** presented a smooth homogeneous parenchyma hyperechoic to liver and renal cortical parenchyma. The capsule was smooth without noticeable expansion or deviation from within the spleen or adjacent pathology. The splenic vasculature demonstrated normal volume without signs of congestion or thrombosis. No sonographic evidence of acute or chronic inflammatory, neoplastic, or infarctual changes was noted.

HOSPITAL NAME

Rockaway AH

REFERRING VET

Dr. Maniar

Liver

The **liver** images from right and left intercostal as well as subcostal views revealed subjectively normal liver size, contour, and structure. Occasional parenchymal cysts were noted. Some age-related parenchymal remodeling was noted but likely not clinically significant at this time. Vascular and biliary tracts were of normal volume and no evidence of congestion was noted. The gallbladder presented some dependent debris with essentially normal contour. The cystic and common bile ducts were normal. No overt evidence of active inflammatory, infiltrative or regenerative pathology was noted but should be paired with current or past LE elevations regarding any clinical significance to this presentation. The hepatic lymph nodes were unremarkable.

INVOICE

92459

DATE

10/19/21



PATIENT *Gastrointestinal*

Collin Herig Examination of the **gastrointestinal tract** revealed a stomach and intestine free of stasis, of normal wall thickness, acceptable curvilinear mural detail, and peristaltic activity. Small and large intestine demonstrated normal luminal chyme and stool consistency respectively. No obstructive or overt infiltrative disease was noted. No associated abnormal lymphatic activity was noted.

SPECIES

Canine

BREED

Collie Mix

SEX

Neutered male

AGE

10 years

WEIGHT

32.5 lbs

INTERPRETED BY

Eric Lindquist, DMV
DABVP, Cert. IVUSS

IMAGING PERFORMED BY

Jenn

HOSPITAL NAME

Rockaway AH

REFERRING VET

Dr. Maniar

INVOICE

92459

DATE

10/19/21

Pancreas

The base and limbs of the **pancreas** were observed to be largely isoechoic to surrounding omental fat. Pancreatic duct and capsular contour were acceptably normal and parenchyma respected normal curvilinear patterns. No overt evidence of active inflammatory or neoplastic disease was noted.

ULTRASONOGRAPHIC FINDINGS

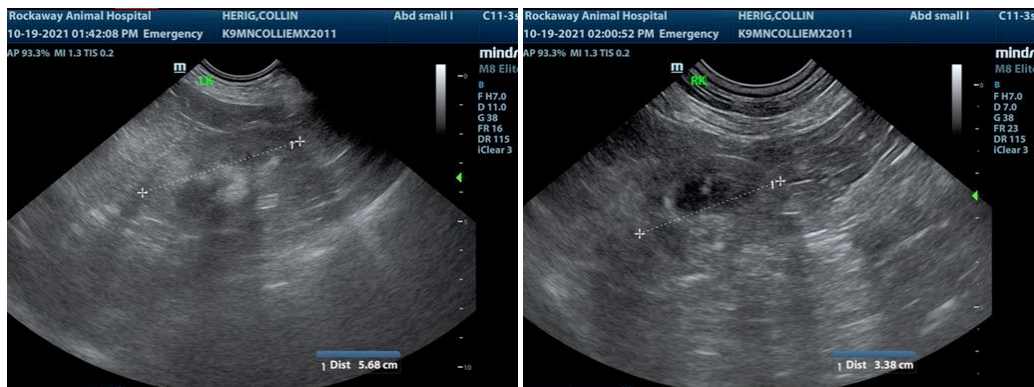
Chronic cystitis pattern.

INTERPRETATION OF THE FINDINGS & FURTHER RECOMMENDATIONS

Culture and sensitivity as well as long term antibiotics are recommended. Pulse antibiotics may be necessary in this patient. Ultrasound-guided traumatic catheterization is warranted to ensure that carcinoma is not playing a role in the polypoid changes.

Canine Chronic UTI Protocol

I recommend **Enrofloxacin** (5-10 mg/kg SID PO) (In patients > 1 year of age) in late pm after urination to maximize urinary concentrations overnight. This assumes that culture supports this use. Repeat **culture** at 3-4 weeks and continue treatment at least 7-10 days post negative urinary sediment and negative culture. *Note: Negative culture does not necessarily mean lack of UTI.* Other favorite antibiotics for chronic UTI include third generation Cefa (Ceftiafur or similar s.i.d. injectable) or Clavamox. If suspicion of occult urinary incontinence is present then **phenylpropanolamine (PPA)** (1-2 mg/kg BID) can be employed long term to enhance urethral tone.





PATIENT

Collin Herig

SPECIES

Canine

BREED

Collie Mix

SEX

Neutered male

AGE

10 years

WEIGHT

32.5 lbs

INTERPRETED BY

Eric Lindquist, DMV
DABVP, Cert. IVUSS

IMAGING PERFORMED BY

Jenn

HOSPITAL NAME

Rockaway AH

REFERRING VET

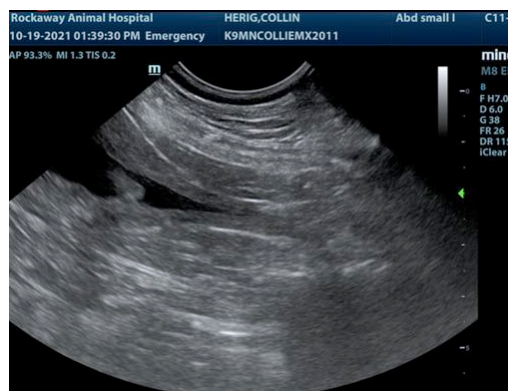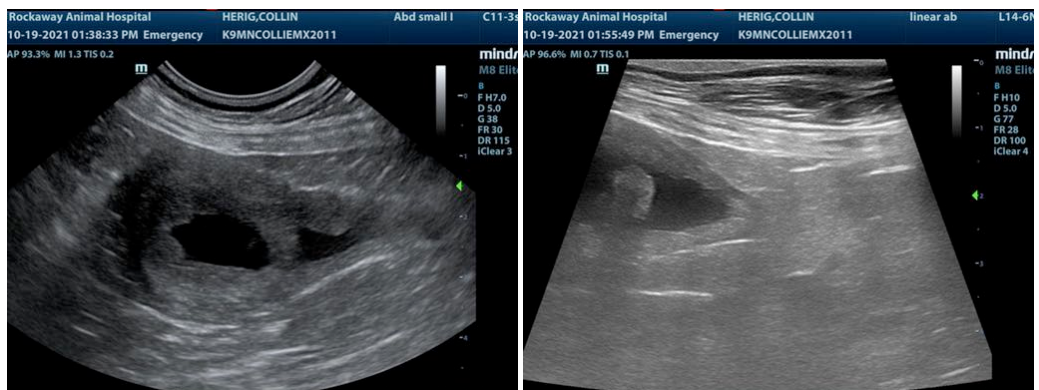
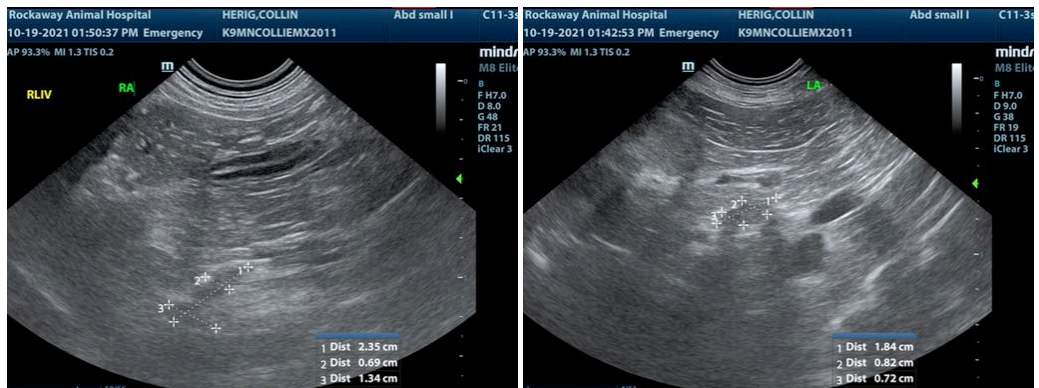
Dr. Maniar

INVOICE

92459

DATE

10/19/21



The information and recommendations provided are based on the images presented by the referring veterinarian. No evaluation can be communicated regarding pathology that was not visible in the image/video clips provided.

Thank you for this referral. If the clinical or image interpretation does not parallel your findings or if I can be of any further assistance please contact me.

Eric Lindquist, DMV, DABVP, Cert. IVUSS, CEO of SonoPath.com
info@SonoPath.com