



**PATIENT**

Bella Cicco

**SPECIES**

Feline

**BREED**

Maine Coon

**SEX**

Spayed Female

**AGE**

18 years

**WEIGHT**

13.6 lbs

**INTERPRETED BY**

Eric Lindquist, DMV  
DABVP, Cert. IVUSS

**IMAGING PERFORMED BY**

Kelly Vazquez, CVT

**HOSPITAL NAME**

Westwood Regional  
VH

**REFERRING VET**

Dr. Murphy

**INVOICE**

92464

**DATE**

10/19/21

**PRESENTING CLINICAL SIGNS**

History: Dyspnea. Episodes of open-mouth breathing with abdominal retractions. Current treatments: Convenia 10/16/21, one dose of Lasix 10/16/21. BUN 62, creat. 3.2, Na 168, cl 133, retics 76.1.

**ULTRASONOGRAPHIC EXAMINATION OF THE ABDOMEN**

**Urinary System**

The **urinary bladder**, trigone, and pelvic urethra presented normal thicknesses and normal tone. The ureters were not visible which is normal. No uroliths or sediment were visualized and anechoic urine was present. No evidence of inflammatory or neoplastic changes was noted. Ureteral papillae were normal.

The right kidney revealed pyelectasia and moderate chronic degenerative changes. Pericapsular inflammatory pattern with cortical infarcts were noted. The right kidney measured 3.63 cm. The left kidney measured 3.87 cm with pyelectasia and similar changes to the right kidney.

**Adrenal Glands**

The **adrenal glands** were uniform, yet bilaterally swollen and hypoechoic. This is most consistent with stress-induced hyperplasia. The left adrenal gland measured 0.31 cm with slight focal mineralization and age related change.

**Spleen**

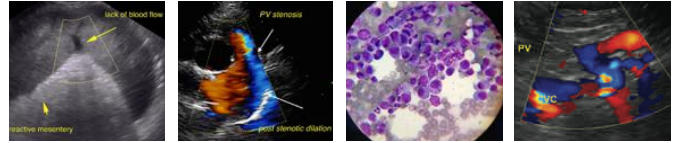
The **spleen** presented a smooth homogeneous parenchyma hyperechoic to liver and renal cortical parenchyma. The capsule was smooth without noticeable expansion or deviation from within the spleen or adjacent pathology. The splenic vasculature demonstrated normal volume without signs of congestion or thrombosis. No sonographic evidence of acute or chronic inflammatory, neoplastic, or infarctual changes was noted. The spleen measured 0.66 cm.

**Liver**

The **liver** images from right and left intercostal as well as subcostal views revealed subjectively normal liver size, contour, and structure. Some age-related parenchymal remodeling was noted but likely not clinically significant at this time. Vascular and biliary tracts were of normal volume and no evidence of congestion was noted. The gallbladder presented some dependent debris with essentially normal contour. The cystic and common bile ducts were normal. No overt evidence of active inflammatory, infiltrative or regenerative pathology was noted but should be paired with current or past LE elevations regarding any clinical significance to this presentation. The hepatic lymph nodes were unremarkable.

**Gastrointestinal**

Examination of the **gastrointestinal tract** revealed a stomach and intestine free of stasis, of normal wall thickness, acceptable curvilinear mural detail, and peristaltic activity. Small and large intestine



**PATIENT**

demonstrated normal luminal chyme and stool consistency respectively. No obstructive or overt infiltrative disease was noted. No associated abnormal lymphatic activity was noted.

Bella Cicco

**SPECIES**

**Pancreas**

Feline

The base and limbs of the **pancreas** were observed to be largely isoechoic to surrounding omental fat. Some parenchymal remodeling, however, with mild deviation from curvilinear normalcy was observed. Pancreatic duct and capsular irregularities were present consistent with age related changes. If pain upon imaging (+ Murphy sign) was present or if the patient is focally painful in subxiphoid palpation then low-grade smoldering chronic pancreatitis should be suspected.

**BREED**

Maine Coon

**SEX**

**ULTRASONOGRAPHIC EXAMINATION OF THE HEART**

Spayed Female

The thoracic presentation revealed a large amount of pleural effusion that does not appear to be cardiogenic in nature as the left atrial size is normal. There were areas of lung consolidation and an overt lung mass were noted in this patient. This is suspicious for thoracic neoplasia.

**AGE**

18 years

**WEIGHT**

13.6 lbs

**INTERPRETED BY**

Eric Lindquist, DMV  
DABVP, Cert. IVUSS

**IMAGING PERFORMED BY**

Kelly Vazquez, CVT

**HOSPITAL NAME**

Westwood Regional  
VH

**REFERRING VET**

Dr. Murphy

**INVOICE**

92464

**DATE**

10/19/21

FELINE CARDIAC PARAMETERS	BODY WEIGHT (kg)	HR (BPM)	IVSd (cm)	LVIDd (cm)	LVWd (cm)	FS (%)	EF (%)
NORMAL PARAMETER	-----	150-240	0.3-0.6	1.0-2.1	0.25-0.6	35-67	80-100
PATIENT		134	0.48	1.87	0.48	27	56
FELINE CARDIAC PARAMETERS	LA/AO (Boon)	LA/AO HEART BASE (Sisson)	LA 2D 4-chamber long axis AS to FW (Sisson) (cm)	LVOT VEL. (m/s)	RVOT VEL. (m/s)	IVRT (m/)	
NORMAL PARAMETER	<1.5	0.88-1.79	0.7-1.7	<1.6	<1.3	40-60	
PATIENT	1.3		1.4		0.55	NM	
Adapted from June Boon, Veterinary Echocardiography, 1998 Sisson D et al. JVIM 1991; 5: 232, Jacobs et al. Am J Vet Res 1985; 46:1705							

**ULTRASONOGRAPHIC FINDINGS**

Moderate degenerative renal changes with pyelectasia. Potential concurrent UTI.

Age related abdominal changes.

Lung mass suspicious for thoracic neoplasia. Pleural effusion.



**PATIENT**

Bella Cicco

**SPECIES**

Feline

**BREED**

Maine Coon

**SEX**

Spayed Female

**AGE**

18 years

**WEIGHT**

13.6 lbs

**INTERPRETED BY**

Eric Lindquist, DMV  
DABVP, Cert. IVUSS

**IMAGING PERFORMED BY**

Kelly Vazquez, CVT

**HOSPITAL NAME**

Westwood Regional  
VH

**REFERRING VET**

Dr. Murphy

**INVOICE**

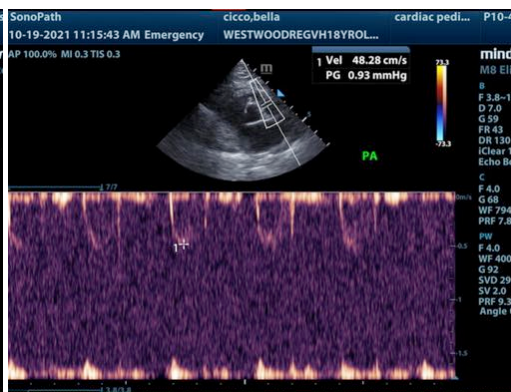
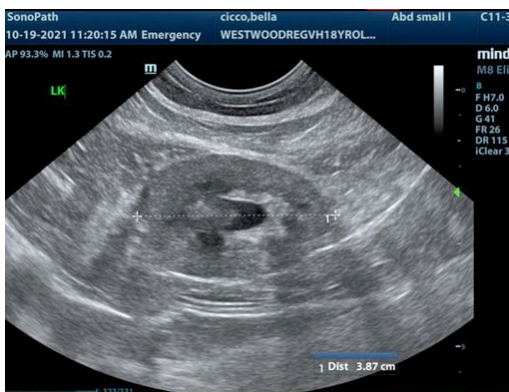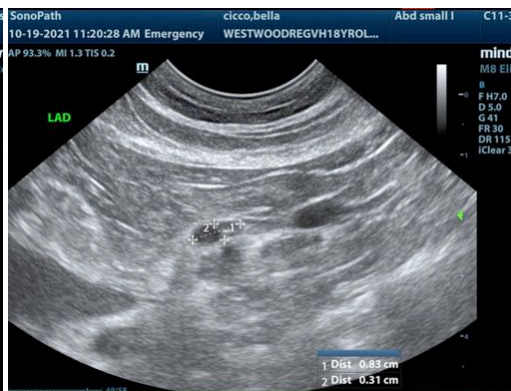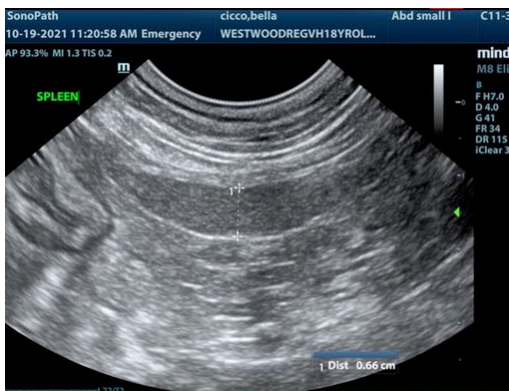
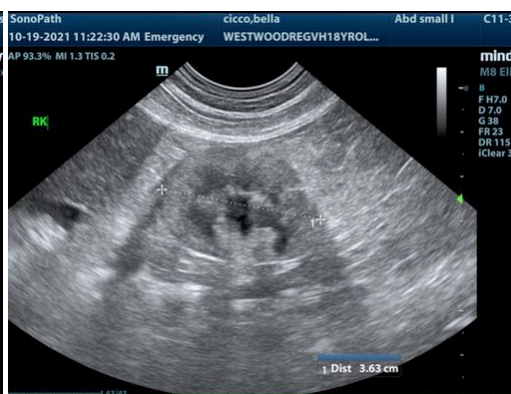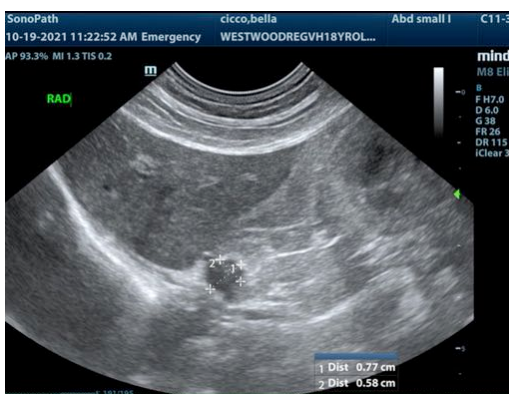92464

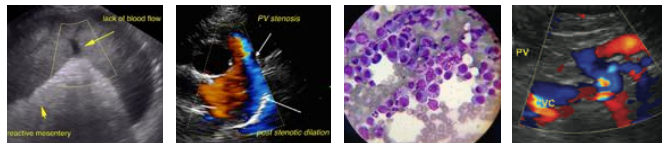
**DATE**

10/19/21

**INTERPRETATION OF THE FINDINGS & FURTHER RECOMMENDATIONS**

Pleurocentesis and cytospin of the thoracic fluid is recommended to assess for neoplastic cells. Low-dose Lasix can be considered from a palliative standpoint. However, the prognosis is poor. Humane euthanasia should be considered in this patient.





**PATIENT**

Bella Cicco

**SPECIES**

Feline

**BREED**

Maine Coon

**SEX**

Spayed Female

**AGE**

18 years

**WEIGHT**

13.6 lbs

**INTERPRETED BY**

Eric Lindquist, DMV  
DABVP, Cert. IVUSS

**IMAGING PERFORMED BY**

Kelly Vazquez, CVT

**HOSPITAL NAME**

Westwood Regional  
VH

**REFERRING VET**

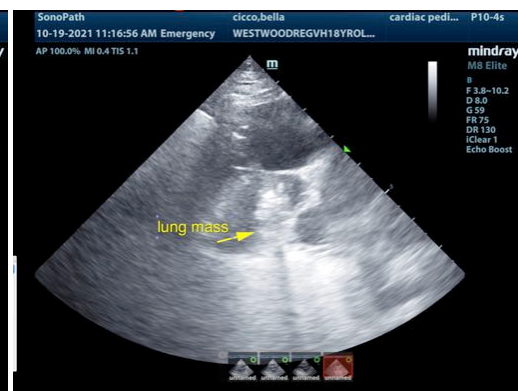
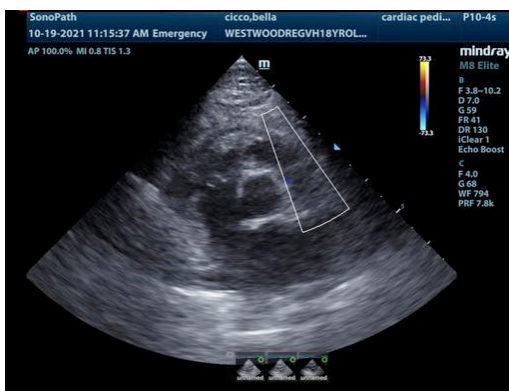
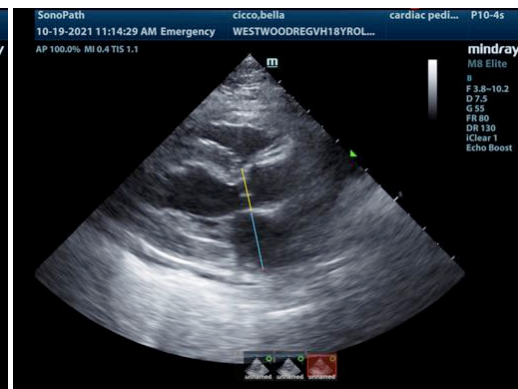
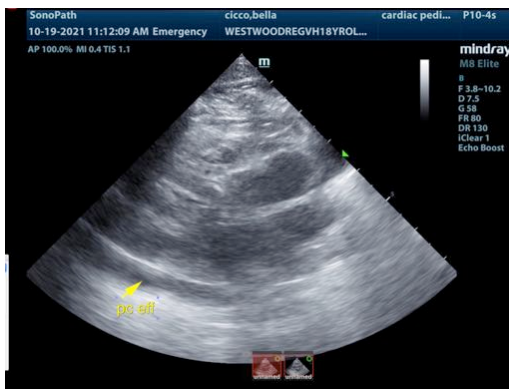
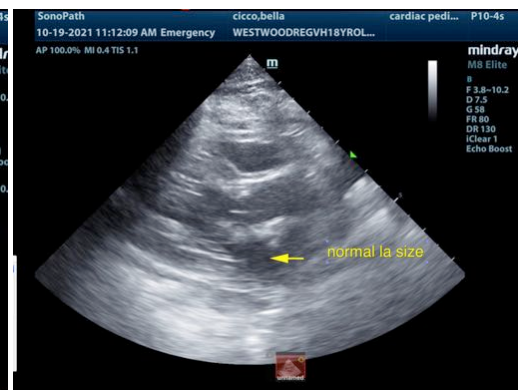
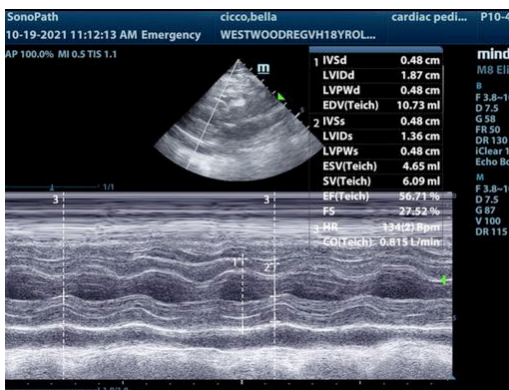
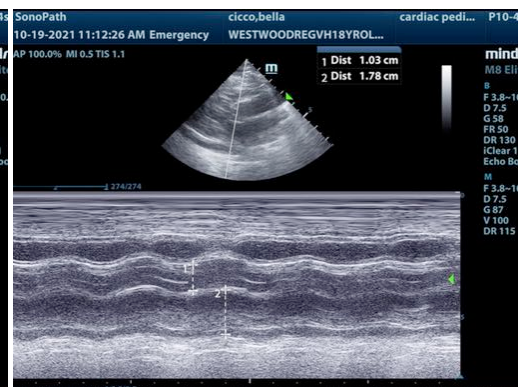
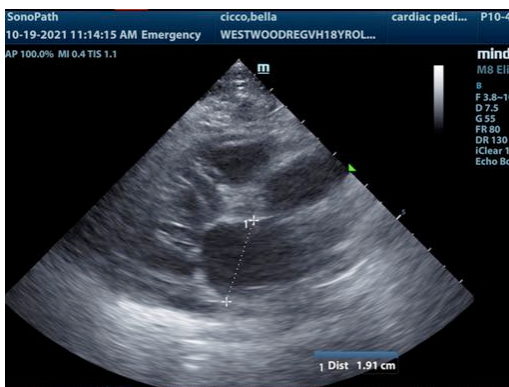Dr. Murphy

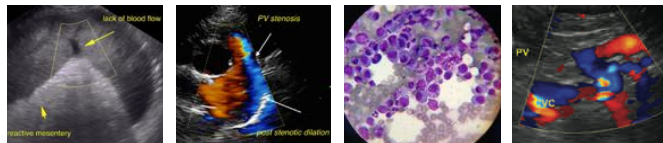
**INVOICE**

92464

**DATE**

10/19/21





**PATIENT**

Bella Cicco

The information and recommendations provided are based on the images presented by the referring veterinarian. No evaluation can be communicated regarding pathology that was not visible in the image/video clips provided.

**SPECIES**

Feline

Thank you for this referral. If the clinical or image interpretation does not parallel your findings or if I can be of any further assistance please contact me.

**Eric Lindquist, DMV, DABVP, Cert. IVUSS, CEO of SonoPath.com**  
info@SonoPath.com

**BREED**

Maine Coon

**SEX**

Spayed Female

**AGE**

18 years

**WEIGHT**

13.6 lbs

**INTERPRETED BY**

Eric Lindquist, DMV  
DABVP, Cert. IVUSS

**IMAGING  
PERFORMED BY**

Kelly Vazquez, CVT

**HOSPITAL NAME**

Westwood Regional  
VH

**REFERRING VET**

Dr. Murphy

**INVOICE**

92464

**DATE**

10/19/21