



**PATIENT PRESENTING CLINICAL SIGNS**

Bailey Horowitz

History: Thick pasty debris in bladder; repeated UTIs; previous echo follow up (Prev. echo 1/27/21).  
Current meds: Clavamox.

**SPECIES**

Abnormal PE/Chem/CBC/UA Results: RBC 5.08, HCT 36.9, HGB 12.9, glucose 41. U/A: UPC 0.3, BP 180 mm/Hg.

Canine

**BREED**

Cavapoo

**SEX**

Neutered male

**AGE**

13 years

**WEIGHT**

8.3 lbs

**ULTRASONOGRAPHIC EXAMINATION OF THE ABDOMEN**

**Urinary System**

The **urinary bladder**, trigone, and pelvic urethra presented normal thicknesses and normal tone. The ureters were not visible which is normal. No uroliths or sediment were visualized and anechoic urine was present. No evidence of inflammatory or neoplastic changes was noted. Ureteral papillae were normal.

The residual prostate was uniform and measured 0.59 cm.

The **kidneys** revealed largely normal size and structure, corticomedullary definition and ratio (cortex 1/3 of medulla) were essentially maintained with some age-related loss of curvilinear patterns regarding the capsule and C/M junction. The cortices presented largely uniform texture with some increased echogenicity expected for this age patient. Medullary structure differed distinctly from that of the cortex and no evidence of pelvic dilation was present. Mineralization was noted in the kidneys. The right kidney measured 3.66 cm. The left kidney measured 3.7 cm.

**INTERPRETED BY**

Eric Lindquist, DMV  
DABVP, Cert. IVUSS

**Adrenal Glands**

Both **adrenal glands** were visualized and recognized as having normal shape, size, position and echogenicity for this breed. The phrenic vasculature, glandular echogenicity and detail were unremarkable. Capsule, cortex, and medullary definition were normal for this age patient. The right adrenal gland measured 1.37 x 0.46 cm at the caudal pole and 0.72 cm at the cranial pole. The left adrenal gland measured 1.45 x 0.44 cm at the caudal pole and 0.46 cm at the cranial pole.

**IMAGING PERFORMED BY**

Kelly Vazquez, CVT

**Spleen**

**HOSPITAL NAME**

Cresskill AH

The **spleen** presented a smooth homogeneous parenchyma hyperechoic to liver and renal cortical parenchyma. The capsule was smooth without noticeable expansion or deviation from within the spleen or adjacent pathology. The splenic vasculature demonstrated normal volume without signs of congestion or thrombosis. No sonographic evidence of acute or chronic inflammatory, neoplastic, or infarctual changes was noted.

**REFERRING VET**

Dr. Micale

**INVOICE**

92460

**Liver**

The **liver** images from right and left intercostal as well as subcostal views revealed subjectively normal liver size, contour, and structure. Some age-related parenchymal remodeling was noted but likely not clinically significant at this time. Vascular and biliary tracts were of normal volume and no evidence of congestion was noted. The gallbladder presented some dependent debris with essentially normal contour. The cystic and common bile ducts were normal. No overt evidence of active inflammatory,

**DATE**

10/19/21



**PATIENT**

infiltrative or regenerative pathology was noted but should be paired with current or past LE elevations regarding any clinical significance to this presentation. The hepatic lymph nodes were unremarkable.

Bailey Horowitz

**SPECIES**

**Gastrointestinal**

Canine

Examination of the **gastrointestinal tract** revealed a stomach and intestine free of stasis, of normal wall thickness, acceptable curvilinear mural detail, and peristaltic activity. Small and large intestine demonstrated normal luminal chyme and stool consistency respectively. No obstructive or overt infiltrative disease was noted. No associated abnormal lymphatic activity was noted.

**BREED**

Cavapoo

**Pancreas**

**SEX**

The base and limbs of the **pancreas** were observed to be largely isoechoic to surrounding omental fat. Pancreatic duct and capsular contour were acceptably normal and parenchyma respected normal curvilinear patterns. No overt evidence of active inflammatory or neoplastic disease was noted.

Neutered male

**AGE**

13 years

**ULTRASONOGRAPHIC FINDINGS**

Structurally unremarkable abdomen.

**WEIGHT**

8.3 lbs

Largely geriatric abdominal changes with renal mineralization, non-obstructive.

**INTERPRETED BY**

**INTERPRETATION OF THE FINDINGS & FURTHER RECOMMENDATIONS**

Eric Lindquist, DMV  
DABVP, Cert. IVUSS

There was no evidence of significant pathology. The patient may be passing calculi periodically contributing to the clinical signs.

**IMAGING PERFORMED BY**

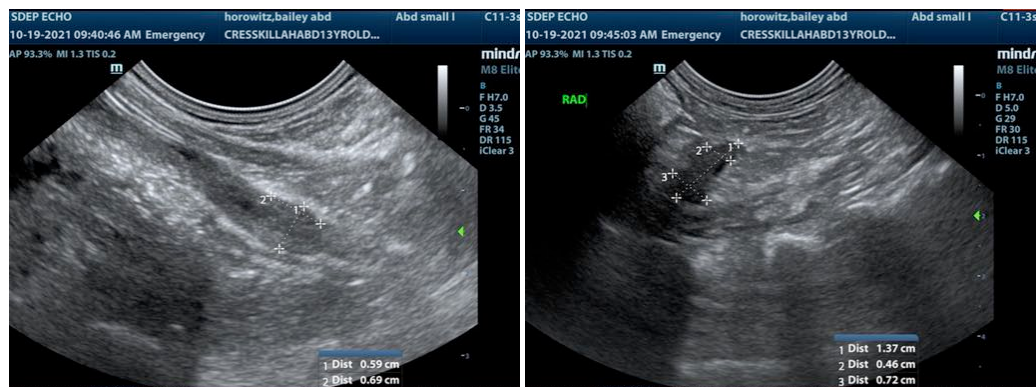
Kelly Vazquez, CVT

**HOSPITAL NAME**

Cresskill AH

**REFERRING VET**

Dr. Micale



**INVOICE**

92460

**DATE**

10/19/21



**PATIENT**

Bailey Horowitz

**SPECIES**

Canine

**BREED**

Cavapoo

**SEX**

Neutered male

**AGE**

13 years

**WEIGHT**

8.3 lbs

**INTERPRETED BY**

Eric Lindquist, DMV  
DABVP, Cert. IVUSS

**IMAGING PERFORMED BY**

Kelly Vazquez, CVT

**HOSPITAL NAME**

Cresskill AH

**REFERRING VET**

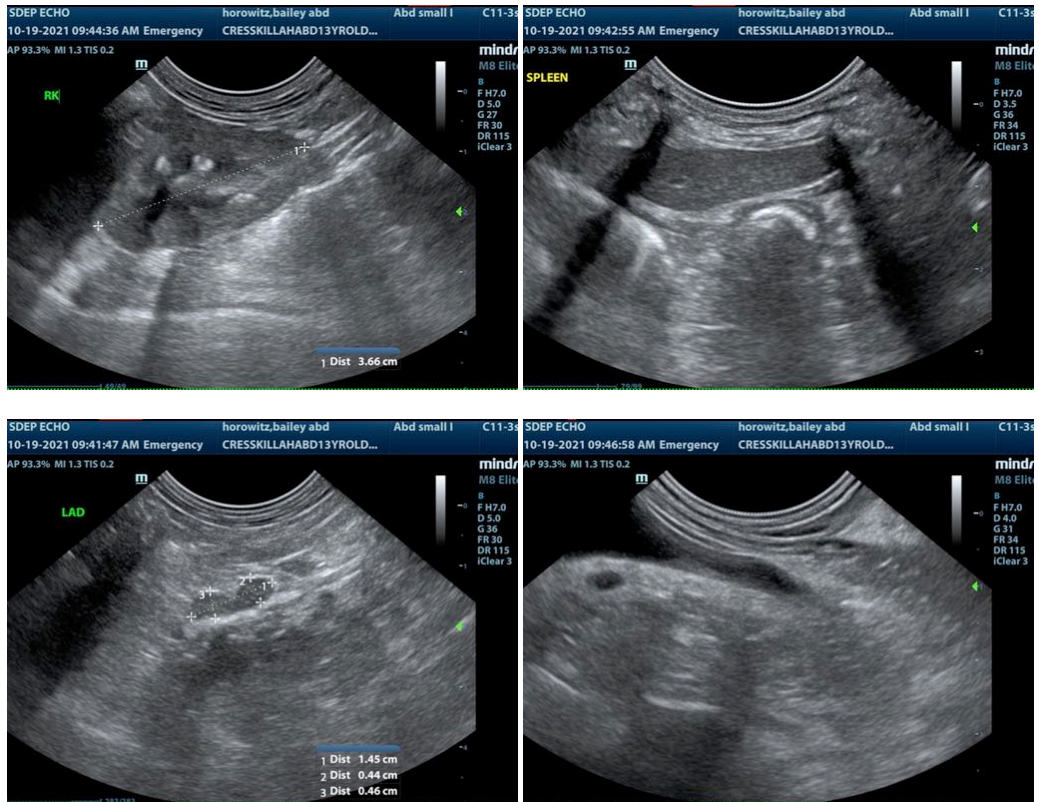
Dr. Micale

**INVOICE**

92460

**DATE**

10/19/21



The information and recommendations provided are based on the images presented by the referring veterinarian. No evaluation can be communicated regarding pathology that was not visible in the image/video clips provided.

Thank you for this referral. If the clinical or image interpretation does not parallel your findings or if I can be of any further assistance please contact me.

Eric Lindquist, DMV, DABVP, Cert. IVUSS, CEO of SonoPath.com  
info@SonoPath.com