



## PATIENT

Carmella Wanna

## PRESENTING CLINICAL SIGNS

History: lethargic, heavy breathing, fluid in lungs

## SPECIES

Feline

## ULTRASONOGRAPHIC EXAMINATION OF THE HEART & ABDOMEN

## BREED

DSH

## SEX

Spayed Female

## AGE

2 Years

## WEIGHT

5.6 Pounds

FELINE CARDIAC PARAMETERS	BODY WEIGHT (kg)	HR (BPM)	IVSd (cm)	LVIDd (cm)	LVWd (cm)	FS (%)	EF (%)
<b>NORMAL PARAMETER</b>	-----	150-240	0.3-0.6	1.0-2.1	0.25-0.6	35-67	80-100
<b>PATIENT</b>	--	NM	--	--	--	--	--
FELINE CARDIAC PARAMETERS	LA/AO (Boon)	LA/AO HEART BASE (Sisson)	LA 2D 4-chamber long axis AS to FW (Sisson) (cm)	LVOT VEL. (m/s)	RVOT VEL. (m/s)	IVRT (m/)	
<b>NORMAL PARAMETER</b>	<1.5	0.88-1.79	0.7-1.7	<1.6	<1.3	40-60	
<b>PATIENT</b>	1.15	1.27	--	--	.93	NM	

Adapted from June Boon, Veterinary Echocardiography, 1998  
Sisson D et al. JVIM 1991; 5: 232, Jacobs et al. Am J Vet Res 1985; 46:1705

### Cardiac Presentation

The echocardiogram in this patient demonstrated normal **left atrial** size based on 3 separate LA measurements. The cranial and caudal **mitral** valve leaflets presented normal linear structure and kinetics. The **left ventricle** presented normal thicknesses with linear contour and was not dilated nor restricted. The **myocardium** presented normal echogenicity without subjective evidence of significant fibrotic or ischemic disease. **Contractility** of the ventricular walls was adequate and in normal range for this patient evidenced by the fractional shortening measurement and subjective evaluation of the different regions and angles of the myocardium. The **left ventricular outflow** tract demonstrated normal laminar flow and subjective structural integrity. The **right atrium** and auricle revealed normal size, structure and content. No evidence of masses was noted or chamber overload. **Tricuspid** valvular assessment demonstrated adequate linear morphology and kinetics. The **right ventricle** was of normal size (1/3 diameter of LV), chordae structure, myocardial echogenicity and thickness. **Pulmonic** tract assessment revealed normal valve structure, laminar flow, and diameter (approx. 1:1 pa/ao ratio).

### Urinary System

The **urinary bladder**, trigone, and pelvic urethra presented normal thicknesses and normal tone. The ureters were not visible which is normal. No uroliths or sediment were visualized and anechoic urine was present. No evidence of inflammatory or neoplastic changes were noted. Ureteral papillae were normal.

The **kidneys** revealed normal size and structure, corticomedullary definition and ratio for this age. The cortices presented largely uniform texture with normal echogenic relationship to liver and spleen. Medullary structure differed distinctly from the cortex and no evidence of pelvic dilation was present.

## INTERPRETED BY

Eric Lindquist, DMV  
DABVP, Cert. IVUSS

## IMAGING PERFORMED BY

Jenn

## HOSPITAL NAME

Rockaway AH

## REFERRING VET

Dr. Maniar

## INVOICE

17814

## DATE

10/18/22



**PATIENT**

Carmella Wanna

The capsules were acceptably uniform without significant irregularities. The left kidney measured 4.09 cm. The right kidney measured 3.77 cm.

**Adrenal Glands**

**SPECIES**

Feline

The regions of the **adrenal glands** revealed no evident pathology.

**Spleen**

**BREED**

DSH

The **spleen** presented a smooth homogeneous parenchyma hyperechoic to liver and renal cortical parenchyma. The capsule was smooth without noticeable expansion or deviation from within the spleen or adjacent pathology. The splenic vasculature demonstrated normal volume without signs of congestion or thrombosis. No sonographic evidence of acute or chronic inflammatory, neoplastic, or infarctual changes were noted.

**SEX**

Spayed Female

**Liver**

The **liver** revealed slight increased portal markings. The gallbladder was echogenic.

**AGE**

2 Years

**Gastrointestinal**

Examination of the **gastrointestinal tract** revealed a stomach and intestine free of stasis, of normal wall thickness, acceptable curvilinear mural detail, and peristaltic activity. Small and large intestine demonstrated normal luminal chyme and stool consistency respectively. No obstructive or overt infiltrative disease was noted. No associated abnormal lymphatic activity was noted.

**WEIGHT**

5.6 Pounds

**Pancreas**

The base and limbs of the **pancreas** were observed to be largely isoechoic to surrounding omental fat. Pancreatic duct and capsular contour were acceptably normal and parenchyma respected normal curvilinear patterns. No overt evidence of active inflammatory or neoplastic disease was noted.

**INTERPRETED BY**

Eric Lindquist, DMV  
DABVP, Cert. IVUSS

**Other**

**IMAGING PERFORMED BY**

Jenn

The **chest** in the patient revealed tissue density occupation in the caudal and right thorax. No free fluid was noted at the time of the sonogram. Direct diaphragmatic hernia could not be ascertained, however, the diaphragm itself appeared somewhat nebulous in the cranial abdomen. I recommend chest and abdominal CT for further definition.

**HOSPITAL NAME**

Rockaway AH

**ULTRASONOGRAPHIC FINDINGS**

**REFERRING VET**

Dr. Maniar

- Suspect diaphragmatic hernia
- Normal echocardiogram
- Slight increased portal markings in the liver
- Echogenic gallbladder

**INTERPRETATION OF THE FINDINGS & FURTHER RECOMMENDATIONS**

**INVOICE**

17814

Chest radiographs are warranted for further definition +/- FNA of the tissue density in the chest. No evidence of cardiac disease.

**DATE**

10/18/22

**SonoPath CT Services** are offered at the [Blairstown Animal Hospital](#). Blairstown animal hospital is just a 30-minute drive west on route 80 from the route 80/287 interchange/Parsippany, New Jersey. More information can be found at:



**PATIENT**

Carmella Wanna

<https://sonopath.com/resources/sonopaths-teleconsultation-services-and-sdep-certification/sonopath-ct-services>

**SPECIES**

Feline

**BREED**

DSH

**SEX**

Spayed Female

**AGE**

2 Years

**WEIGHT**

5.6 Pounds

**INTERPRETED BY**

Eric Lindquist, DMV  
DABVP, Cert. IVUSS

**IMAGING PERFORMED BY**

Jenn

**HOSPITAL NAME**

Rockaway AH

**REFERRING VET**

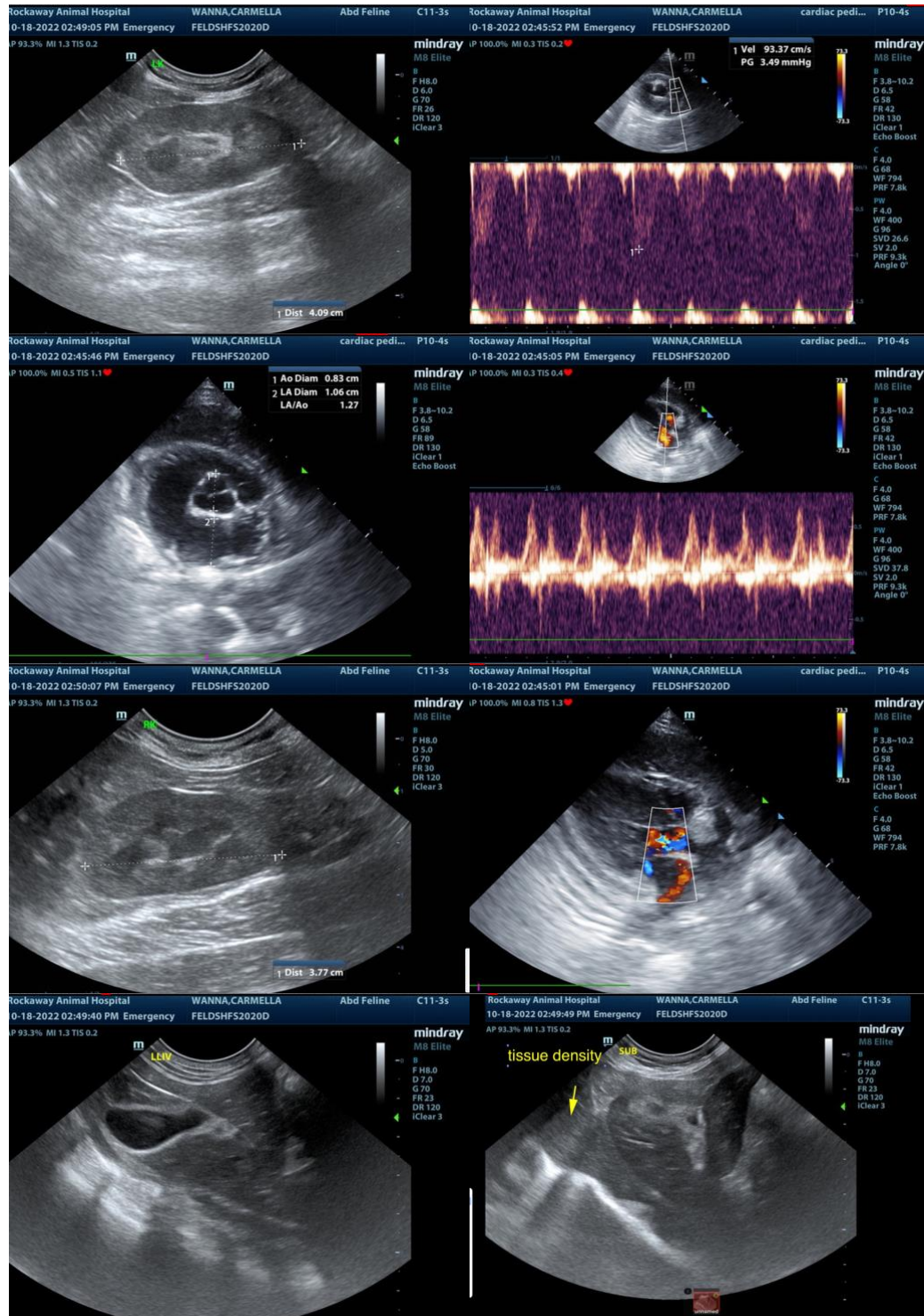
Dr. Maniar

**INVOICE**

17814

**DATE**

10/18/22





**PATIENT**

Carmella Wanna

**The information and recommendations provided are based on the images presented by the referring veterinarian. No evaluation can be communicated regarding pathology that was not visible in the image/video clips provided.**

**SPECIES**

Feline

Thank you for this referral. If the clinical or image interpretation does not parallel your findings or if I can be of any further assistance please contact me.

**BREED**

DSH

**Eric Lindquist**, DMV, DABVP, Cert. IVUSS, CEO of SonoPath.com  
info@SonoPath.com

**SEX**

Spayed Female

**AGE**

2 Years

**WEIGHT**

5.6 Pounds

**INTERPRETED BY**

Eric Lindquist, DMV  
DABVP, Cert. IVUSS

**IMAGING  
PERFORMED BY**

Jenn

**HOSPITAL NAME**

Rockaway AH

**REFERRING VET**

Dr. Maniar

**INVOICE**

17814

**DATE**

10/18/22