



PATIENT PRESENTING CLINICAL SIGNS

Katy Speight History: Grade 3/5 murmur. Pet has seizures
 Abnormal PE/Chem/CBC/UA Results: BP 141/92(107),156/67(96),125/77(105)

SPECIES

Canine

ULTRASONOGRAPHIC EXAMINATION OF THE HEART

BREED

Shih Tzu

The echocardiogram in this patient demonstrated normal **left atrial** size based on 3 different LA measurement methods. Chamber volumes and echogenicity were normal. The cranial and caudal **mitral** valve leaflets presented vegetative thickening consistent with endocardiosis. Prolapse of the anterior mitral valve leaflet was noted. Doppler indicated measurable insufficiency. The **left ventricle** presented thicknesses with linear contour and was not dilated nor restricted. The **myocardium** presented normal echogenicity without subjective evidence of significant fibrotic or ischemic disease. **Contractility** of the ventricular walls was adequate and in normal range for this patient evidenced by the fractional shortening measurement and subjective evaluation of the different regions of the myocardium. The **left ventricular outflow** tract demonstrated normal laminar flow and subjective structural integrity. The **right atrium** and auricle revealed normal size, structure and content. No evidence of masses was noted or chamber overload. Minor **tricuspid** insufficiency was noted. The **right ventricle** was of normal size (1/3 diameter of LV), chordae structure, myocardial echogenicity and thickness. **Pulmonic** tract assessment revealed normal valve structure, laminar flow, and diameter (approx.1:1 pa/ao ratio). No visible **pericardial** or free pleura fluid was noted. No echographically detectable evidence of infiltrative disease was visible. The cranial **mediastinum and pericardial regions** were free of masses in the visible window.

SEX

Spayed Female

AGE

12 Pounds

WEIGHT

14.5 Years

INTERPRETED BY

Eric Lindquist, DMV
 DABVP, Cert. IVUSS

IMAGING PERFORMED BY

JK

HOSPITAL NAME

Hamburg VC

REFERRING VET

Dr. Martens

CANINE CARDIAC PARAMETERS	MR VMAX (m/s)	TR VMAX (m/s)	LA/AO (Boon method)	LA/AO (Heart Base; Swe)	FS (%)	EF (%)	EPSS (cm)
NORMAL PARAMETER	4.5-5.5	<2.7	1.3	<1.6	28-40	40-100	<0.6
PATIENT	5.0	2.0	1.3	1.5	53	86	0.2
CANINE CARDIAC PARAMETERS	HR (BPM)	AV VMAX (m/s)	PV MAX (m/s)	BODY WEIGHT	LA (2D short axis Base view)	LVIDd (Avg; 2D and m-mode short axis)	LVIDs (Avg; 2D and m-mode short axis)
NORMAL PARAMETER	50-100	0.7-1.7	0.7-1.6		(cm)	(cm)	(cm)
PATIENT	144	1.2	0.9	12 lbs	2.7	2.41	

INVOICE

ULTRASONOGRAPHIC FINDINGS

- Stage B1 valvular disease.

DATE

10/18/21



PATIENT

Katy Speight

SPECIES

Canine

BREED

Shih Tzu

SEX

Spayed Female

AGE

12 Pounds

WEIGHT

14.5 Years

INTERPRETED BY

Eric Lindquist, DMV
DABVP, Cert. IVUS

IMAGING PERFORMED BY

JK

HOSPITAL NAME

Hamburg VC

REFERRING VET

Dr. Martens

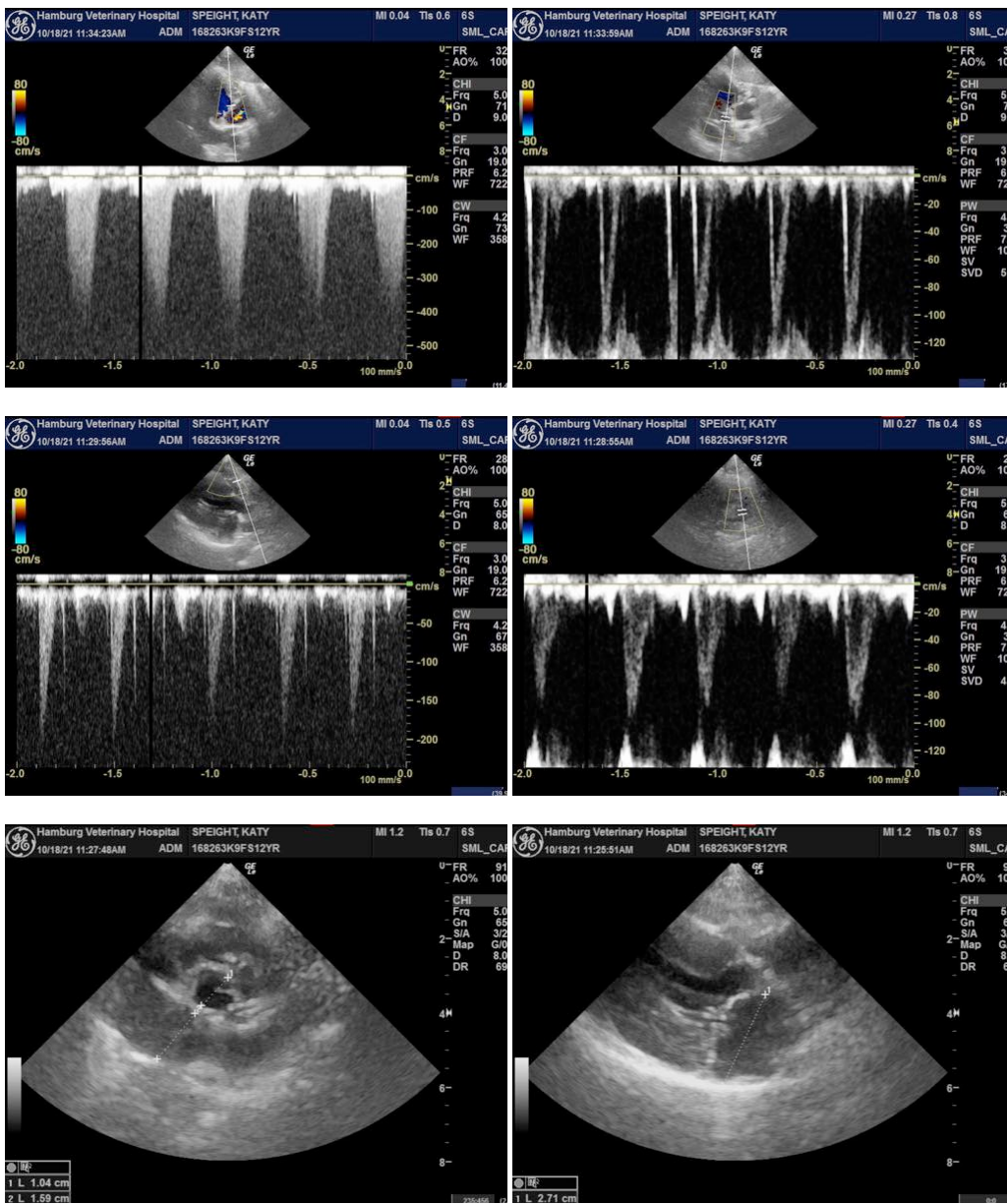
INVOICE

DATE

10/18/21

INTERPRETATION OF THE FINDINGS & FURTHER RECOMMENDATIONS

No therapy is recommended at this time. If anesthesia is necessary, there is no overt contraindication to an anesthetic procedure. Suggested protocol includes Torbutrol premed, Propofol induction, and Isoflurane maintenance. Recheck echocardiogram in 6 months or earlier if murmur grade increases or clinical signs initiate.





PATIENT

Katy Speight

SPECIES

Canine

BREED

Shih Tzu

SEX

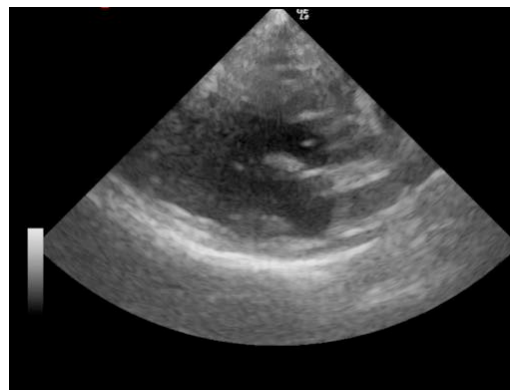
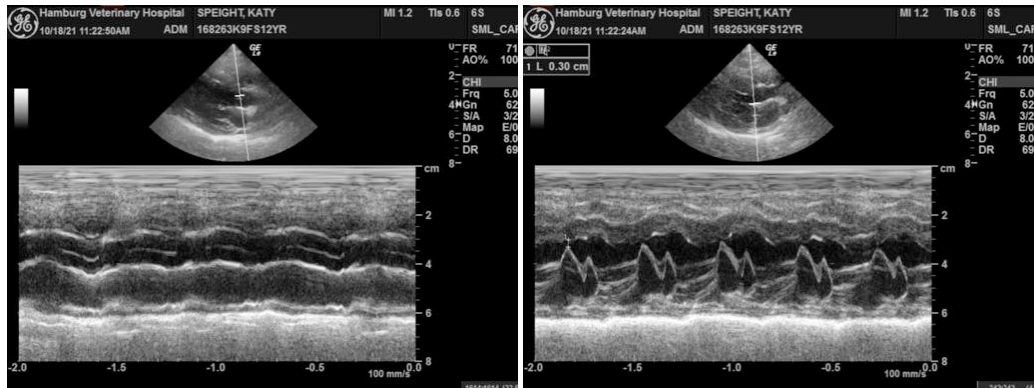
Spayed Female

AGE

12 Pounds

WEIGHT

14.5 Years



INTERPRETED BY

Eric Lindquist, DMV
DABVP, Cert. IVUSS

IMAGING PERFORMED BY

JK

HOSPITAL NAME

Hamburg VC

REFERRING VET

Dr. Martens

INVOICE

DATE

10/18/21

The information and recommendations provided are based on the images presented by the referring veterinarian. No evaluation can be communicated regarding pathology that was not visible in the image/video clips provided.

Thank you for this referral. If the clinical or image interpretation does not parallel your findings or if I can be of any further assistance please contact me.

Eric Lindquist, DMV, DABVP, Cert. IVUSS, CEO of SonoPath.com
info@SonoPath.com