


PATIENT

Rush Bleiler

SPECIES

Canine

BREED

Australian Shepherd

SEX

Neutered male

AGE

8 years

WEIGHT

44 lbs

INTERPRETED BY

 Eric Lindquist, DMV
 DABVP, Cert. IVUSS

IMAGING PERFORMED BY

Dr. Wallisch

HOSPITAL NAME

 Sondel Family
 Veterinary Clinic

REFERRING VET

Dr. Wallisch

INVOICE

40103

DATE

10/17/22

PRESENTING CLINICAL SIGNS

History: Recheck echo. Last echo sent to Sonopath 1/3/22. Stable, some coughing, no new heart symptoms. Doing well overall. O wanting to make sure no major changes. Current meds: Pimo 5mg, one tablet BID; Benazepril 5mg, 1.5 tablets BID. Left sided heart murmur 3/6.
 Abnormal PE/Chem/CBC/UA Results: None

ULTRASONOGRAPHIC EXAMINATION OF THE HEART

The echocardiogram in this patient revealed mitral insufficiency. The left ventricular and left atrial volume was normal. There was no evidence of volume overload at this point. Mitral insufficiency velocity is fairly excessive and centralized to slightly eccentric jet noted on color flow assessment. Aortic outflow was normal with mildly excessive velocity. The right atrium, right ventricle and pulmonary outflow was all normal. This is consistent with stage B1 valvular disease.

CANINE CARDIAC PARAMETERS	MR VMAX (m/s)	TR VMAX (m/s)	LA/AO (Boon method)	LA/AO (Heart Base; Swe)	FS (%)	EF (%)	EPSS (cm)
NORMAL PARAMETER	4.5-5.5	<2.7	1.3	<1.6	28-40	40-100	<0.6
PATIENT	6.0		1.15	1.25	45		0.2
CANINE CARDIAC PARAMETERS	HR (BPM)	AV VMAX (m/s)	PV MAX (m/s)	BODY WEIGHT	LA (2D short axis Base view) (cm)	LVIDd (Avg; 2D and m-mode short axis) (cm)	LVIDs (Avg; 2D and m-mode short axis) (cm)
NORMAL PARAMETER	50-100	0.7-1.7	0.7-1.6	BELOW	BELOW	BELOW	BELOW
PATIENT		1.9	1.0	44 lbs	3.8 max	4.3	

ULTRASONOGRAPHIC FINDINGS

Stable Stage 1 valvular disease.

INTERPRETATION OF THE FINDINGS & FURTHER RECOMMENDATIONS

No treatment is recommended at this time. Blood pressure measurements are recommended. Pericardial and pleural spaces were unremarkable.



PATIENT

Rush Bleiler

SPECIES

Canine

BREED

Australian Shepherd

SEX

Neutered male

AGE

8 years

WEIGHT

44 lbs

INTERPRETED BY

Eric Lindquist, DMV
DABVP, Cert. IVUSS

IMAGING PERFORMED BY

Dr. Wallisch

HOSPITAL NAME

Sondel Family
Veterinary Clinic

REFERRING VET

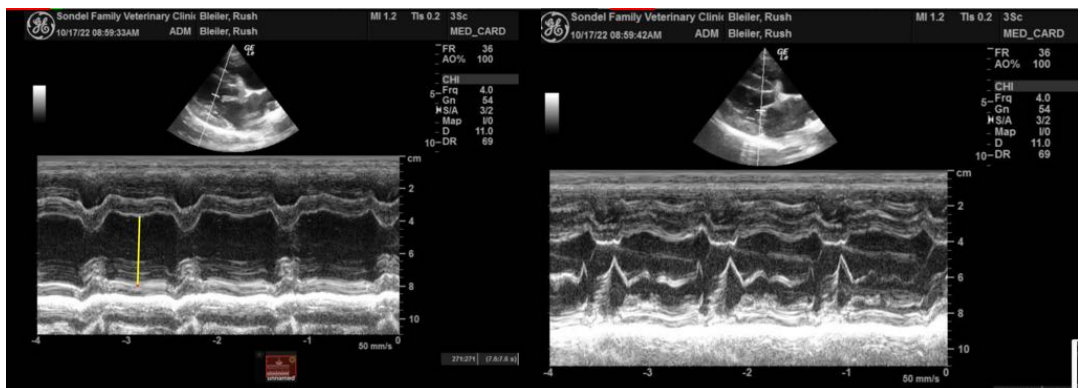
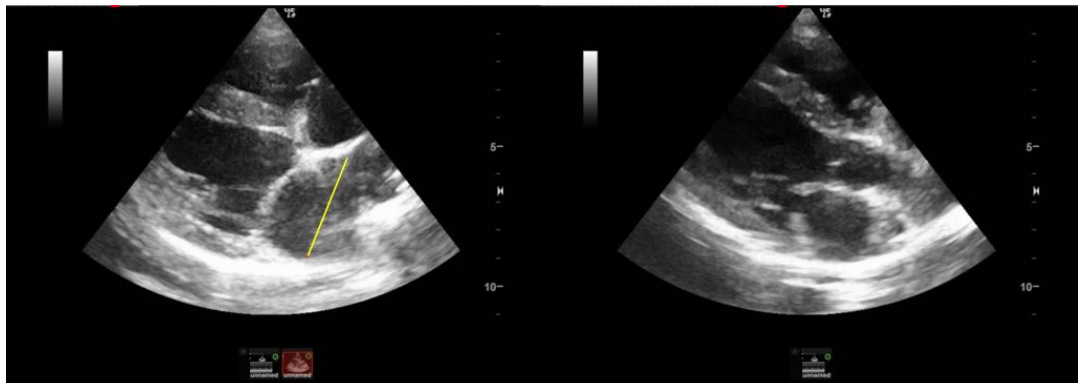
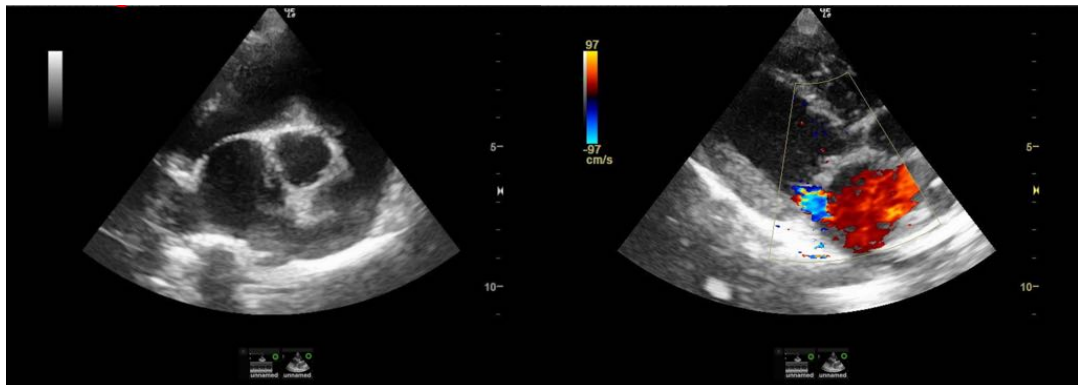
Dr. Wallisch

INVOICE

40103

DATE

10/17/22





PATIENT

Rush Bleiler

SPECIES

Canine

BREED

Australian Shepherd

SEX

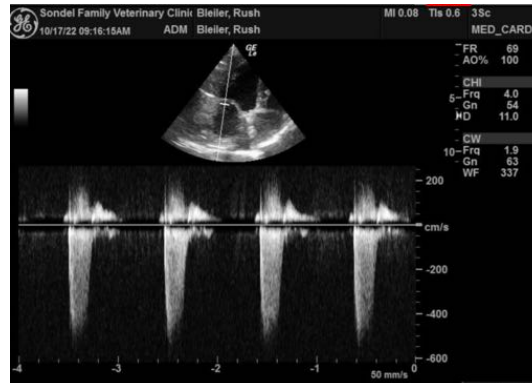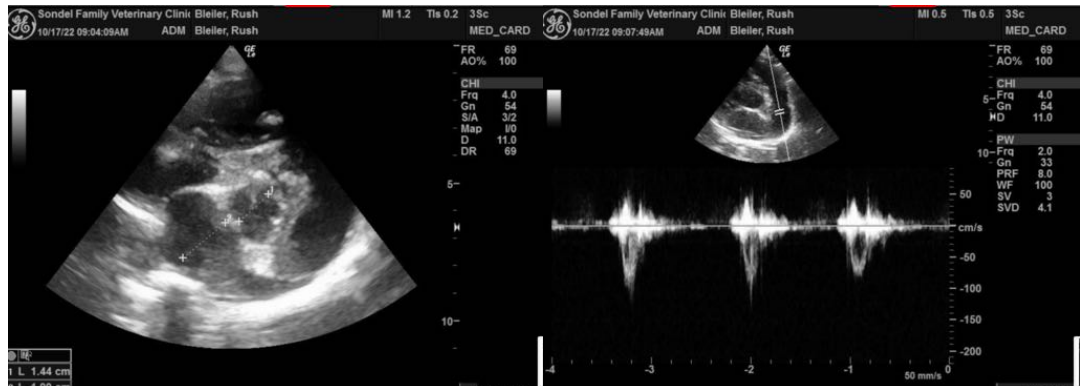
Neutered male

AGE

8 years

WEIGHT

44 lbs



INTERPRETED BY

Eric Lindquist, DMV
DABVP, Cert. IVUSS

IMAGING PERFORMED BY

Dr. Wallisch

HOSPITAL NAME

Sondel Family
Veterinary Clinic

REFERRING VET

Dr. Wallisch

INVOICE

40103

DATE

10/17/22

The information and recommendations provided are based on the images presented by the referring veterinarian/sonographer. No evaluation can be communicated regarding pathology that was not visible in the image/video clips provided.

Thank you for this referral. If the clinical or image interpretation does not parallel your findings or if I can be of any further assistance please contact me.

Eric Lindquist, DMV, DABVP, Cert. IVUSS, CEO of SonoPath.com
info@SonoPath.com