



## PATIENT

Mojo Al Thani

## SPECIES

Feline

## BREED

Maine Coon

## SEX

Neutered Male

## AGE

14 Years

## WEIGHT

4.3 kg

## INTERPRETED BY

Eric Lindquist, DMV  
DABVP, Cert. IVUSS

## IMAGING PERFORMED BY

Dr. Samad Khan

## HOSPITAL NAME

The Veterinary Surgery

## REFERRING VET

Dr. Samad Khan

## INVOICE

17750

## DATE

10/17/22

## PRESENTING CLINICAL SIGNS

History: Black spot on the neck ulcerated ,no masses or enlarged lymph nodes are obvious. histo BOWENOID IN SITU CARCINOMA WITH MALIGNANT TRANSFORMATIONS PAPILLOMA VIRUS INFECTION Intestine impacted with hard faeces. Heart and lung sound clear. Concerned about the diet(on tuna only\_as can cause taurine deficiency can cause cardiac issue. double cavity to assess metasatsiis and anesathe risk

Abnormal PE/Chem/CBC/UA Results: Blood work unremarkable

## ULTRASONOGRAPHIC EXAMINATION OF THE HEART & ABDOMEN

FELINE CARDIAC PARAMETERS	BODY WEIGHT (kg)	HR (BPM)	IVSd (cm)	LVIDd (cm)	LVWd (cm)	FS (%)	EF (%)
NORMAL PARAMETER	-----	150-240	0.3-0.6	1.0-2.1	0.25-0.6	35-67	80-100
PATIENT	--	NM	0.36	1.6	0.42	50	90
FELINE CARDIAC PARAMETERS	LA/AO (Boon)	LA/AO HEART BASE (Sisson)	LA 2D 4-chamber long axis AS to FW (Sisson) (cm)	LVOT VEL. (m/s)	RVOT VEL. (m/s)	IVRT (m/)	
NORMAL PARAMETER	<1.5	0.88-1.79	0.7-1.7	<1.6	<1.3	40-60	
PATIENT	1.15		1.43				NM
Adapted from June Boon, Veterinary Echocardiography, 1998							
Sisson D et al. JVIM 1991; 5: 232, Jacobs et al. Am J Vet Res 1985; 46:1705							

## Cardiac Presentation

The echocardiogram in this patient demonstrated normal **left atrial** size based on 3 separate LA measurements. The cranial and caudal **mitral** valve leaflets presented normal linear structure and kinetics. The **left ventricle** presented normal thicknesses with linear contour and was not dilated nor restricted. The **myocardium** presented normal echogenicity without subjective evidence of significant fibrotic or ischemic disease. **Contractility** of the ventricular walls was adequate and in normal range for this patient evidenced by the fractional shortening measurement and subjective evaluation of the different regions and angles of the myocardium. The **left ventricular outflow** tract demonstrated normal laminar flow and subjective structural integrity. The **right atrium** and auricle revealed normal size, structure and content. No evidence of masses was noted or chamber overload. **Tricuspid** valvular assessment demonstrated adequate linear morphology and kinetics. The **right ventricle** was of normal size (1/3 diameter of LV), chordae structure, myocardial echogenicity and thickness. **Pulmonic** tract assessment revealed normal valve structure, laminar flow, and diameter (approx.1:1 pa/ao ratio). No visible **pericardial** or free pleura fluid was noted or extra cardiac pathology in the visible planes. The cranial **mediastinum and pericardial regions** were free of masses in the visible window.

## Urinary System



**PATIENT**

Mojo Al Thani

The **urinary bladder**, trigone, and pelvic urethra presented normal thicknesses and normal tone. The ureters were not visible which is normal. No uroliths or sediment were visualized, and anechoic urine was present. No evidence of inflammatory or neoplastic changes were noted. Ureteral papillae were normal. The pelvic urethra was imaged 3.0 cm beyond the cystourethral junction.

**SPECIES**

Feline

The **kidneys** revealed normal size and structure, corticomedullary definition and ratio for this age. The cortices presented largely uniform texture with normal echogenic relationship to liver and spleen. Medullary structure differed distinctly from the cortex and no evidence of pelvic dilation was present. The capsules were acceptably uniform without significant irregularities. The right kidney measured 3.9 cm. The left kidney measured 3.9 cm.

**BREED**

Maine Coon

**Adrenal Glands**

The regions of the **adrenal glands** revealed no evident pathology.

**SEX**

Neutered Male

**Spleen**

The **spleen** presented a smooth homogeneous parenchyma hyperechoic to liver and renal cortical parenchyma. The capsule was smooth without noticeable expansion or deviation from within the spleen or adjacent pathology. The splenic vasculature demonstrated normal volume without signs of congestion or thrombosis. No sonographic evidence of acute or chronic inflammatory, neoplastic, or infarctual changes were noted.

**AGE**

14 Years

**WEIGHT**

4.3 kg

**Liver**

The **liver** images submitted revealed subjectively normal liver size, contour, and structure. Parenchymal echogenicity was naturally coarse and hypoechoic to the spleen. Vascular and biliary tracts were of normal volume with no evidence of congestion. The gallbladder presented acceptably thin walls with primarily anechoic content. The cystic and common bile ducts were normal. No pathological hepatic lymphadenopathy was evident. No overt structural evidence of inflammatory, infiltrative or regenerative pathology was evident.

**INTERPRETED BY**

Eric Lindquist, DMV  
DABVP, Cert. IVUSS

**Gastrointestinal**

Minor retention of ingesta noted in the **stomach**. The small intestine and colon were unremarkable.

**IMAGING PERFORMED BY**

Dr. Samad Khan

**Pancreas**

The base and limbs of the **pancreas** were observed to be largely isoechoic to surrounding omental fat. Pancreatic duct and capsular contour were acceptably normal and parenchyma respected normal curvilinear patterns. No overt evidence of active inflammatory or neoplastic disease was noted.

**HOSPITAL NAME**

The Veterinary Surgery

**Free Abdomen**

A mid abdominal **mass** was noted in this patient, measuring 3.3 cm x 2.77 cm. The mass was just cranial to the urinary bladder and appeared to deviate the descending colon. This is likely of lymph node or intestinal origin. It presented irregular contour.

**REFERRING VET**

Dr. Samad Khan

**INVOICE**

17750

**ULTRASONOGRAPHIC FINDINGS**

- Normal feline cardiac
- Undifferentiated mid caudal abdominal mass, suspect intestinal or lymph node origin
- Stomach ingesta
- Unremarkable abdomen otherwise

**DATE**

10/17/22



**PATIENT**

Mojo Al Thani

**INTERPRETATION OF THE FINDINGS & FURTHER RECOMMENDATIONS**

FNA of the mass is indicated. Prognosis is guarded.

**SPECIES**

Feline

**BREED**

Maine Coon

**SEX**

Neutered Male

**AGE**

14 Years

**WEIGHT**

4.3 kg

**INTERPRETED BY**

Eric Lindquist, DMV  
DABVP, Cert. IVUSS

**IMAGING PERFORMED BY**

Dr. Samad Khan

**HOSPITAL NAME**

The Veterinary Surgery

**REFERRING VET**

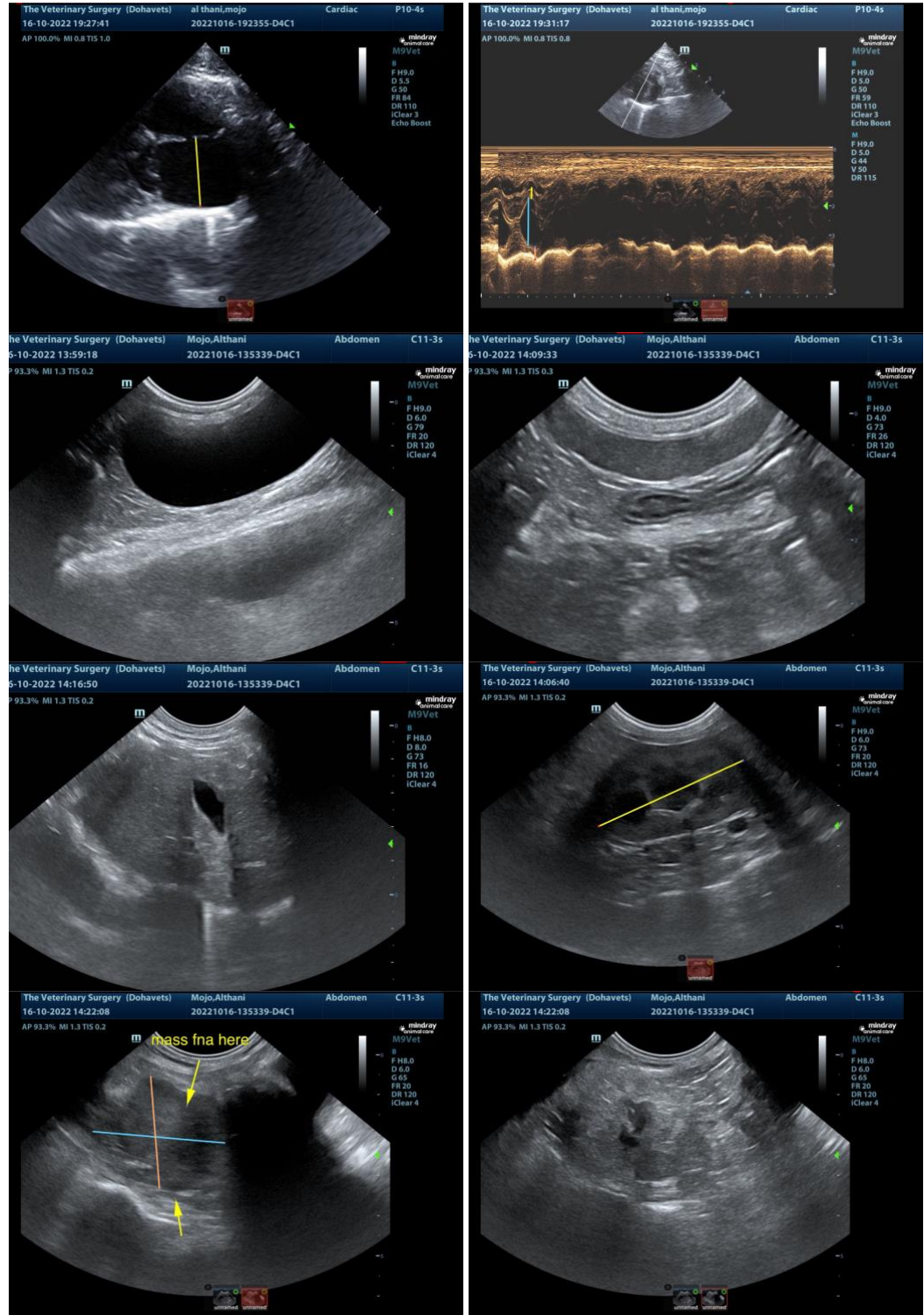
Dr. Samad Khan

**INVOICE**

17750

**DATE**

10/17/22





**PATIENT**

Mojo Al Thani

The information and recommendations provided are based on the images presented by the referring veterinarian. No evaluation can be communicated regarding pathology that was not visible in the image/video clips provided.

**SPECIES**

Feline

Thank you for this referral. If the clinical or image interpretation does not parallel your findings or if I can be of any further assistance please contact me.

**BREED**

Maine Coon

**Eric Lindquist**, DMV, DABVP, Cert. IVUSS, CEO of SonoPath.com  
info@SonoPath.com

**SEX**

Neutered Male

**AGE**

14 Years

**WEIGHT**

4.3 kg

**INTERPRETED BY**

Eric Lindquist, DMV  
DABVP, Cert. IVUSS

**IMAGING PERFORMED BY**

Dr. Samad Khan

**HOSPITAL NAME**

The Veterinary Surgery

**REFERRING VET**

Dr. Samad Khan

**INVOICE**

17750

**DATE**

10/17/22