



PATIENT

Daisy Miranda

PRESENTING CLINICAL SIGNS

History: Routine Bloodwork showed hematuria
Abnormal PE/Chem/CBC/UA Results: USG: 1.044, RBC 11-20 HPF, WBC 2-3 HPF, No bacteria seen

SPECIES

Canine

ULTRASONOGRAPHIC EXAMINATION OF THE ABDOMEN

Urinary System

BREED

French Bulldog

The **urinary bladder** revealed minor apical wall thickening with slight polypoid changes. The pelvic urethra was imaged 3.0 cm beyond the cystourethral junction and appeared normal.

SEX

Spayed female

The **kidneys** revealed normal size and structure, corticomedullary definition and ratio for this age. The cortices presented largely uniform texture with normal echogenic relationship to liver and spleen. Medullary structure differed distinctly from the cortex and no evidence of pelvic dilation was present. The capsules were acceptably uniform without significant irregularities. The left kidney measured 5.0 cm with slight, non-obstructive, pinpoint mineralization. The right kidney measured 5.17 cm.

AGE

12 years

ULTRASONOGRAPHIC FINDINGS

WEIGHT

25 lbs

Minor cystitis bladder pattern.
Minor renal mineralization.

INTERPRETED BY

Eric Lindquist, DMV
DABVP, Cert. IVUSS

INTERPRETATION OF THE FINDINGS & FURTHER RECOMMENDATIONS

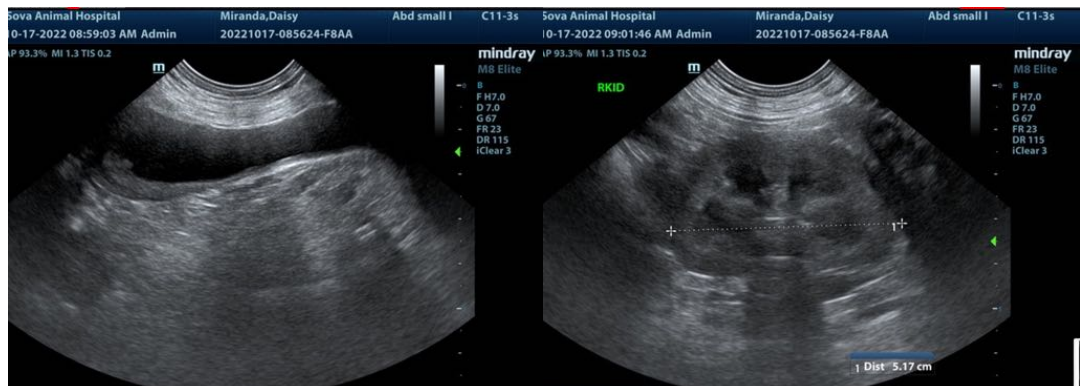
Urine culture and empirical treatment with Enrofloxacin over a 10-14 day period can be considered. The patient may be passing small calculi periodically, yet no obstructive disease was noted at this time.

IMAGING PERFORMED BY

Dr. Ammeraal

HOSPITAL NAME

Sova



REFERRING VET

Dr. Ammeraal

INVOICE

40094

DATE

10/17/22



PATIENT

Daisy Miranda

SPECIES

Canine

BREED

French Bulldog

SEX

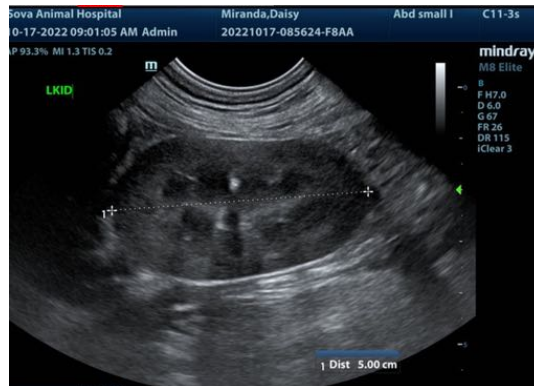Spayed female

AGE

12 years

WEIGHT

25 lbs



The information and recommendations provided are based on the images presented by the referring veterinarian/sonographer. No evaluation can be communicated regarding pathology that was not visible in the image/video clips provided.

Thank you for this referral. If the clinical or image interpretation does not parallel your findings or if I can be of any further assistance please contact me.

Eric Lindquist, DMV, DABVP, Cert. IVUSS, CEO of SonoPath.com
info@SonoPath.com

INTERPRETED BY

Eric Lindquist, DMV
DABVP, Cert. IVUSS

IMAGING PERFORMED BY

Dr. Ammeraal

HOSPITAL NAME

Sova

REFERRING VET

Dr. Ammeraal

INVOICE

40094

DATE

10/17/22