



PATIENT

Chloe Schramm

SPECIES

Feline

BREED

Domestic Shorthair

SEX

Spayed female

AGE

14 years

WEIGHT

14.68 lbs

INTERPRETED BY

Eric Lindquist, DMV
DABVP, Cert. IVUSS

IMAGING PERFORMED BY

Dr. Striano Kaplan

HOSPITAL NAME

Ramsey VH

REFERRING VET

Dr. Striano Kaplan

INVOICE

40102

DATE

10/17/22

PRESENTING CLINICAL SIGNS

History: weight loss, vomiting on and off x1 month increased over the past 3-4 days pet vomiting at least 1x daily, decreased appetite x1 month, pu/pd x1-2 months. Multifocal pulmonary nodules noted on AIS radiology report - primary differential is metastatic neoplasia. Recently diagnosed hyperthyroid. Abnormal PE/Chem/CBC/UA Results: Free T4 (ng/dL): 4.1H, Free T4 (pmol/L): 52.8H, Creatinine: 0.8L, BUN: 14L, TCO2: 24H, Cholesterol: 72L, MCV: 38L, MCH: 12.1L, Retic HGB: 14.1L, Lymphocyte: 494L UPC Ratio: 0.5

ULTRASONOGRAPHIC EXAMINATION OF THE ABDOMEN

Urinary System

The **urinary bladder** cystourethral junction and caudal ventral wall revealed slight polypoid changes that measured up to 0.5 cm at the cystourethral junction and 0.3 cm at the ventral bladder wall.

The **kidneys** revealed largely normal size and structure, corticomedullary definition and ratio (cortex 1/3 of medulla) were essentially maintained with some age-related loss of curvilinear patterns regarding the capsule and C/M junction. The cortices presented largely uniform texture with some increased echogenicity expected for his age patient. Medullary structure differed distinctly from that of the cortex and no evidence of pelvic dilation was present. The right kidney measured 4.18 cm with a cortical infarct at the caudal pole. The left kidney measured 4.16 cm.

Adrenal Glands

Both **adrenal glands** were visualized and recognized as having normal shape, size, position and echogenicity for this breed. The phrenic vasculature, glandular echogenicity and detail were unremarkable. Capsule, cortex, and medullary definition were normal for this age patient.

Spleen

The **spleen** revealed a subtle micronodular pattern.

Liver

The **liver** images submitted revealed subjectively normal liver size, contour, and structure. Parenchymal echogenicity was naturally coarse and hypoechoic to the spleen. Vascular and biliary tracts were of normal volume with no evidence of congestion. The gallbladder presented acceptably thin walls with primarily anechoic content. The cystic and common bile ducts were normal. No pathological hepatic lymphadenopathy was evident. No overt structural evidence of inflammatory, infiltrative or regenerative pathology was evident.

Gastrointestinal

Examination of the **gastrointestinal tract** revealed a stomach and intestine free of stasis, of normal wall thickness, acceptable curvilinear mural detail, and peristaltic activity. Small and large intestine



PATIENT

Chloe Schramm

demonstrated normal luminal chyme and stool consistency respectively. A separate 3.0 x 2.6 cm mixed hypoechoic mass was noted cranial to the urinary bladder. This appeared to be colonic or ileocecal. The mesenteric root revealed multiple, irregular, undifferentiated, hypoechoic tissue structures. These are likely lymph node in origin and are non-resectable. Reactive, irregular mesentery was noted.

SPECIES

Feline

Pancreas

The base and limbs of the **pancreas** were observed to be largely isoechoic to surrounding omental fat. Pancreatic duct and capsular contour were acceptably normal and parenchyma respected normal curvilinear patterns. No overt evidence of active inflammatory or neoplastic disease was noted.

BREED

Domestic Shorthair

SEX

Spayed female

Free Abdomen

A 5.2 x 5.0 cm lipomatous type mass was noted and appeared to be deriving from the midabdomen.

AGE

14 years

ULTRASONOGRAPHIC FINDINGS

Bladder differentials include polypoid hyperplasia versus carcinoma.

Intestinal mass.

WEIGHT

14.68 lbs

Abdominal lipoma, subjectively benign.

Multi-focal lymphadenopathy.

INTERPRETED BY

Eric Lindquist, DMV
DABVP, Cert. IVUSS

Splenic nodular changes.

Age related renal changes with minor infarcts in the right kidney.

IMAGING PERFORMED BY

Dr. Striano Kaplan

INTERPRETATION OF THE FINDINGS & FURTHER RECOMMENDATIONS

Ultrasound-guided FNA is recommended of the intestinal mass, spleen and lymph nodes are recommended. Carcinoma versus lymphomatosis or similar is suspected. The prognosis is guarded to poor. Granulomatous and non-neoplastic disease is possible, yet less likely.

HOSPITAL NAME

Ramsey VH

REFERRING VET

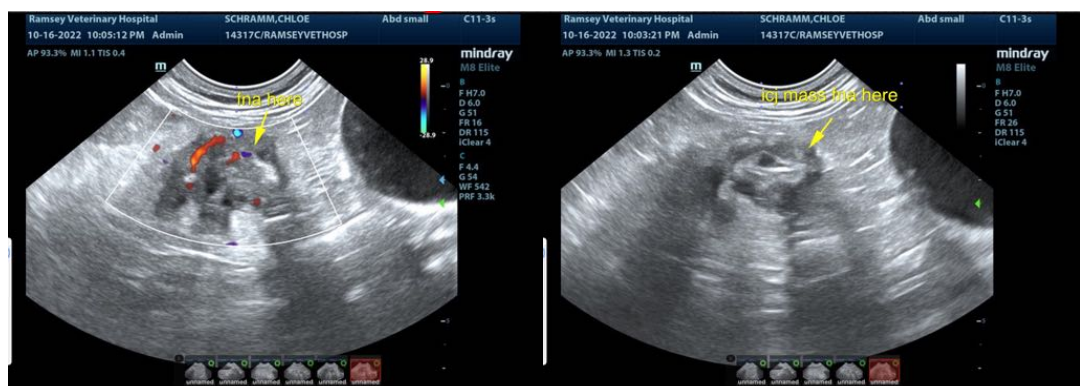
Dr. Striano Kaplan

INVOICE

40102

DATE

10/17/22





PATIENT

Chloe Schramm

SPECIES

Feline

BREED

Domestic Shorthair

SEX

Spayed female

AGE

14 years

WEIGHT

14.68 lbs

INTERPRETED BY

Eric Lindquist, DMV
DABVP, Cert. IVUSS

IMAGING PERFORMED BY

Dr. Striano Kaplan

HOSPITAL NAME

Ramsey VH

REFERRING VET

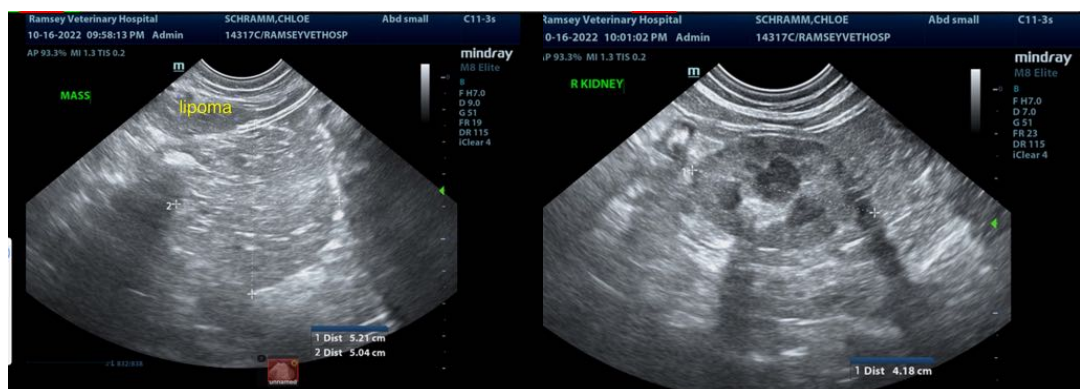
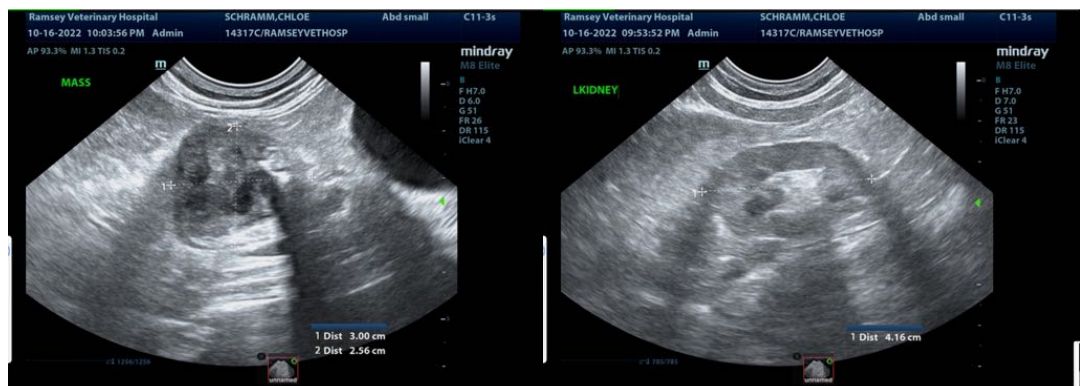
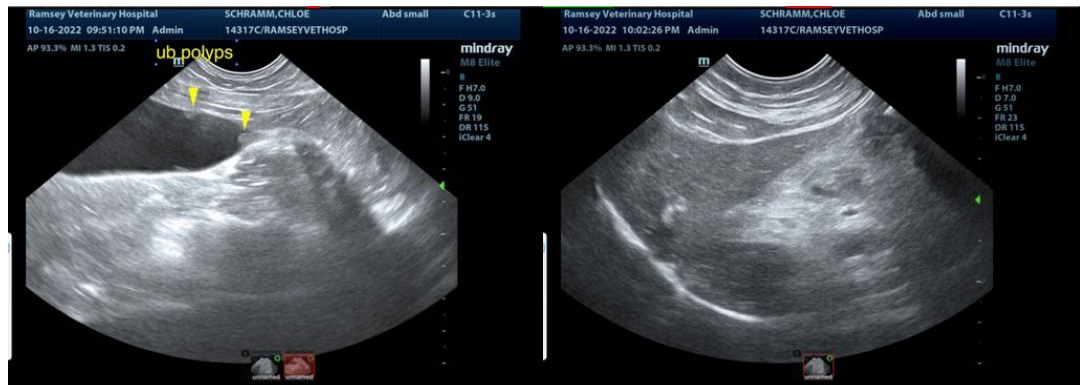
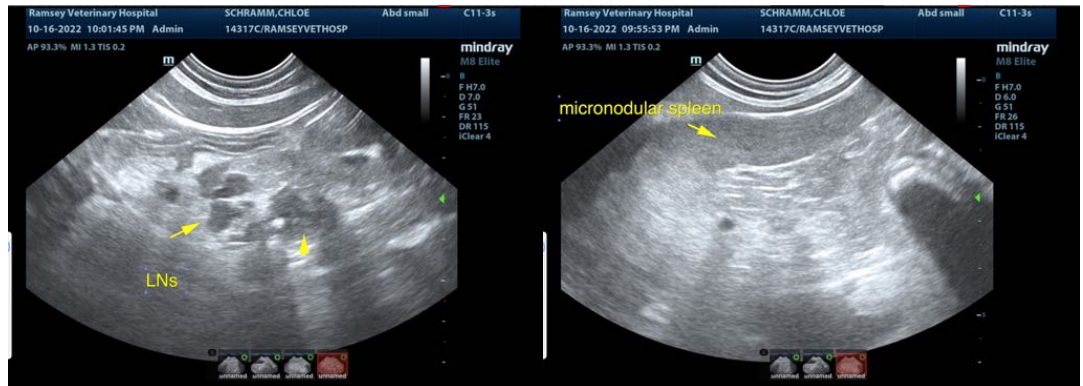
Dr. Striano Kaplan

INVOICE

40102

DATE

10/17/22





PATIENT

Chloe Schramm

The information and recommendations provided are based on the images presented by the referring veterinarian/sonographer. No evaluation can be communicated regarding pathology that was not visible in the image/video clips provided.

SPECIES

Feline

Thank you for this referral. If the clinical or image interpretation does not parallel your findings or if I can be of any further assistance please contact me.

BREED

Domestic Shorthair

Eric Lindquist, DMV, DABVP, Cert. IVUSS, CEO of SonoPath.com
info@SonoPath.com

SEX

Spayed female

AGE

14 years

WEIGHT

14.68 lbs

INTERPRETED BY

Eric Lindquist, DMV
DABVP, Cert. IVUSS

**IMAGING
PERFORMED BY**

Dr. Striano Kaplan

HOSPITAL NAME

Ramsey VH

REFERRING VET

Dr. Striano Kaplan

INVOICE

40102

DATE

10/17/22