



**PATIENT**

Abby Nibling

**SPECIES**

Feline

**BREED**

Mixed

**SEX**

Spayed Female

**AGE**

12 Years

**WEIGHT**

7 Pounds

**INTERPRETED BY**

Eric Lindquist, DMV  
DABVP, Cert. IVUSS

**IMAGING  
PERFORMED BY**

Byron Cabrera

**HOSPITAL NAME**

All Creatures Great &  
Small, Denville

**REFERRING VET**

Ilija Mitrovic

**INVOICE**

17778

**DATE**

10/17/22

**PRESENTING CLINICAL SIGNS**

History: History of Emesis for couples months, Good body condition even losing weight

Abnormal PE/Chem/CBC/UA Results: bloodwork normal

**ULTRASONOGRAPHIC EXAMINATION OF THE ABDOMEN**

**Urinary System**

The **urinary bladder**, trigone, and pelvic urethra presented normal thicknesses and normal tone. The ureters were not visible which is normal. No uroliths or sediment were visualized, and anechoic urine was present. No evidence of inflammatory or neoplastic changes were noted. Ureteral papillae were normal. The pelvic urethra was imaged 1.0 cm beyond the cystourethral junction.

The **left kidney** revealed mild generalized enlargement and an interstitial nephrosis pattern with loss of structural detail. The left kidney measured 4.1 cm.

The **right kidney** revealed similar changes to the left. The right kidney measured 4.5 cm.

**Adrenal Glands**

The **adrenal glands** were uniform, yet bilaterally swollen and hypoechoic. This is most consistent with stress-induced hyperplasia.

**Spleen**

The **spleen** revealed slight irregular contour with focal out pocketing. The spleen measured 9.0 mm.

**Liver**

The **liver** revealed generalized enlargement with swollen irregular contour and increased portal markings. The gallbladder wall was slightly echogenic. The hepatic lymph nodes were mildly enlarged and slightly rounded, measuring up to 1.0 cm.

**Gastrointestinal**

Some retention of chyme was noted in the **stomach**. The gastric wall was unremarkable. Curvilinear patterns were maintained. The pylorus was free of evident pathology. The intestinal tract revealed chronic thickening of the submucosal layer. Some nebulous mucosal changes were noted in the small intestine.

**Pancreas**

The base and limbs of the **pancreas** were observed to be largely isoechoic to surrounding omental fat. Some mild parenchymal remodeling, however, with mild deviation from curvilinear normalcy was observed. Pancreatic duct and capsular irregularities were present consistent with age related changes. If pain upon imaging (+ Murphy sign) was present or if the patient is focally painful in subxyphoid palpation then low-grade smoldering chronic pancreatitis should be suspected.

**Free Abdomen**

A mesenteric **lymph node** mass was noted. The largest lymph node measured up to 2.0 cm, a grouping of which measured approximately 4.0 cm.



**PATIENT**

Abby Nibling

**SPECIES**

Feline

**BREED**

Mixed

**SEX**

Spayed Female

**AGE**

12 Years

**WEIGHT**

7 Pounds

**INTERPRETED BY**

Eric Lindquist, DMV  
DABVP, Cert. IVUSS

**IMAGING PERFORMED BY**

Byron Cabrera

**HOSPITAL NAME**

All Creatures Great &  
Small, Denville

**REFERRING VET**

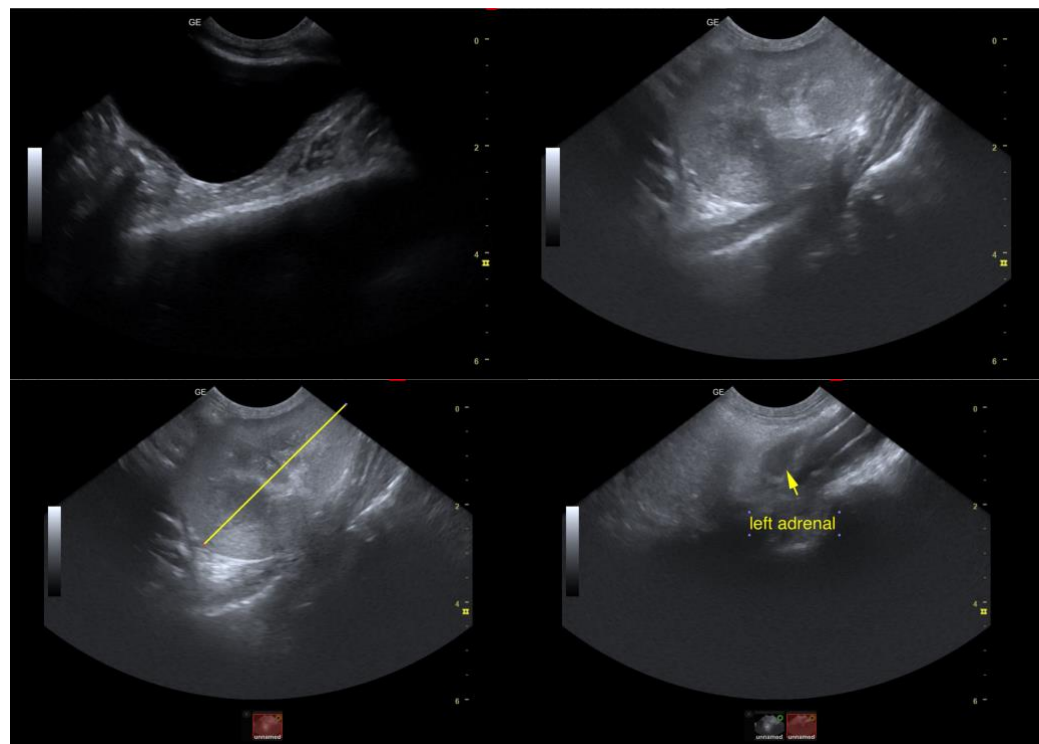
Ilija Mitrovic

**ULTRASONOGRAPHIC FINDINGS**

- Diffuse intestinal thickening
- Retention of ingesta in the stomach
- Mesenteric lymphadenopathy
- Irregular spleen
- Swollen irregular liver
- Enlarged and rounded hepatic lymph nodes
- Interstitial nephrosis pattern to the kidneys
- Age-related pancreatic changes
- Adrenal gland stress

**INTERPRETATION OF THE FINDINGS & FURTHER RECOMMENDATIONS**

Ultrasound guided FNA of the lymph nodes spleen and liver recommended to assess for lymphoma (strong potential). Chronic inflammatory bowel GI presentation. Prognosis is guarded depending upon cytology results.



**INVOICE**

17778

**DATE**

10/17/22



**PATIENT**

Abby Nibling

**SPECIES**

Feline

**BREED**

Mixed

**SEX**

Spayed Female

**AGE**

12 Years

**WEIGHT**

7 Pounds

**INTERPRETED BY**

Eric Lindquist, DMV  
DABVP, Cert. IVUSS

**IMAGING PERFORMED BY**

Byron Cabrera

**HOSPITAL NAME**

All Creatures Great &  
Small, Denville

**REFERRING VET**

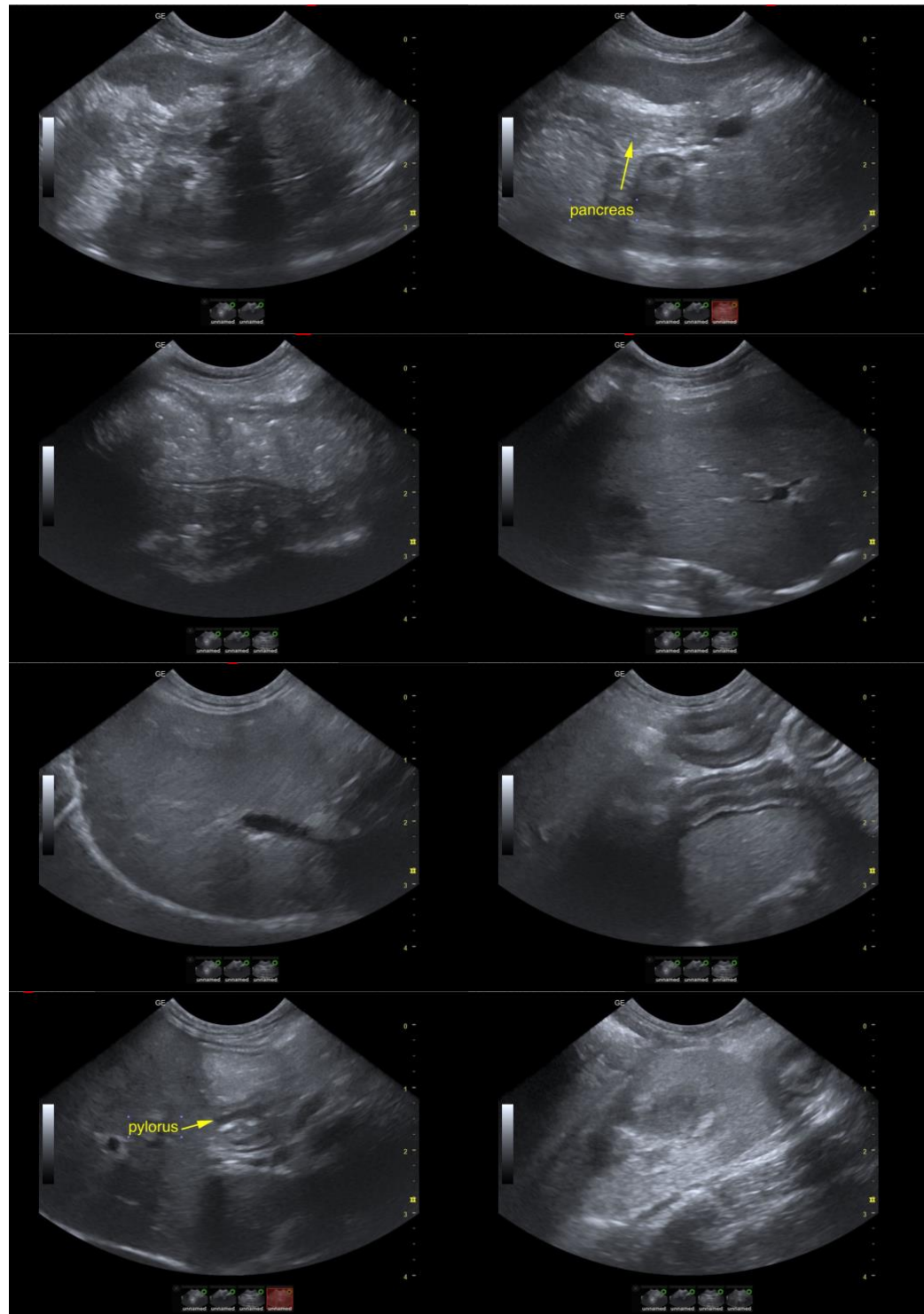
Ilija Mitrovic

**INVOICE**

17778

**DATE**

10/17/22





**PATIENT**

Abby Nibling

**SPECIES**

Feline

**BREED**

Mixed

**SEX**

Spayed Female

**AGE**

12 Years

**WEIGHT**

7 Pounds

**INTERPRETED BY**

Eric Lindquist, DMV  
DABVP, Cert. IVUSS

**IMAGING  
PERFORMED BY**

Byron Cabrera

**HOSPITAL NAME**

All Creatures Great &  
Small, Denville

**REFERRING VET**

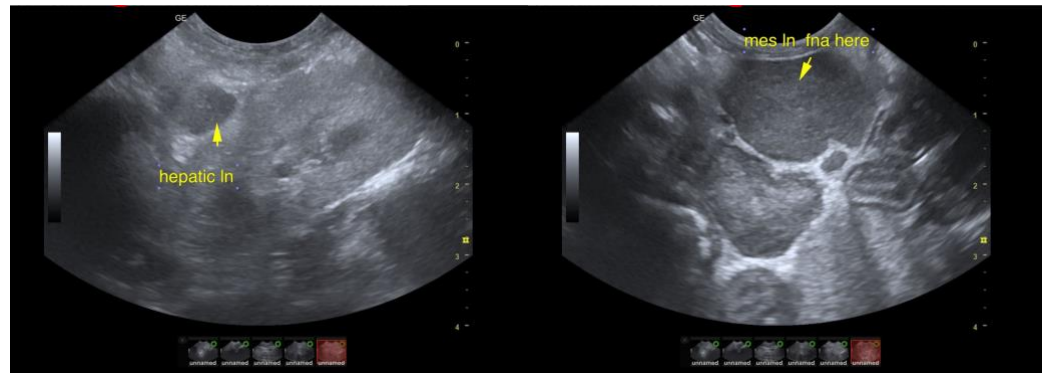
Ilija Mitrovic

**INVOICE**

17778

**DATE**

10/17/22



The information and recommendations provided are based on the images presented by the referring veterinarian. No evaluation can be communicated regarding pathology that was not visible in the image/video clips provided.

Thank you for this referral. If the clinical or image interpretation does not parallel your findings or if I can be of any further assistance please contact me.

**Eric Lindquist**, DMV, DABVP, Cert. IVUSS, CEO of SonoPath.com  
info@SonoPath.com