



|   |  |
|---|--|
| <b>PATIENT</b>                            | <b>PRESENTING CLINICAL SIGNS</b>   |
| Desmond Campbell                          | History: Sudden L prescapular lymphomegaly and PUPD.   |
| <b>SPECIES</b>                            | Abnormal PE/Chem/CBC/UA Results: L prescapular ln 8x6x4cm. Hypercalcemia (15) USG 1.012, hemoconcentration. Lytes and remainder of biochem normal.   |
| Canine                                    | <b>ULTRASONOGRAPHIC EXAMINATION OF THE ABDOMEN</b>   |
| <b>BREED</b>                              | <b>Urinary System</b>  |
| Mix                                       | The <b>urinary bladder</b> , trigone, and pelvic urethra presented normal thicknesses and normal tone. The ureters were not visible which is normal. No uroliths or sediment were visualized and anechoic urine was present. No evidence of inflammatory or neoplastic changes were noted. Ureteral papillae were normal. The pelvic urethra was imaged 2.0 cm beyond the cystourethral junction.  |
| <b>SEX</b>                                |  |
| Neutered Male                             | The <b>kidneys</b> revealed normal size and structure, corticomedullary definition and ratio for this age. The cortices presented largely uniform texture with normal echogenic relationship to liver and spleen. Medullary structure differed distinctly from the cortex and no evidence of pelvic dilation was present. The capsules were acceptably uniform without significant irregularities. The left kidney measured 6.0 cm. The right kidney measured 6.0 cm.  |
| <b>AGE</b>                                |  |
| 6 Years                                   | <b>Adrenal Glands</b>  |
| <b>WEIGHT</b>                             | The <b>left adrenal gland</b> was visualized and recognized as having normal shape, size, position and echogenicity for this breed. The phrenic vasculature, glandular echogenicity and detail were unremarkable. Capsule, cortex, and medullary definition were normal for this age patient. The left adrenal gland measured 0.4 cm.  |
| 25.5 Pounds                               | The <b>right adrenal gland</b> was imaged and revealed no evident pathology.   |
| <b>INTERPRETED BY</b>                     | <b>Spleen</b>  |
| Eric Lindquist, DMV<br>DABVP, Cert. IVUSS | The <b>spleen</b> presented a smooth homogeneous parenchyma hyperechoic to liver and renal cortical parenchyma. The capsule was smooth without noticeable expansion or deviation from within the spleen or adjacent pathology. The splenic vasculature demonstrated normal volume without signs of congestion or thrombosis. No sonographic evidence of acute or chronic inflammatory, neoplastic, or infarctual changes were noted. Cranial folding of the spleen was noted.  |
| <b>IMAGING PERFORMED BY</b>               |  |
| Sorbo                                     | <b>Liver</b>   |
| <b>HOSPITAL NAME</b>                      | The <b>liver</b> images submitted revealed subjectively normal liver size, contour, and structure. Parenchymal echogenicity was naturally coarse and hypoechoic to the spleen. Vascular and biliary tracts were of normal volume with no evidence of congestion. The gallbladder presented acceptably thin walls with primarily anechoic content. The cystic and common bile ducts were normal. No pathological hepatic lymphadenopathy was evident. No overt structural evidence of inflammatory, infiltrative or regenerative pathology was evident. |
| Back Bay VC                               |  |
| <b>REFERRING VET</b>                      |  |
| Campbell                                  |  |
| <b>INVOICE</b>                            | <b>Gastrointestinal</b>  |
| 13802                                     | Examination of the <b>gastrointestinal tract</b> revealed a stomach and intestine free of stasis, of normal wall thickness, acceptable curvilinear mural detail, and peristaltic activity. Small and large intestine demonstrated normal luminal chyme and stool consistency respectively. No obstructive or overt infiltrative disease was noted. No associated abnormal lymphatic activity was noted.  |
| <b>DATE</b>                               |  |
| 10/16/21                                  |  |



## PATIENT

Desmond Campbell

## SPECIES

Canine

## BREED

Mix

## SEX

Neutered Male

## AGE

6 Years

## WEIGHT

25.5 Pounds

## INTERPRETED BY

Eric Lindquist, DMV  
DABVP, Cert. IVUSS

## IMAGING PERFORMED BY

Sorbo

## HOSPITAL NAME

Back Bay VC

## REFERRING VET

Campbell

## INVOICE

13802

## DATE

10/16/21

## Pancreas

The base and limbs of the **pancreas** were observed to be largely isoechoic to surrounding omental fat. Pancreatic duct and capsular contour were acceptably normal and parenchyma respected normal curvilinear patterns. No overt evidence of active inflammatory or neoplastic disease was noted.

## Other

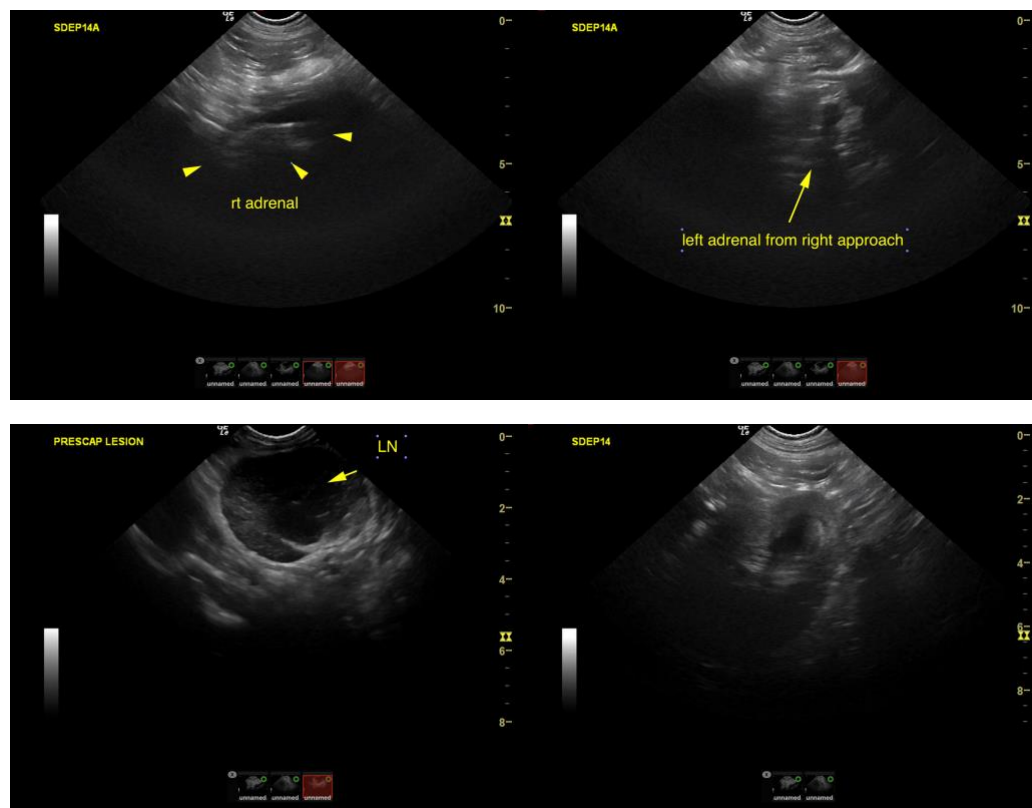
Prescapular **lymph node** noted, enlarged and undifferentiated, measuring 4.0 cm with pericapsular inflammatory pattern, strongly suggestive for round cell neoplasia or aggressive lymphadenitis- FNA warranted. No spread into the abdomen noted.

## ULTRASONOGRAPHIC FINDINGS

- Prescapular lymphadenopathy strongly suggestive for round cell neoplasia

## INTERPRETATION OF THE FINDINGS & FURTHER RECOMMENDATIONS

Radiographs or ultrasound warranted to check for cranial mediastinal lymph node which is common in paraneoplastic hypercalcemia with lymphoma.





## PATIENT

Desmond Campbell

## SPECIES

Canine

## BREED

Mix

## SEX

Neutered Male

## AGE

6 Years

## WEIGHT

25.5 Pounds

## INTERPRETED BY

Eric Lindquist, DMV  
DABVP, Cert. IVUSS

## IMAGING PERFORMED BY

Sorbo

## HOSPITAL NAME

Back Bay VC

## REFERRING VET

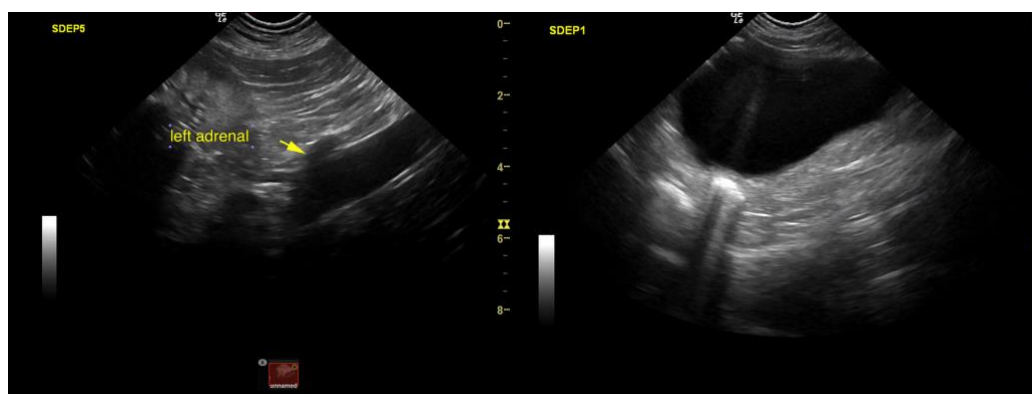
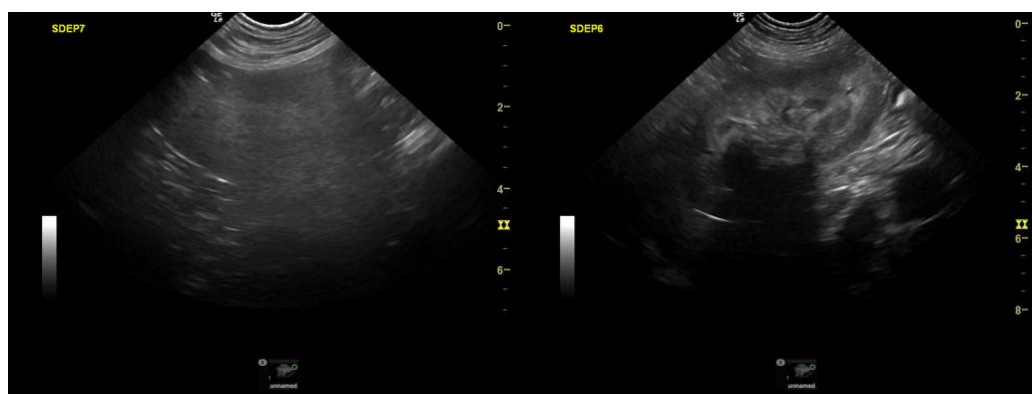
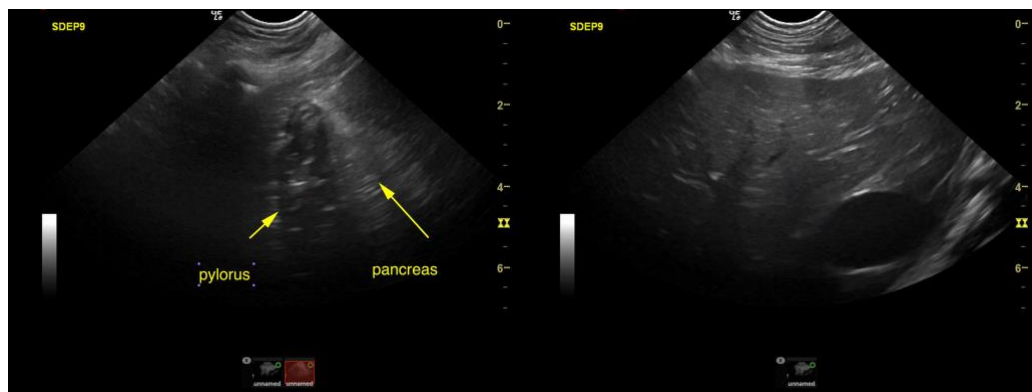
Campbell

## INVOICE

13802

## DATE

10/16/21



The information and recommendations provided are based on the images presented by the referring veterinarian. No evaluation can be communicated regarding pathology that was not visible in the image/video clips provided.

Thank you for this referral. If the clinical or image interpretation does not parallel your findings or if I can be of any further assistance please contact me.

**Eric Lindquist**, DMV, DABVP, Cert. IVUSS, CEO of SonoPath.com  
info@SonoPath.com