

**DATE PRESENTING CLINICAL SIGNS**

10/15/21 History: Not defecating. Episode of vomiting. Lethargic and weak.  
 PE: BCS 7.0/9. Temp 103.6 F. No other significant PE Findings.  
**PATIENT** Current Medications: N/A  
 Sam Hall Lab Results: Pancreatic lipase positive. T4 0.9 (1.1-4). GLOB 5.0 (2.1-4.9).  
 WBC 19.6 (6-17). LYM 0.9 (1-4.8). NEU 17.2 (3-12).  
**SPECIES** Radiographs: See attached.  
 Canine Date of Previous IntraPet Ultrasound: No previous.  
 Sedation: Not needed.  
 Stat Report: Declined.

**BREED****ULTRASONOGRAPHIC EXAMINATION OF THE ABDOMEN**

Golden Retriever

**Urinary System****SEX**

The **urinary bladder**, trigone, and pelvic urethra presented normal thicknesses and normal tone. The ureters were not visible which is normal. No uroliths or sediment were visualized, and anechoic urine was present. No evidence of inflammatory or neoplastic changes were noted. Ureteral papillae were normal.

Neutered Male

**AGE**

The **kidneys** revealed normal size and structure, corticomedullary definition and ratio for this age. The cortices presented largely uniform texture with normal echogenic relationship to liver and spleen.

2012

**WEIGHT**

Medullary structure differed distinctly from the cortex and no evidence of pelvic dilation was present. The capsules were acceptably uniform without significant irregularities. The right kidney measured 8.17 cm. The left kidney measured 8.34 cm.

107 Pounds

**INTERPRETED BY****Adrenal Glands**Eric Lindquist, DMV  
DABVP, Cert. IVUS

Both **adrenal glands** were visualized and recognized as having normal shape, size, position and echogenicity for this breed. The phrenic vasculature, glandular echogenicity and detail were unremarkable. Capsule, cortex, and medullary definition were normal for this age patient. The left adrenal gland measured 0.5 cm. The right adrenal gland measured 0.5 cm.

**HOSPITAL NAME****Spleen**

Friendly Paws VC

The **spleen** presented a smooth homogeneous parenchyma hyperechoic to liver and renal cortical parenchyma. The capsule was smooth without noticeable expansion or deviation from within the spleen or adjacent pathology. The splenic vasculature demonstrated normal volume without signs of congestion or thrombosis. No sonographic evidence of acute or chronic inflammatory, neoplastic, or infarctual changes were noted.

**REFERRING VET**

Dr. Price

**INVOICE****Liver**

13814

The **liver** images submitted revealed subjectively normal liver size, contour, and structure. Parenchymal echogenicity was naturally coarse and hypoechoic to the spleen. Vascular and biliary tracts were of normal volume with no evidence of congestion. The gallbladder presented acceptably thin walls with primarily anechoic content. The cystic and common bile ducts were normal. No pathological hepatic lymphadenopathy was evident. No overt structural evidence of inflammatory, infiltrative or regenerative pathology was evident.

**Gastrointestinal**

The **stomach** revealed distinctly shadowing material, measuring approximately 10.0 cm in length occupying the entire stomach, most consistent with fabric accumulation and fluid absorbing material. The small intestine and colon were unremarkable.

### **Pancreas**

The base and limbs of the **pancreas** were observed to be largely isoechoic to surrounding omental fat. Pancreatic duct and capsular contour were acceptably normal and parenchyma respected normal curvilinear patterns. No overt evidence of active inflammatory or neoplastic disease was noted.

### **ULTRASONOGRAPHIC FINDINGS**

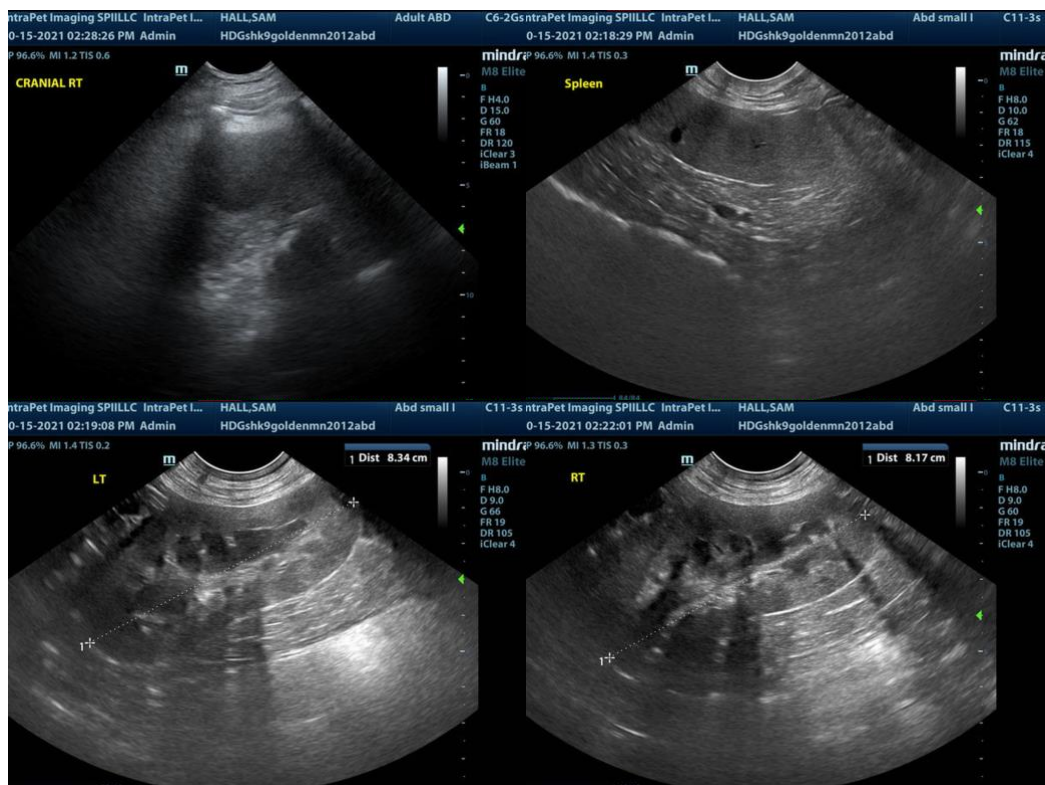
- Gastric foreign matter

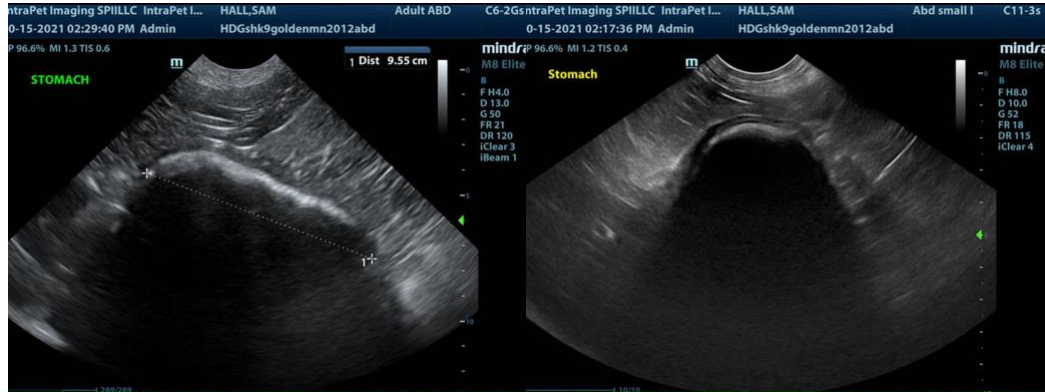
### **INTERPRETATION OF THE FINDINGS & FURTHER RECOMMENDATIONS**

Gastrotoomy recommended. GI biopsies warranted to rule out underlying disease even though structurally the GI tract is unremarkable.

GI Foreign Body Research

According to Sonopath research presented at ECVIM 2016 (Stockholm, Sweden), Advances in Small Animal Medicine and Surgery (May 2017), and EVDI 2017 (Verona, Italy), concurrent underlying chronic inflammatory neoplastic intestinal disease can often reside in PICA patients. Therefore, surgical biopsies are essential in this case regardless of the exploratory findings.





**The information and recommendations provided are based on the images presented by the referring veterinarian. No evaluation can be communicated regarding pathology that was not visible in the image/video clips provided.**

Thank you for this referral. If the clinical or image interpretation does not parallel your findings or if I can be of any further assistance please contact me.

**Eric Lindquist**, DMV, DABVP, Cert. IVUSS, CEO of SonoPath.com  
[info@SonoPath.com](mailto:info@SonoPath.com)