



**PATIENT**

Gabby Gennari

**PRESENTING CLINICAL SIGNS**

Dyspnea x 3 days. No previous history. Treated with Lasix and Unasyn.

**SPECIES**

Feline

**ULTRASONOGRAPHIC EXAMINATION OF THE HEART**

**BREED**

DSH

**SEX**

Neutered Male

**AGE**

14 Years

**WEIGHT**

11 Pounds

FELINE CARDIAC PARAMETERS	BODY WEIGHT (kg)	HR (BPM)	IVSd (cm)	LVIDd (cm)	LVWd (cm)	FS (%)	EF (%)
NORMAL PARAMETER	-----	150-240	0.3-0.6	1.0-2.1	0.25-0.6	35-67	80-100
PATIENT		NM					
FELINE CARDIAC PARAMETERS	LA/AO (Boon)	LA/AO HEART BASE (Sisson)	LA 2D 4-chamber long axis AS to FW (Sisson) (cm)		LVOT VEL. (m/s)	RVOT VEL. (m/s)	IVRT (m/)
NORMAL PARAMETER	<1.5	0.88-1.79	0.7-1.7		<1.6	<1.3	40-60
PATIENT	2.4		3.03				NM

Adapted from June Boon, Veterinary Echocardiography, 1998  
Sisson D et al. JVIM 1991; 5: 232, Jacobs et al. Am J Vet Res 1985; 46:1705

**INTERPRETED BY**

Eric Lindquist, DMV DABVP, Cert. IVUSS

**Cardiac Presentation**

The cardiac Presentation revealed severe volume overload of the left atrium and left ventricle with hypocontractility and bradyarrhythmia. Rapid echocardiogram performed owing to the precarious nature of the presentation. Mitral and tricuspid insufficiency noted. Pleural effusion and mild pericardial effusion noted with smoke in both atria. Right and left-sided heart failure.

**IMAGING PERFORMED BY**

Kelly Vazquez

**ULTRASONOGRAPHIC FINDINGS**

- Severe end stage congestive heart failure in the left and right heart
- Unclassified cardiomyopathy

**HOSPITAL NAME**

Westwood Regional

**INTERPRETATION OF THE FINDINGS & FURTHER RECOMMENDATIONS**

This patient is at high risk for sudden death. Lasix at 2-3 mg/kg BID, Pimobendan 0.3 mg/kg BID off-label, Plavix therapy, ACE inhibitor, heat support, and oxygen all indicated. However, humane euthanasia should be considered in this patient.

**REFERRING VET**

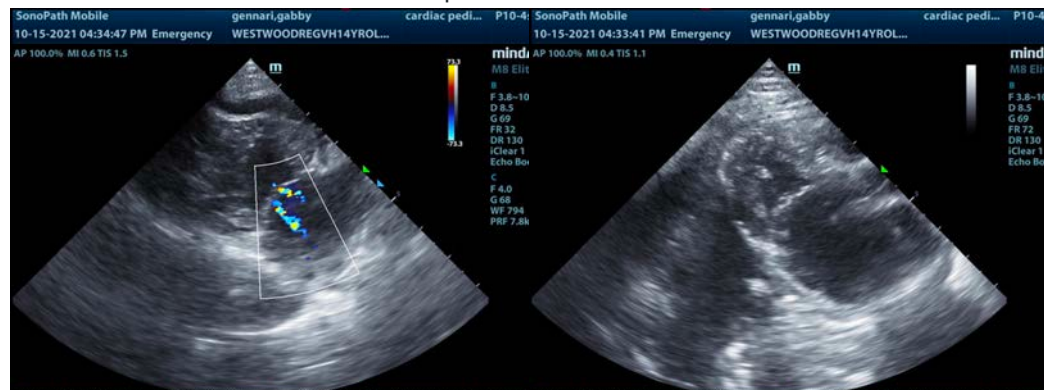
Dr. Murphy

**INVOICE**

26312

**DATE**

10/15/21





**PATIENT**

Gabby Gennari

**SPECIES**

Feline

**BREED**

DSH

**SEX**

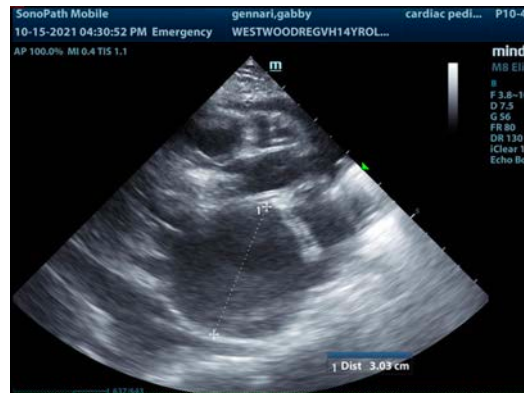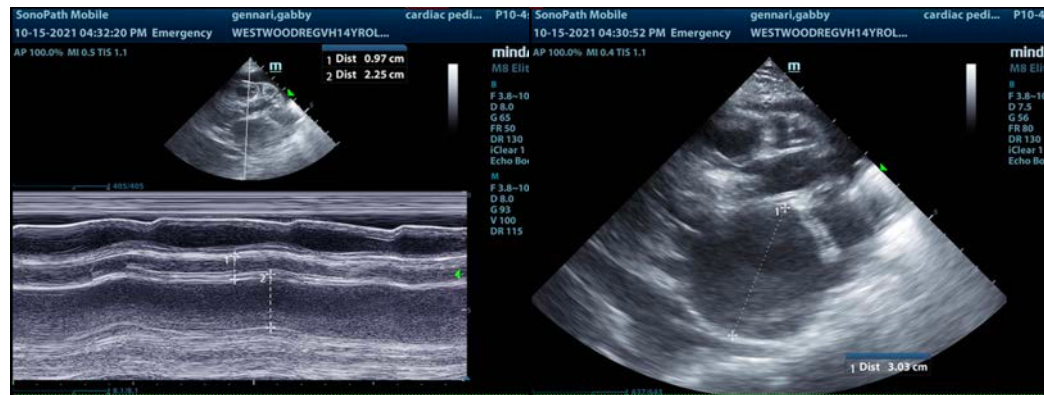
Neutered Male

**AGE**

14 Years

**WEIGHT**

11 Pounds



**INTERPRETED BY**

Eric Lindquist, DMV  
DABVP, Cert. IVUSS

**IMAGING PERFORMED BY**

Kelly Vazquez

**HOSPITAL NAME**

Westwood Regional

**REFERRING VET**

Dr. Murphy

**INVOICE**

26312

**DATE**

10/15/21

The information and recommendations provided are based on the images presented by the referring veterinarian. No evaluation can be communicated regarding pathology that was not visible in the image/video clips provided.

Thank you for this referral. If the clinical or image interpretation does not parallel your findings or if I can be of any further assistance please contact me.

Eric Lindquist, DMV, DABVP, Cert. IVUSS, CEO of SonoPath.com  
[info@SonoPath.com](mailto:info@SonoPath.com)