



PATIENT

Famous Roberts

SPECIES

Canine

BREED

Pitbull

SEX

Neutered Male

AGE

13 Years 6 Months

WEIGHT

62 Pounds

INTERPRETED BY

Eric Lindquist, DMV
DABVP, Cert. IVUSS

IMAGING PERFORMED BY

Carter

HOSPITAL NAME

Willamette VH

REFERRING VET

Carter

INVOICE

13789

DATE

10/15/21

PRESENTING CLINICAL SIGNS

History: Referred from Ark Animal Hosp for recurrent bladder infections, incontinence. Concerned about prostate cancer. Has been treated with repeated courses of antibiotics. No improvement. Frequent urination, stranguria, pollakiuria. O reports has been having bladder infections off and on at least 2 yrs. O considering splenectomy and potential bladder biopsy/culture at that time.

Abnormal PE/Chem/CBC/UA Results: UA on 10-5. USG 1.030, 3+ blood, , increased wbc. rods. Culture grew e. coli. Same in Sept. Had toe amputation in July; hemangiopericytoma In July had Hct 37% and increased platelets Submitting Cadet Braf test; results pending

ULTRASONOGRAPHIC EXAMINATION OF THE ABDOMEN

Urinary System

The **urinary bladder** revealed apical wall thickening with polypoid changes, measuring approximately 3.0 cm. A minimal amount of urine was present in the bladder. The cystourethral junction and urethra were thickened, suggestive for infiltrative disease. However, the prostate (3.0 cm) was enlarged with areas of mineralization. The pre-prostatic urethra was also mineralized. Iliac trifurcation was unremarkable.

The **kidneys** revealed largely normal size and structure, corticomedullary definition and ratio (cortex 1/3 of medulla) were essentially maintained with some mild age-related loss of curvilinear patterns regarding the capsule and C/M junction. The cortices presented largely uniform texture with some increased echogenicity expected for his age patient. Medullary structure differed distinctly from that of the cortex. Mineralization was present in the kidneys. The left kidney measured 5.9 cm. The right kidney measured 7.26 cm. Trace pyelectasia was noted in the right kidney.

Adrenal Glands

The **left adrenal gland** was visualized and recognized as having normal shape, size, position and echogenicity for this breed. The phrenic vasculature, glandular echogenicity and detail were unremarkable. Capsule, cortex, and medullary definition were normal for this age patient. The left adrenal gland measured 0.41 cm at the cranial pole and 0.63 cm at the caudal pole.

The **right adrenal gland** revealed no evident pathology.

Spleen

The **spleen** revealed an expansive hypoechoic 2.9 cm mass at the mid cranial body.

Liver

The **liver** images from right and left intercostal as well as subcostal views revealed subjectively normal liver size, contour, and structure. Some mild age-related parenchymal remodeling was noted but likely not clinically significant at this time. Vascular and biliary tracts were of normal volume and no evidence of congestion was noted. The gallbladder presented some dependent debris with essentially normal contour. The cystic and common bile ducts were normal. No overt evidence of active inflammatory, infiltrative or regenerative pathology was noted but should be paired with current or past LE elevations regarding any clinical significance to this presentation. The hepatic lymph nodes were unremarkable.



PATIENT

Gastrointestinal

Famous Roberts

The **stomach** was filled with ingesta. No evidence of pathology. The small intestine and colon were unremarkable.

SPECIES

Pancreas

Canine

The base and limbs of the **pancreas** were observed to be largely isoechoic to surrounding omental fat. Pancreatic duct and capsular contour were acceptably normal and parenchyma respected normal curvilinear patterns. No overt evidence of active inflammatory or neoplastic disease was noted.

BREED

Pitbull

ULTRASONOGRAPHIC FINDINGS

SEX

- Mineralized, enlarged prostate and urethra
- Polypoid bladder changes
- Mild to moderate degenerative renal changes
- Concurrent splenic mass
- Stomach ingesta
- Age-related hepatic changes

Neutered Male

AGE

13 Years 6 Months

INTERPRETATION OF THE FINDINGS & FURTHER RECOMMENDATIONS

WEIGHT

Lower urinary tract neoplasia consistent with carcinoma likely deriving from the prostate or from the bladder itself. Traumatic catheterization with ultrasound guidance could be considered for a definitive diagnosis.

62 Pounds

INTERPRETED BY

Eric Lindquist, DMV
DABVP, Cert. IVUSS

IMAGING PERFORMED BY

Carter

HOSPITAL NAME

Willamette VH

REFERRING VET

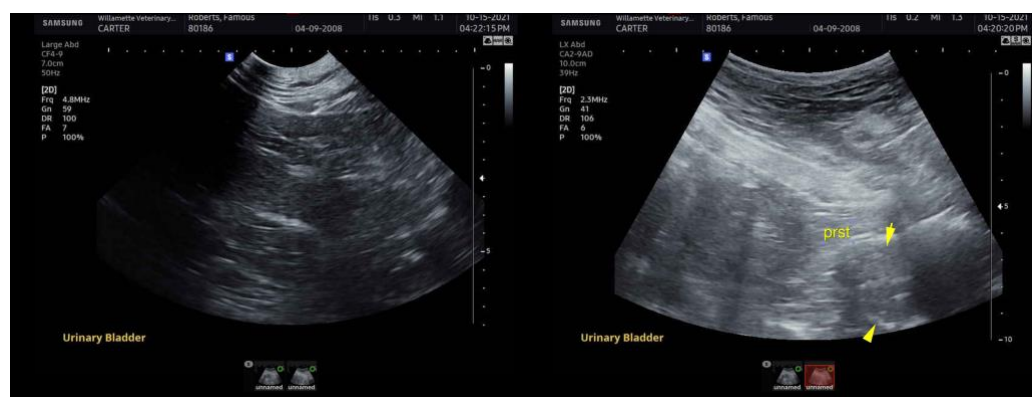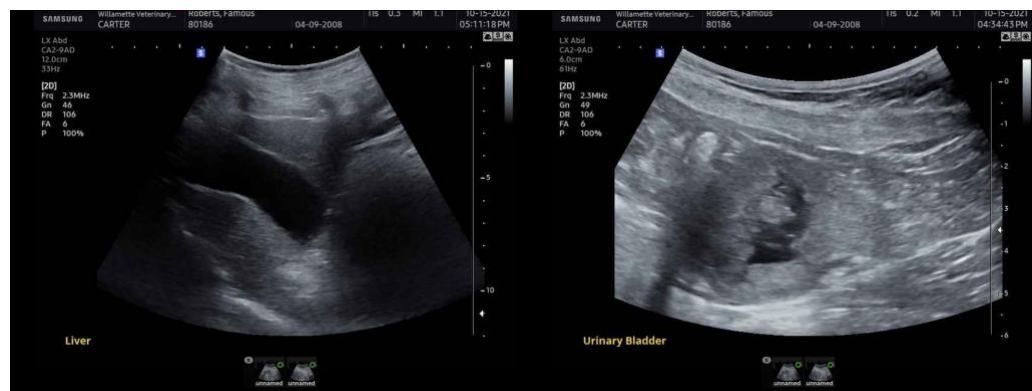Carter

INVOICE

13789

DATE

10/15/21





PATIENT

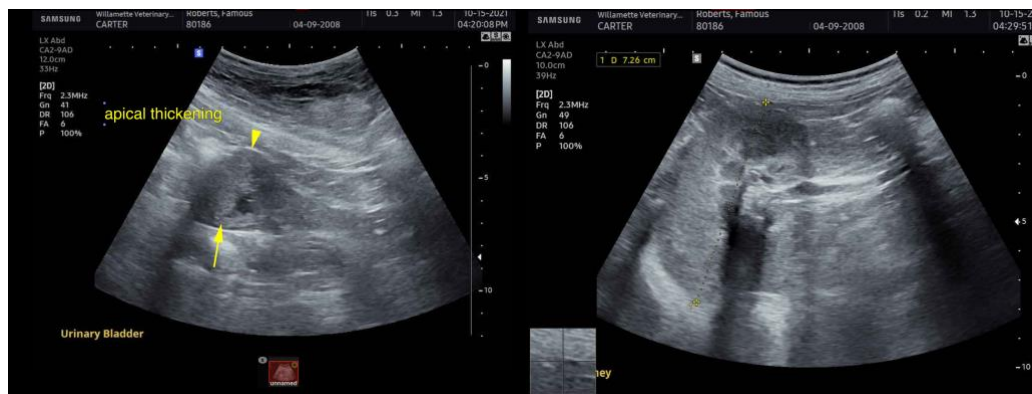Famous Roberts

SPECIES

Canine

BREED

Pitbull



SEX

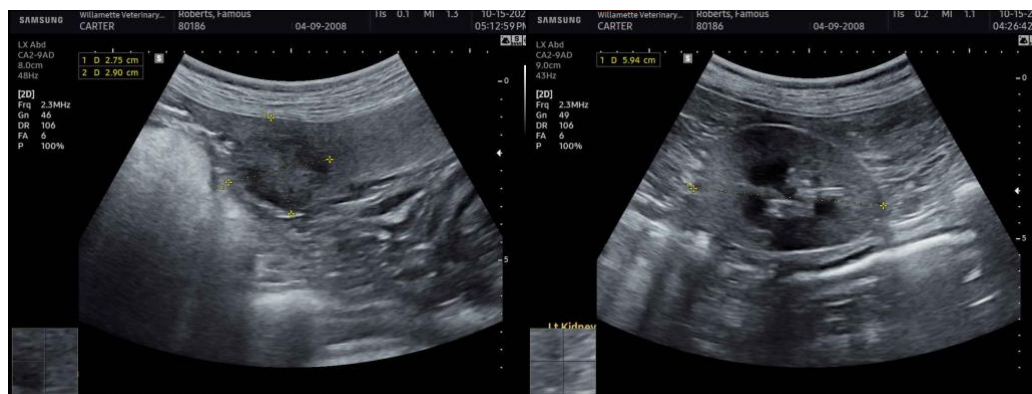Neutered Male

AGE

13 Years 6 Months

WEIGHT

62 Pounds



INTERPRETED BY

Eric Lindquist, DMV
DABVP, Cert. IVUSS

IMAGING PERFORMED BY

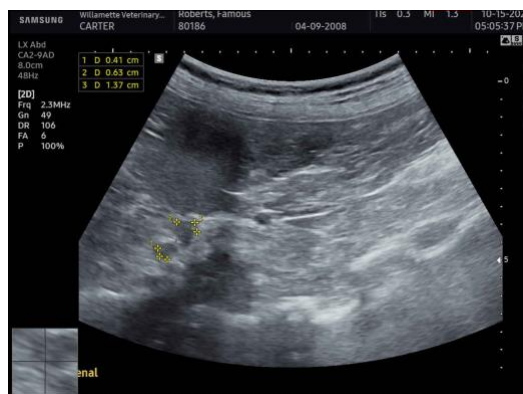
Carter

HOSPITAL NAME

Willamette VH

REFERRING VET

Carter



The information and recommendations provided are based on the images presented by the referring veterinarian. No evaluation can be communicated regarding pathology that was not visible in the image/video clips provided.

Thank you for this referral. If the clinical or image interpretation does not parallel your findings or if I can be of any further assistance please contact me.

INVOICE

13789

Eric Lindquist, DMV, DABVP, Cert. IVUSS, CEO of SonoPath.com
info@SonoPath.com

DATE

10/15/21

Canine Prostatic Neoplasia

<http://www.sonopath.com/ProstaticCarcinoma>



PATIENT

Famous Roberts

SPECIES

Canine

BREED

Pitbull

SEX

Neutered Male

AGE

13 Years 6 Months

WEIGHT

62 Pounds

INTERPRETED BY

Eric Lindquist, DMV
DABVP, Cert. IVUSS

IMAGING PERFORMED BY

Carter

HOSPITAL NAME

Willamette VH

REFERRING VET

Carter

INVOICE

13789

DATE

10/15/21

Description: Prostatic neoplasia is frequently seen in dogs and can be diagnosed via ultrasonographic examination. The most commonly diagnosed prostatic neoplasms are adenocarcinoma and undifferentiated carcinoma. Transitional cell carcinoma (TCC) frequently spreads from the urinary bladder and urethra to the prostatic tissue (see the “Transitional Cell Carcinoma” chapter for more details). Metastatic squamous cell carcinoma, lymphoma, hemangiosarcoma, and leiomyosarcoma have been reported, but are less prevalent. Prostatic neoplasia has been documented in cats, but is quite rare.

Clinical Signs: Prostatic neoplasia presents in both neutered and intact males; however, a 2002 study suggested that neutered males were at greater risk for developing prostatic neoplasia than intact males. Typically, prostatic neoplasia is seen in older dogs (mean age of 10 years). Breed predilection includes mixed breed dogs, Shetland Sheepdogs, Dobermans, Scottish Terriers, and Airedale Terriers. Clinical signs and commonly reported signs from owners typically include: stranguria, frequent urinations, hematuria, dyschezia, weight loss, and decreased appetite. Other findings upon physical examination include fever, ataxia, pain upon rectal examination, and pain upon spinal palpation.

Diagnostics: Ultrasonographic examination should be performed if prostatic neoplasia is suspected. Common ultrasonographic findings include an enlarged, irregular prostate that typically has a hypoechoic appearance. Multifocal, poorly coalescing hyperechoic foci are also seen in prostatic malignancies. Hyperechoic foci are due to mineralization of the prostate; they cause far field shadowing. Cystic components can also be observed and are thought to indicate abscessation and/or necrosis. It can be difficult to differentiate chronic bacterial prostatitis from a prostatic neoplasia; however, regional lymphadenopathy is much more common with prostatic neoplasia than it is with chronic bacterial prostatitis. Malignancies of the prostate have often metastasized by the time of diagnosis. Frequent sites of metastases include the sublumbar lymph nodes, the pelvis, lumbar vertebrae, and the lungs. If metastases to the pelvis or lumbar vertebrae have occurred, bony lysis will often be noted radiographically. Metastasis to the liver, brain, kidney and spleen may occur. A definitive diagnosis of a prostatic neoplasm can be achieved through biopsy as well as fine needle aspiration (FNA) or through ultrasound-guided traumatic catheterization.

A complete and thorough workup includes a CBC, biochemical profile, urinalysis, as well as three radiographic views of the thorax, an abdominal ultrasound, and an ultrasound-guided prostatic biopsy or FNA, if indicated. Urinalysis may reveal hematuria and pyuria. Prostatic fluid analysis can also be helpful in identifying neoplastic cells.

Treatment: Unfortunately, once diagnosed, prostatic carcinoma offers a poor prognosis; prostatectomy, chemotherapy, and radiation therapy have proven unsuccessful in improving quality or length of life. Nonsteroidal anti-inflammatory drugs (NSAIDs), such as deracoxib, meloxicam, and piroxicam, have been used for their palliative, anti-neoplastic properties with prostatic carcinomas. Certain tumors, including various carcinomas (e.g. TCC, prostatic carcinoma, mammary carcinoma, squamous cell carcinoma) overexpress COX-2, which converts arachidonic acid to prostaglandin G₂ (PGG₂)/prostaglandin H₂ (PGH₂), and ultimately to prostaglandin E₂ (PGE₂). The metabolite, PGE₂, is associated with increased inflammation, tumor invasiveness, angiogenesis, and reduced apoptosis. In vivo and in vitro, NSAIDs inhibit COX-2, resulting in the suppression of PGE₂, and



PATIENT	thereby inhibiting tumor growth and metastasis. This effect has been achieved with both non-selective COX inhibitors as well as COX-2 inhibitors (the latter will suppress COX-1 at increased doses).
Famous Roberts	
SPECIES	Some cases of prostatic carcinoma are managed palliatively with cyst/abscess ultrasound-guided drainage, antibiotic infusion, systemic antibiotics, and NSAID treatment and/or chemotherapy. Anecdotally, it has been observed that patients that often present clinical signs of hematuria or dysuria owing to cyst or abscess formation may be treated with repeat ultrasound-guided drainage.
Canine	
BREED	This appears to work especially well if there is a considerable cystic component to the prostatic tumor. The key is to image the prostate adequately, drain any cysts that are present, sample the abnormal parenchyma (FNA or biopsy), and potentially infuse antibiotics directly into the cystic cavities if a suppurative fluid is retrieved. The patient should be monitored clinically over time and reevaluated to see if cysts recur. Every case responds differently to treatment, and the behavior of parenchymal and cystic growth will vary.
Pitbull	
SEX	
Neutered Male	
AGE	Currently, investigational studies involving fluoroscopic-guided direct chemotherapeutic embolization through the iliac arteries as well as urethral stent placement are offered by select tertiary veterinary facilities that have an interventional radiology department. Ultrasound-guided endoscopic diode laser ablation through a perineal urethrostomy is also being attempted as a salvage and palliative procedure.
13 Years 6 Months	
WEIGHT	
62 Pounds	
INTERPRETED BY	Conclusion: Prostatic neoplasia is more commonly detected in neutered male dogs than intact males. Diagnosis is typically obtained using ultrasound, cytology, and histopathology. Unfortunately, traditional therapy typically yields a guarded to poor long-term prognosis, but palliation with NSAIDs and/or chemotherapy can temporarily improve clinical signs. Investigational techniques may provide additional therapeutic options but are currently experimental.
Eric Lindquist, DMV DABVP, Cert. IVUSS	
IMAGING PERFORMED BY	References:
Carter	Cerf DJ, Lindquist EC. Palliative ultrasound-guided endoscopic laser ablation of transitional cell carcinomas of the lower urinary tract in dogs. <i>J Am Vet Med Assoc</i> 2012;240(1):51-60.
HOSPITAL NAME	Culp, WTN. Interventional oncology and the management of urinary tract cancer. Proceedings from the American College of Veterinary Internal Medicine, New Orleans, LA, May 30-June 2, 2012.
Willamette VH	
REFERRING VET	Francey T. Prostatic Diseases. In: Ettinger SJ, Feldman EC, eds. <i>Textbook of Veterinary Internal Medicine 7th ed.</i> Philadelphia, PA: WB Saunders; 2010:2047-58.
Carter	Hecht S. Male Reproductive Tract. In: Pennick D, D'Anjou MA, eds. <i>Atlas of Small Animal Ultrasonography.</i> Ames, IA: Blackwell Publishing; 2008:417-43.
INVOICE	Milner RJ. Do NSAIDs make a difference in cancer. Proceedings from the American College of Veterinary Internal Medicine, Denver, CO, June 15-18, 2011.
13789	
DATE	
10/15/21	



PATIENT

Famous Roberts

Mohammed SI, Khan KN, Sellers RS, et al. Expression of cyclooxygenase-1 and 2 in naturally-occurring canine cancer. *Prostag Leukotr Ess* 2004;70(5):479-83.

SPECIES

Canine

Nyland, TG, Mattoon JS. *Small Animal Diagnostic Ultrasound 2nd ed.* Philadelphia, PA: WB Saunders; 2002:250-66.

BREED

Pitbull

Sorenmo KU, Goldschmidt MH, Shofer FS, et al. Evaluation of cyclooxygenase-1 and cyclooxygenase-2 expression and the effect of cyclooxygenase inhibitors in canine prostatic carcinoma. *Vet Comp Oncol* 2004;2(1):13-23.

SEX

Neutered Male

AGE

13 Years 6 Months

WEIGHT

62 Pounds

INTERPRETED BY

Eric Lindquist, DMV
DABVP, Cert. IVUSS

**IMAGING
PERFORMED BY**

Carter

HOSPITAL NAME

Willamette VH

REFERRING VET

Carter

INVOICE

13789

DATE

10/15/21