



PATIENT

Brynn Fortich

SPECIES

Canine

BREED

Poodle/Yorkie

SEX

Spayed Female

AGE

2.5 Years

WEIGHT

10.8 Pounds

INTERPRETED BY

Eric Lindquist, DMV

DABVP, Cert. IVUSS

IMAGING PERFORMED BY

Dr. John Ammeraal

HOSPITAL NAME

Sova Animal Hospital

REFERRING VET

Dr. John Ammeraal

INVOICE

42063

DATE

10/14/22

PRESENTING CLINICAL SIGNS

Presenting for abdominal discomfort pacing this AM. Vomited up a couple foreign pieces of plastic material. Seems to be more comfortable. Also has liquid diarrhea

Abnormal PE/Chem/CBC/UA Results: Mild discomfort Abdominal Rads - possible FB in stomach. CBC mod dehydration. Chem Overall normal

ULTRASONOGRAPHIC EXAMINATION OF THE ABDOMEN

Urinary System

The **urinary bladder**, trigone, and pelvic urethra presented normal thicknesses and normal tone. The ureters were not visible which is normal. No uroliths or sediment were visualized and anechoic urine was present. No evidence of inflammatory or neoplastic changes were noted. Ureteral papillae were normal.

The **kidneys** revealed normal size and structure, corticomedullary definition and ratio for this age. The cortices presented largely uniform texture with normal echogenic relationship to liver and spleen. Medullary structure differed distinctly from the cortex and no evidence of pelvic dilation was present. The capsules were acceptably uniform without significant irregularities. The left kidney measured 3.4 cm. The right kidney measured 3.4 cm.

Adrenal Glands

Both **adrenal glands** were visualized and recognized as having normal shape, size, position and echogenicity for this breed. The phrenic vasculature, glandular echogenicity and detail were unremarkable. Capsule, cortex, and medullary definition were normal for this age patient. The right adrenal gland measured 1.89 cm x 0.47 cm at the cranial pole and 0.41 cm at the caudal pole. The left adrenal gland measured 1.63 cm x 0.46 cm at the cranial pole and 0.51 cm at the caudal pole.

Spleen

The **spleen** presented a smooth homogeneous parenchyma hyperechoic to liver and renal cortical parenchyma. The capsule was smooth without noticeable expansion or deviation from within the spleen or adjacent pathology. The splenic vasculature demonstrated normal volume without signs of congestion or thrombosis. No sonographic evidence of acute or chronic inflammatory, neoplastic, or infarctual changes were noted.

Liver

The **liver** images submitted revealed subjectively normal liver size, contour, and structure. Parenchymal echogenicity was naturally coarse and hypoechoic to the spleen. Vascular and biliary tracts were of normal volume with no evidence of congestion. The gallbladder presented acceptably thin walls with primarily anechoic content. The cystic and common bile ducts were normal. No pathological hepatic lymphadenopathy was evident. No overt structural evidence of inflammatory, infiltrative or regenerative pathology was evident.

Gastrointestinal

The **stomach** revealed a minor amount of fluid accumulation. Curvilinear patterns were maintained. The distal small intestine was variably thickened with reactive mesentery, consistent with acute on chronic inflammatory bowel. No overt foreign body noted.



PATIENT

Pancreas

Brynn Fortich

The base and limbs of the **pancreas** were observed to be largely isoechoic to surrounding omental fat. Pancreatic duct and capsular contour were acceptably normal and parenchyma respected normal curvilinear patterns. No overt evidence of active inflammatory or neoplastic disease was noted.

SPECIES

Canine

ULTRASONOGRAPHIC FINDINGS

- Gastritis/enteritis pattern

BREED

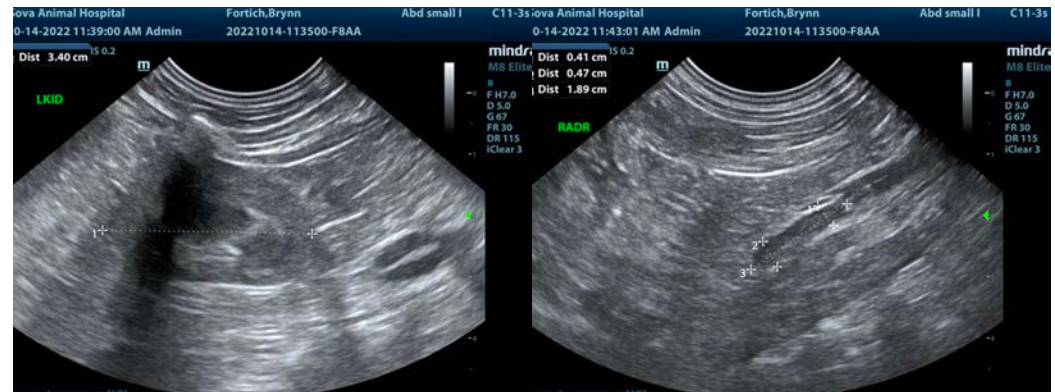
INTERPRETATION OF THE FINDINGS & FURTHER RECOMMENDATIONS

Poodle/Yorkie

Medical management warranted over the next 48-72 hours and recheck sonogram.

SEX

Spayed Female



AGE

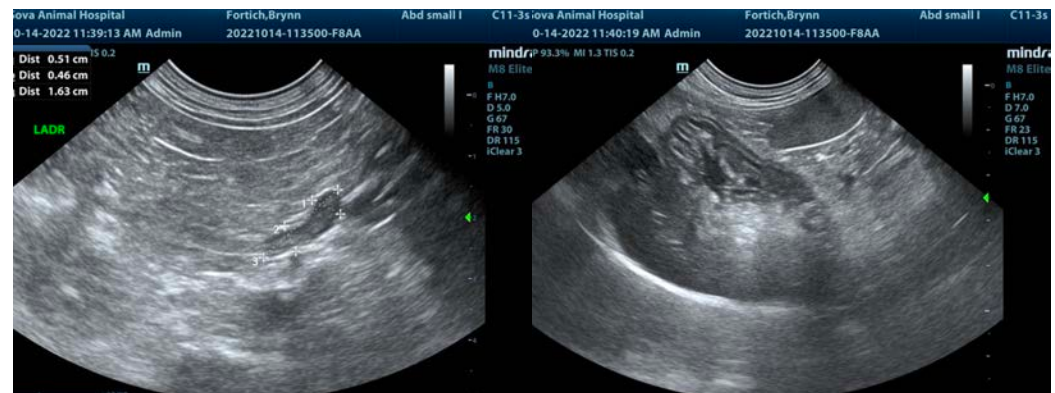
2.5 Years

WEIGHT

10.8 Pounds

INTERPRETED BY

Eric Lindquist, DMV
DABVP, Cert. IVUSS

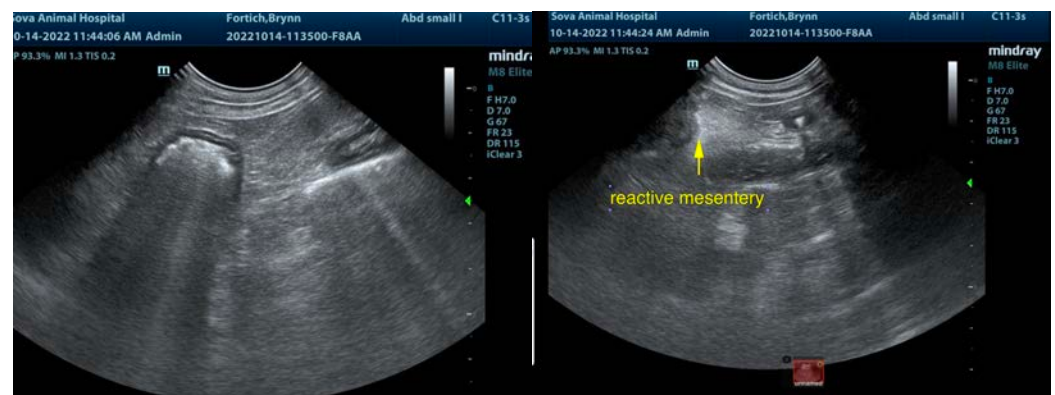


IMAGING PERFORMED BY

Dr. John Ammeraal

HOSPITAL NAME

Sova Animal Hospital



REFERRING VET

Dr. John Ammeraal

INVOICE

42063

DATE

10/14/22



PATIENT

Brynn Fortich

The information and recommendations provided are based on the images presented by the referring veterinarian/sonographer. No evaluation can be communicated regarding pathology that was not visible in the image/video clips provided.

SPECIES

Canine

Thank you for this referral. If the clinical or image interpretation does not parallel your findings or if I can be of any further assistance please contact me.

Eric Lindquist, DMV, DABVP, Cert. IVUSS, CEO of SonoPath.com

info@SonoPath.com

BREED

Poodle/Yorkie

SEX

Spayed Female

AGE

2.5 Years

WEIGHT

10.8 Pounds

INTERPRETED BY

Eric Lindquist, DMV

DABVP, Cert. IVUSS

IMAGING PERFORMED BY

Dr. John Ammeraal

HOSPITAL NAME

Sova Animal Hospital

REFERRING VET

Dr. John Ammeraal

INVOICE

42063

DATE

10/14/22