



PATIENT PRESENTING CLINICAL SIGNS

Olive Ricciardi History: recheck

SPECIES ULTRASONOGRAPHIC EXAMINATION OF THE ABDOMEN

Canine **Urinary System**

BREED The **urinary bladder**, trigone, and pelvic urethra presented normal thicknesses and normal tone. The ureters were not visible which is normal. No uroliths or sediment were visualized and anechoic urine was present. No evidence of inflammatory or neoplastic changes was noted. Ureteral papillae were normal.

Jack Russell

SEX

Spayed Female

The **kidneys** revealed normal size and structure, corticomedullary definition and ratio for this age. The cortices presented largely uniform texture with normal echogenic relationship to liver and spleen. Medullary structure differed distinctly from the cortex and no evidence of pelvic dilation was present. The capsules were acceptably uniform without significant irregularities. The right kidney measured 4.2 cm. The left kidney measured 4.2 cm.

AGE

2 years

Adrenal Glands

WEIGHT

16 lbs

Both **adrenal glands** were visualized and recognized as having normal shape, size, position and echogenicity for this breed. The phrenic vasculature, glandular echogenicity and detail were unremarkable. Capsule, cortex, and medullary definition were normal for this age patient. The left adrenal gland measured 1.0 x 0.4 cm at the caudal pole and 0.48 cm at the cranial pole. The right adrenal gland measured 1.63 x 0.43 cm at the caudal pole and 0.61 cm at the cranial pole.

INTERPRETED BY

Eric Lindquist, DMV
DABVP, Cert. IVUSS

Spleen

IMAGING PERFORMED BY

Jenn

The **spleen** presented a smooth homogeneous parenchyma hyperechoic to liver and renal cortical parenchyma. The capsule was smooth without noticeable expansion or deviation from within the spleen or adjacent pathology. The splenic vasculature demonstrated normal volume without signs of congestion or thrombosis. No sonographic evidence of acute or chronic inflammatory, neoplastic, or infarctual changes was noted.

HOSPITAL NAME

Rockaway AH

Liver

REFERRING VET

Dr. Maniar

The **liver** images submitted revealed subjectively normal liver size, contour, and structure. Parenchymal echogenicity was naturally coarse and hypoechoic to the spleen. Vascular and biliary tracts were of normal volume with no evidence of congestion. The gallbladder presented acceptably thin walls with primarily anechoic content. The cystic and common bile ducts were normal. No pathological hepatic lymphadenopathy was evident. No overt structural evidence of inflammatory, infiltrative or regenerative pathology was evident.

INVOICE

92378

DATE

10/14/21



PATIENT

Gastrointestinal

Olive Ricciardi

The **stomach** presented a minor amount of fluid filled lumen. The gastric wall was normal. The small intestines and colon were unremarkable.

SPECIES

Canine

Pancreas

BREED

Jack Russell

The base and limbs of the **pancreas** were observed to be largely isoechoic to surrounding omental fat. Pancreatic duct and capsular contour were acceptably normal and parenchyma respected normal curvilinear patterns. No overt evidence of active inflammatory or neoplastic disease was noted.

SEX

Spayed Female

ULTRASONOGRAPHIC FINDINGS

Unremarkable abdomen.

AGE

2 years

INTERPRETATION OF THE FINDINGS & FURTHER RECOMMENDATIONS

There was no evidence of a foreign body or other pathology. Supportive care should prove effective.

WEIGHT

16 lbs

INTERPRETED BY

Eric Lindquist, DMV
DABVP, Cert. IVUSS

IMAGING PERFORMED BY

Jenn

HOSPITAL NAME

Rockaway AH

REFERRING VET

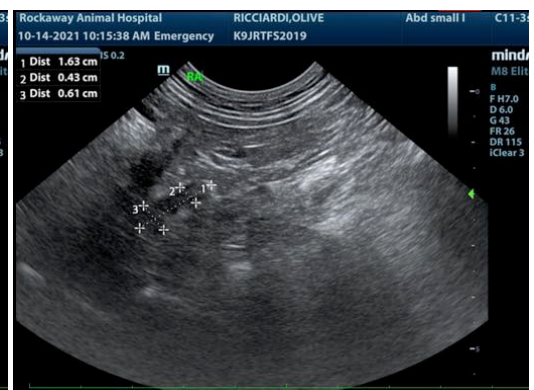
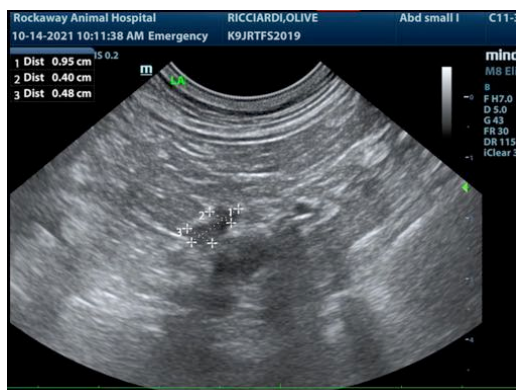
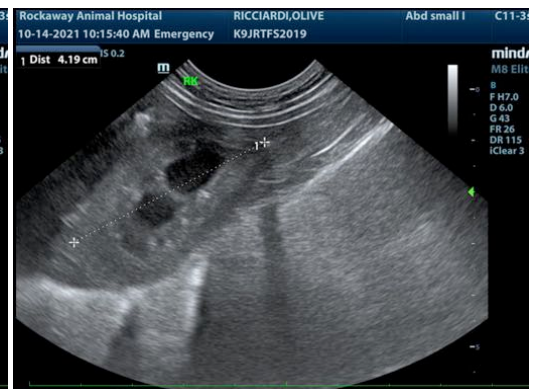
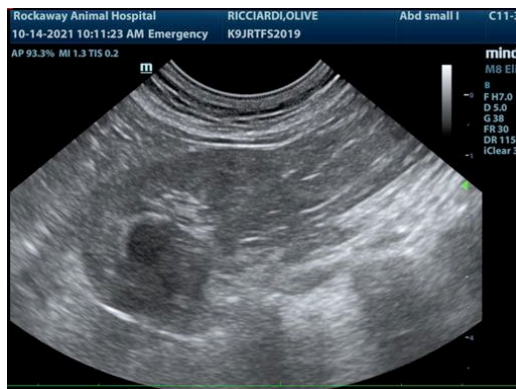
Dr. Maniar

INVOICE

92378

DATE

10/14/21





PATIENT

Olive Ricciardi

SPECIES

Canine

BREED

Jack Russell

SEX

Spayed Female

AGE

2 years

WEIGHT

16 lbs

INTERPRETED BY

Eric Lindquist, DMV
DABVP, Cert. IVUSS

IMAGING PERFORMED BY

Jenn

HOSPITAL NAME

Rockaway AH

REFERRING VET

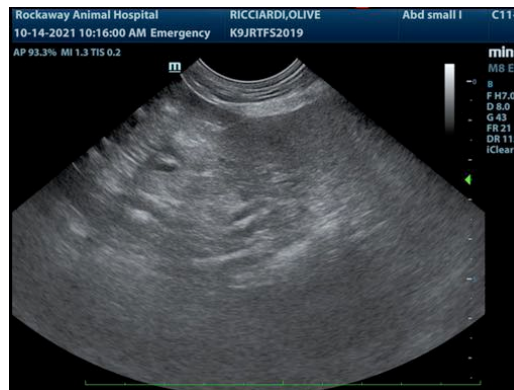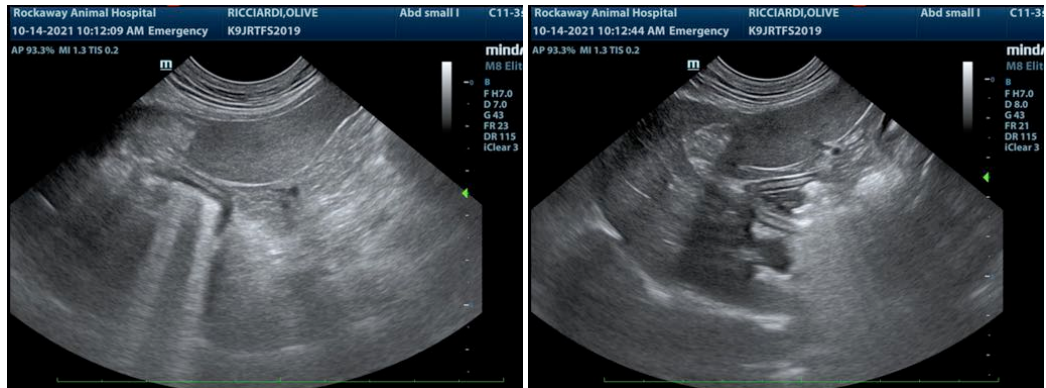
Dr. Maniar

INVOICE

92378

DATE

10/14/21



The information and recommendations provided are based on the images presented by the referring veterinarian. No evaluation can be communicated regarding pathology that was not visible in the image/video clips provided.

Thank you for this referral. If the clinical or image interpretation does not parallel your findings or if I can be of any further assistance please contact me.

Eric Lindquist, DMV, DABVP, Cert. IVUSS, CEO of SonoPath.com
info@SonoPath.com