



**PATIENT**

Cash Reisinger

**SPECIES**

Canine

**BREED**

Boxer

**SEX**

Neutered Male

**AGE**

10 Years

**WEIGHT**

43 kg

**INTERPRETED BY**

Eric Lindquist, DMV  
DABVP, Cert. IVUSS

**IMAGING PERFORMED BY**

Erin Wicks

**HOSPITAL NAME**

Shores VEC

**REFERRING VET**

Dr. Slenbaker

**INVOICE**

27284

**DATE**

10/14/21

**PRESENTING CLINICAL SIGNS**

Presented at our hospital for being diagnosed with pancreatitis at rDVM 3 days ago and p not improving since then. P has not had anything to eat in about 48 hours. Previous Health Concerns: pancreatitis about 4-5 years ago Current Medications: gabapentin (last given at 8a), Cerenia (last given at 5a), Forti flora and Pepcid (last given about 3 days ago) Appetite/When did they eat last: p has no appetite for the last 48 hours, last ate about 3 days

Abnormal PE/Chem/CBC/UA Results: Abdominal: mild tense cranial abdomen, cranial organomegaly but no obvious mass Owner declined radiographs at this time- no radiographs at rDVM rDVM bloodwork: WBC 22.5 H, PMN 19.3 H, BU N34 H, Sodium 141 H, Chloride 99 L, ALP 457 H, Amylase 7387 H, Lipase >1800 H, cPL 2,000 H Chemistry: BUN >140 H, Creat 3.1 H, Ph 13.2 H, Glucose 189 H, ALT 134 H, Alp 780 H, Lipase >1000 H EPOC: pH 7.291 L, Sodium 130 L, Potassium 5.1 H, chloride 100 L, Lactate 5.05 H, BUN 116 H, Creat 4.3 H, Glucose 185 H, HCT 40% N

**ULTRASONOGRAPHIC EXAMINATION OF THE ABDOMEN**

**Urinary System**

The **urinary bladder**, trigone, and pelvic urethra presented normal thicknesses and normal tone. The ureters were not visible which is normal. No uroliths or sediment were visualized and anechoic urine was present. No evidence of inflammatory or neoplastic changes were noted. Ureteral papillae were normal. The iliac trifurcation was unremarkable.

The **kidneys** were swollen with a pericapsular inflammatory pattern. Slight mineralization noted in both kidneys. The left kidney measured 7.64 cm. The right kidney measured 6.5 cm.

**Adrenal Glands**

The **adrenal glands** were not visualized.

**Spleen**

The **spleen** was volume contracted and mildly irregular.

**Liver**

The **liver** was mildly swollen. The gallbladder and common bile duct were unremarkable. Increased portal markings noted. The vena cava was dilated as were the hepatic veins, consistent with passive congestion, likely owing to the pericardial effusion and probable tamponade. The transdiaphragmatic view revealed pericardial effusion as well as ascites.

**Gastrointestinal**

Examination of the **gastrointestinal tract** revealed a stomach and intestine free of stasis, of normal wall thickness, acceptable curvilinear mural detail, and peristaltic activity. Small and large intestine demonstrated normal luminal chyme and stool consistency respectively. No obstructive or overt infiltrative disease was noted. No associated abnormal lymphatic activity was noted.

**Pancreas**

Mixed echogenic changes were noted around the **pancreas**, possibly owing to enhancement artifact.

**Free Abdomen**

Free fluid noted in the abdomen.



**PATIENT**

Cash Reisinger

**SPECIES**

Canine

**BREED**

Boxer

**SEX**

Neutered Male

**AGE**

10 Years

**WEIGHT**

43 kg

**INTERPRETED BY**

Eric Lindquist, DMV  
DABVP, Cert. IVUSS

**IMAGING PERFORMED BY**

Erin Wicks

**HOSPITAL NAME**

Shores VEC

**REFERRING VET**

Dr. Slenbaker

**INVOICE**

27284

**DATE**

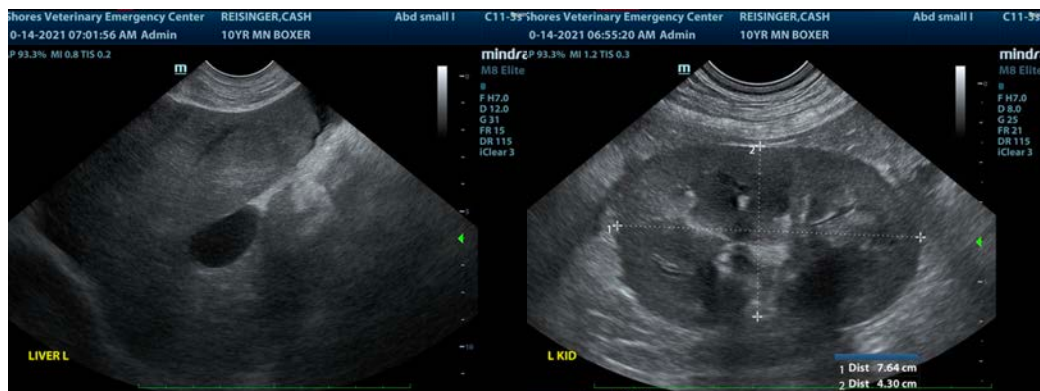
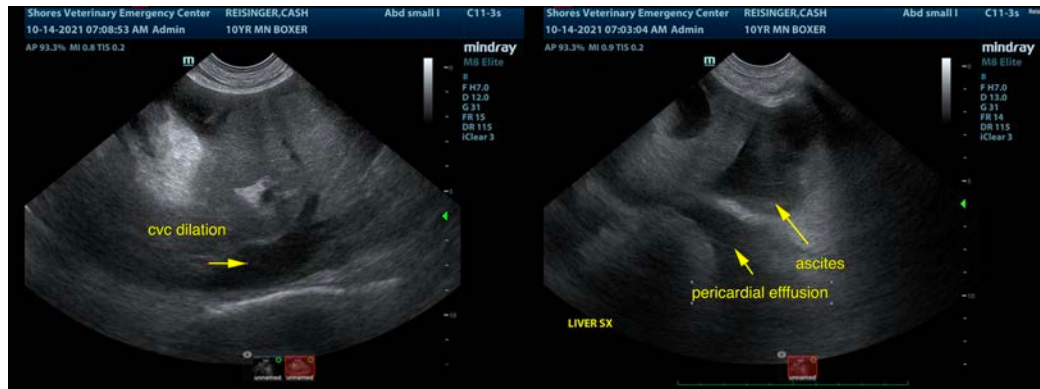
10/14/21

**ULTRASONOGRAPHIC FINDINGS**

- Passive congestion liver pattern
- Transdiaphragmatic visualization of pericardial effusion
- Concurrent nephritis pattern

**INTERPRETATION OF THE FINDINGS & FURTHER RECOMMENDATIONS**

Echocardiogram recommended to assess for causes of pericardial effusion such as neoplasia or idiopathic pericardial effusion, left atrial rupture. SDEP position #3 echo is essential in this case.



The information and recommendations provided are based on the images presented by the referring veterinarian. No evaluation can be communicated regarding pathology that was not visible in the image/video clips provided.

Thank you for this referral. If the clinical or image interpretation does not parallel your findings or if I can be of any further assistance please contact me.

**Eric Lindquist**, DMV, DABVP, Cert. IVUSS, CEO of SonoPath.com  
[info@SonoPath.com](mailto:info@SonoPath.com)