



PATIENT

Willow Flint

SPECIES

Feline

BREED

DSH

SEX

Spayed Female

AGE

6 Years

WEIGHT

11.3 Pounds

INTERPRETED BY

Eric Lindquist, DMV

DABVP, Cert. IVUSS

IMAGING PERFORMED BY

Dr. Susanne Bush

HOSPITAL NAME

Great Miami VC

REFERRING VET

Dr. Susanne Bush

PRESENTING CLINICAL SIGNS

Willow presented for routine wellness exam and her regular blood work showed an increase in the SDMA. She has not had urinary signs and has had no change in eating/drinking or behavior at home. Abnormal PE/Chem/CBC/UA Results: SDMA 22 U/A: proteinuria(100 mg/dL), hematuria (250/uL), USG 1.050

LIMITED ULTRASONOGRAPHIC EXAMINATION

The **urinary bladder**, trigone, and pelvic urethra presented normal thicknesses and normal tone. The ureters were not visible which is normal. No uroliths or sediment were visualized and anechoic urine was present. No evidence of inflammatory or neoplastic changes were noted. Ureteral papillae were normal.

The **right kidney** was mildly subnormal in size at 2.9 cm with loss of corticomedullary definition noted and irregular contour. Multifocal cortical infarcts noted. No evidence of active inflammation at the time of the sonogram.

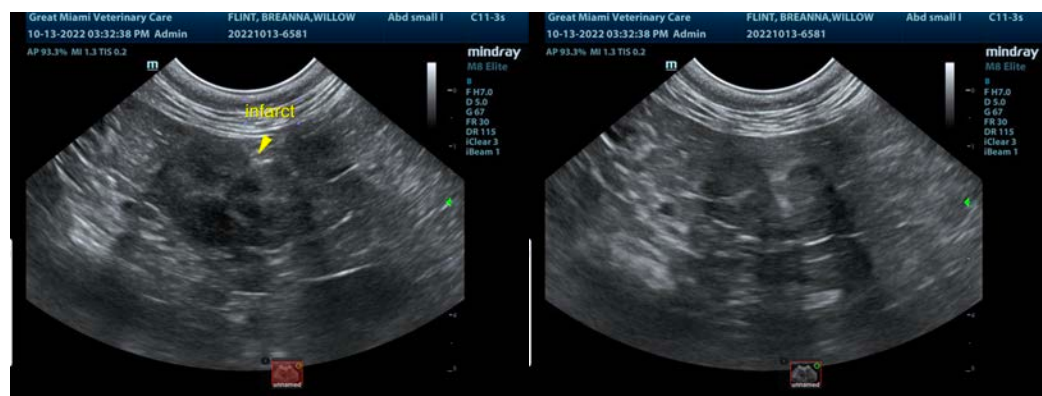
The **left kidney** presented normal size and contour, measuring 3.5 cm.

ULTRASONOGRAPHIC FINDINGS

- Normal lower urinary tract with infarcted right kidney – likely the source of underlying hematuria. No evidence of active inflammation. Concurrent idiopathic cystitis possible.

INTERPRETATION OF THE FINDINGS & FURTHER RECOMMENDATIONS

Palpation of the right kidney recommended to assess for any discomfort. Renal biopsy would be necessary for further definition. Underlying infectious or chronic infectious agents should be considered as well. However, the right kidney is most likely the cause of the clinical history. No evidence of calculi.



INVOICE

42070

DATE

10/13/22



PATIENT

Willow Flint

SPECIES

Feline

BREED

DSH

SEX

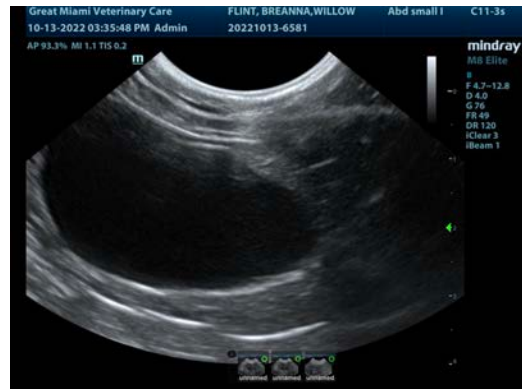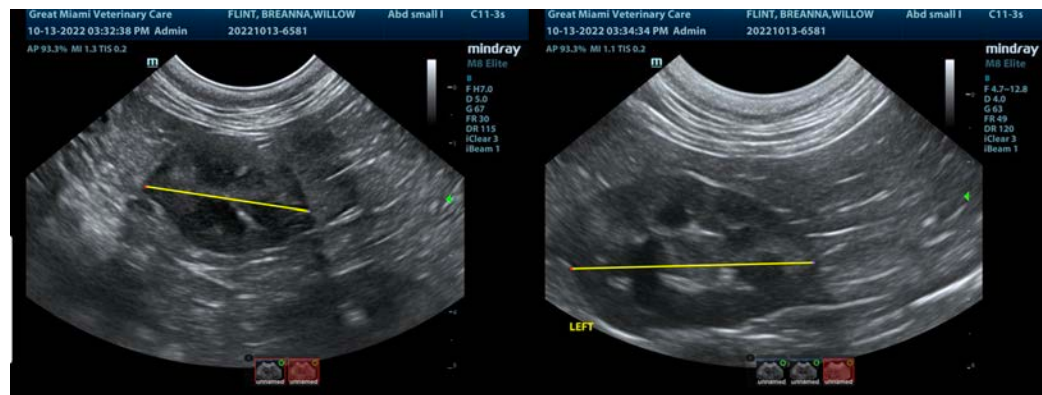
Spayed Female

AGE

6 Years

WEIGHT

11.3 Pounds



INTERPRETED BY

Eric Lindquist, DMV

DABVP, Cert. IVUSS

IMAGING PERFORMED BY

Dr. Susanne Bush

HOSPITAL NAME

Great Miami VC

REFERRING VET

Dr. Susanne Bush

INVOICE

42070

DATE

10/13/22

The information and recommendations provided are based on the images presented by the referring veterinarian/sonographer. No evaluation can be communicated regarding pathology that was not visible in the image/video clips provided.

Thank you for this referral. If the clinical or image interpretation does not parallel your findings or if I can be of any further assistance please contact me.

Eric Lindquist, DMV, DABVP, Cert. IVUSS, CEO of SonoPath.com

info@SonoPath.com