



PATIENT

Tessie Wollman

SPECIES

Canine

BREED

Poodle Mix

SEX

Spayed Female

AGE

13 Years

WEIGHT

8.4 kg

INTERPRETED BY

Eric Lindquist, DMV
DABVP, Cert. IVUSS

IMAGING PERFORMED BY

Jolee Stegemoller,
DVM

HOSPITAL NAME

North Idaho AH

REFERRING VET

Jolee Stegemoller,
DVM

INVOICE

17674

DATE

10/13/22

PRESENTING CLINICAL SIGNS

History: Presented October 11 for 2 brief episodes of panting heaving and pacing. Owner reports no pain when picking her up, no post-ictal signs, and no syncope. Bloodwork performed at another hospital in January 2022 and was unremarkable.

Abnormal PE/Chem/CBC/UA Results: Grade 3/6 left apical systolic murmur, arrhythmia was more pronounced on 10/11 versus today. BP 134/90. ECG pending.

ULTRASONOGRAPHIC EXAMINATION OF THE HEART

CANINE CARDIAC PARAMETERS	MR VMAX (m/s)	TR VMAX (m/s)	LA/AO (Boon method)	LA/AO (Heart Base; Swe)	FS (%)	EF (%)	EPSS (cm)
NORMAL PARAMETER	4.5-5.5	<2.7	1.3	<1.3	28-40	40-100	<0.6
PATIENT	--	1.5	1.3	1.0	45	--	0.2
CANINE CARDIAC PARAMETERS	HR (BPM)	AV VMAX (m/s)	PV MAX (m/s)	BODY WEIGHT (kg)	LA 2D short axis Base view (cm)	LVIDd Avg; 2D and m-mode short axis (cm)	LVIDs Avg; 2D and m-mode short axis (cm)
NORMAL PARAMETER	50-100	0.7-1.7	0.7-1.6				
PATIENT	--	--	.7	--	2.8	2.35	--

Cardiac Presentation

The echocardiogram in this patient demonstrated normal **left atrial** size based on 3 different LA measurement methods. Chamber volumes and echogenicity were normal. The cranial and caudal **mitral** valve leaflets presented vegetative thickening consistent with endocardiosis. Doppler indicated measurable insufficiency yet underestimated. The **left ventricle** presented thicknesses with linear contour and was not dilated nor restricted. The **myocardium** presented normal echogenicity without subjective evidence of significant fibrotic or ischemic disease. **Contractility** of the ventricular walls was adequate and in normal range for this patient evidenced by the fractional shortening measurement and subjective evaluation of the different regions of the myocardium. The **left ventricular outflow** tract demonstrated normal laminar flow and subjective structural integrity. The **right atrium** and auricle revealed normal size, structure and content. No evidence of masses was noted or chamber overload. Tricuspid insufficiency was noted. The **right ventricle** was of normal size (1/3 diameter of LV), chordae structure, myocardial echogenicity and thickness. **Pulmonic** tract assessment revealed normal valve structure, laminar flow, and diameter (approx.1:1 pa/ao ratio). No visible **pericardial** or free pleura fluid was noted. No echographically detectable evidence of infiltrative disease was visible. The cranial **mediastinum and pericardial regions** were free of masses in the visible window.

ULTRASONOGRAPHIC FINDINGS



PATIENT

Tessie Wollman

- Stage B-1 valvular disease, compensated at this time
- Minor mitral insufficiency, fairly trivial- best visualized in the apical position
- Tricuspid insufficiency

SPECIES

Canine

BREED

Poodle Mix

SEX

Spayed Female

AGE

13 Years

WEIGHT

8.4 kg

INTERPRETED BY

Eric Lindquist, DMV
DABVP, Cert. IVUSS

IMAGING PERFORMED BY

Jolee Stegemoller,
DVM

HOSPITAL NAME

North Idaho AH

REFERRING VET

Jolee Stegemoller,
DVM

INVOICE

17674

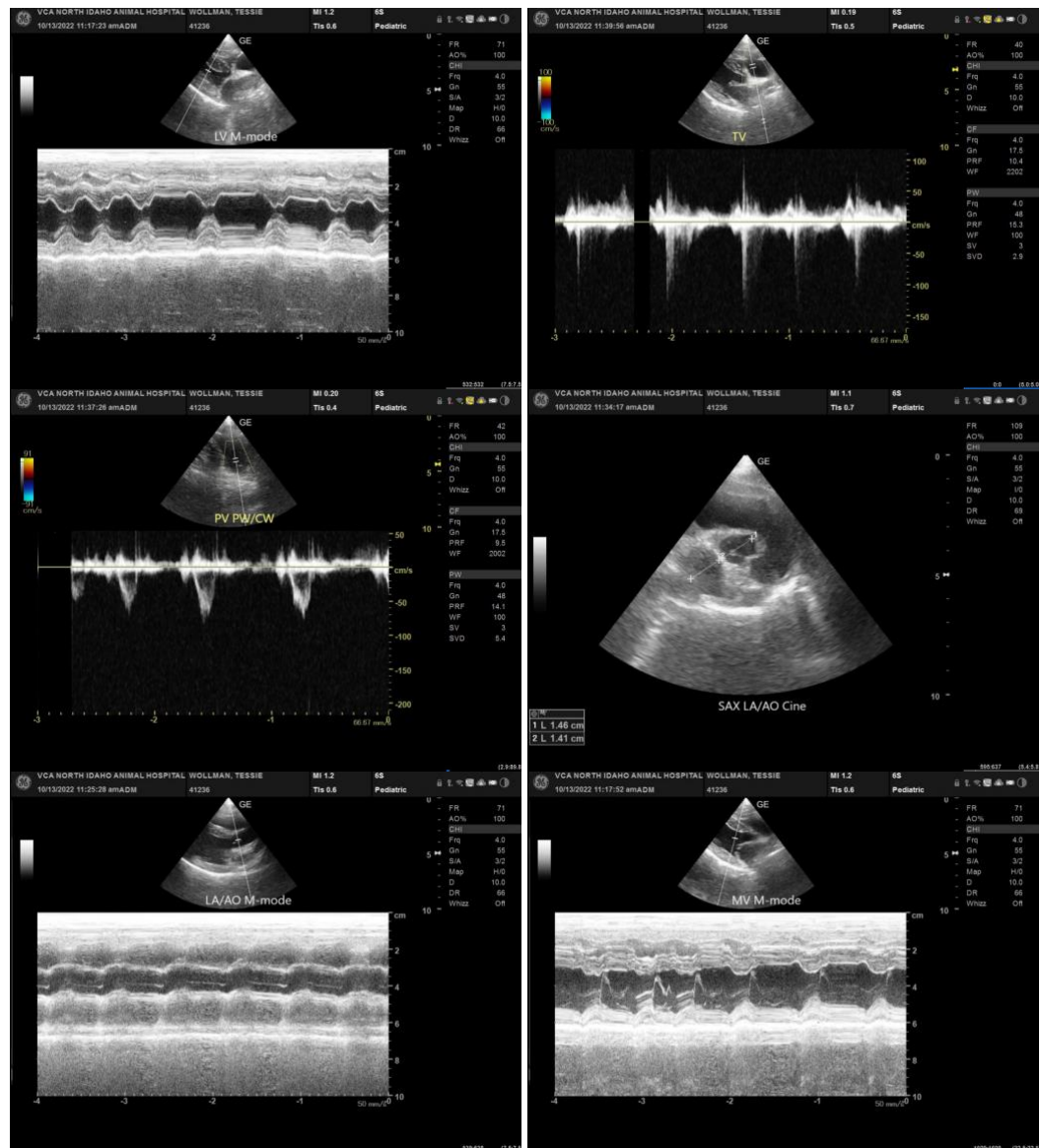
DATE

10/13/22

INTERPRETATION OF THE FINDINGS & FURTHER RECOMMENDATIONS

The heart is stable without clinical disease. No overt contraindication for anesthesia of brief to moderate duration. I suggest Torbutrol premed, Propofol induction, Isoflor maintenance or similar protocol if anesthesia is desired. Blood pressure recommended if not already performed and target white coat negative systolic pressure of < 160 mmHg. If higher than this ACE-inhibitor is suggested to reach this level. Recheck echocardiogram is recommended in 6 months, earlier if murmur grade increases or clinical signs initiate.

No evidence of clinical cardiac disease was noted at this time.





PATIENT

Tessie Wollman

SPECIES

Canine

BREED

Poodle Mix

SEX

Spayed Female

AGE

13 Years

WEIGHT

8.4 kg

INTERPRETED BY

Eric Lindquist, DMV
DABVP, Cert. IVUSS

IMAGING PERFORMED BY

Jolee Stegemoller,
DVM

HOSPITAL NAME

North Idaho AH

REFERRING VET

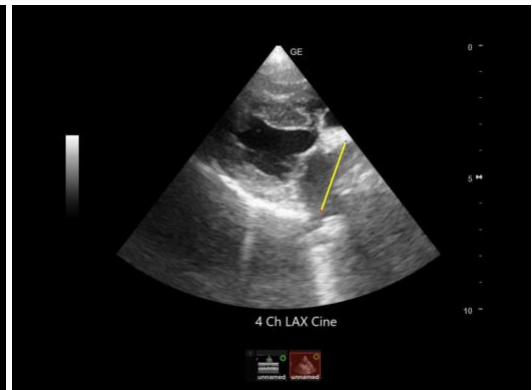
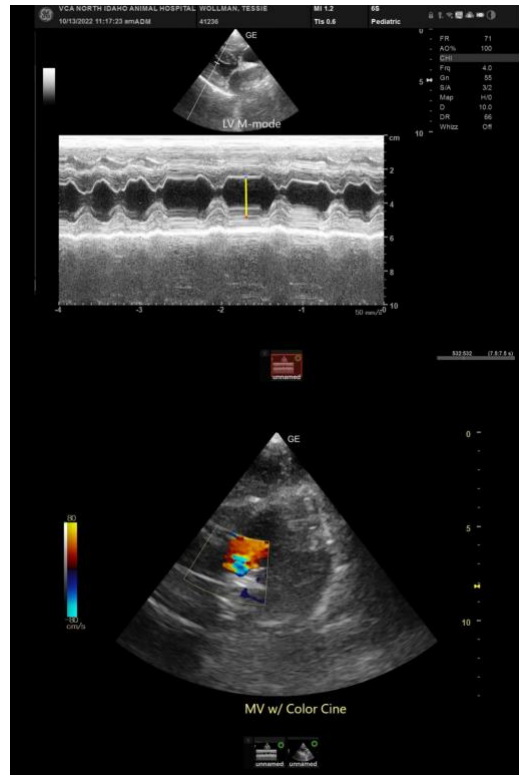
Jolee Stegemoller,
DVM

INVOICE

17674

DATE

10/13/22



The information and recommendations provided are based on the images presented by the referring veterinarian. No evaluation can be communicated regarding pathology that was not visible in the image/video clips provided.

Thank you for this referral. If the clinical or image interpretation does not parallel your findings or if I can be of any further assistance please contact me.

Eric Lindquist, DMV, DABVP, Cert. IVUSS, CEO of SonoPath.com
info@SonoPath.com