



PATIENT PRESENTING CLINICAL SIGNS

Maggie Martin

History: Owner adopted through rescue/puppy mill. A murmur was not noted on puppy exams. I first saw this patient 9/23/22 and noted a grade 2 murmur loudest on left lateral chest wall. Owner has noted increased panting

SPECIES

Canine

Abnormal PE/Chem/CBC/UA Results: Grade 2/6 murmur CBC: WNL CHEM: WNL SDMA: 15 T4: 3.0 Rads/EKG: were submitted to idexx cardiology and VHS and EKG wnl

BREED

King Charles Cavalier Poodle

ULTRASONOGRAPHIC EXAMINATION OF THE HEART

The echocardiogram in this patient demonstrated normal **left atrial** size based on 3 separate methods of LA evaluation. The **mitral and tricuspid** valves revealed normal laminar flow. There was no evidence of congenital disease. Structural integrity of all valvular apparatuses appear normal. There is no evidence of ventricular septal defect or other significant congenital lesion. However, spectral and color flow Doppler of the left ventricular outflow tract and right ventricular outflow tract are necessary. However, structural and functional heart appeared normal.

AGE

1 year

WEIGHT

14 lbs

CANINE CARDIAC PARAMETERS	MR VMAX (m/s)	TR VMAX (m/s)	LA/AO (Boon method)	LA/AO (Heart Base; Swe)	FS (%)	EF (%)	EPSS (cm)
NORMAL PARAMETER	4.5-5.5	<2.7	1.3	<1.6	28-40	40-100	<0.6
PATIENT			1.15	1.3	30	80	0.1
CANINE CARDIAC PARAMETERS	HR (BPM)	AV VMAX (m/s)	PV MAX (m/s)	BODY WEIGHT (kg)	LA (2D short axis Base view) (cm)	LVIDd (Avg; 2D and m-mode short axis) (cm)	LVIDs (Avg; 2D and m-mode short axis) (cm)
NORMAL PARAMETER	50-100	0.7-1.7	0.7-1.6	BELOW	BELOW	BELOW	BELOW
PATIENT						2.27	

INTERPRETED BY

Eric Lindquist, DMV DABVP, Cert. IVUSS

IMAGING PERFORMED BY

Dr. Griffin

HOSPITAL NAME

Norhtside VC

ULTRASONOGRAPHIC FINDINGS

Structurally normal heart.

REFERRING VET

Dr. Griffin

INTERPRETATION OF THE FINDINGS & FURTHER RECOMMENDATIONS

INVOICE

40085

The cause of the murmur is not evident. Further spectral and color flow Doppler assessment of the LVOT and RVOT is recommended.

DATE

10/13/22



PATIENT

Maggie Martin

SPECIES

Canine

BREED

King Charles Cavalier Poodle

SEX

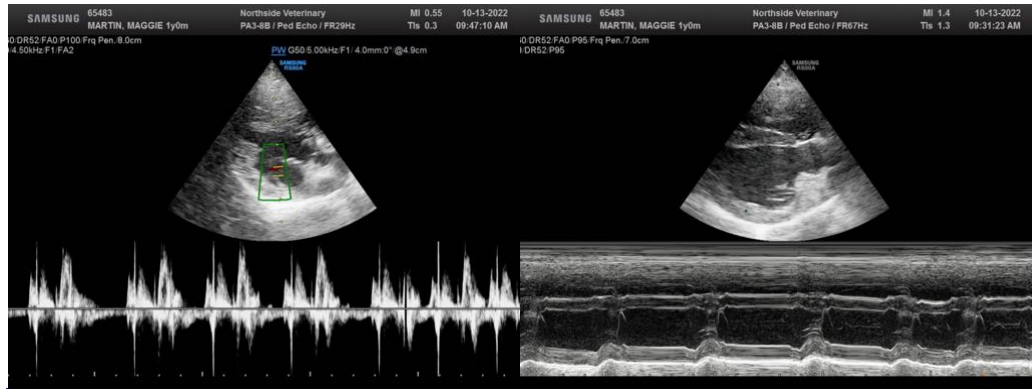
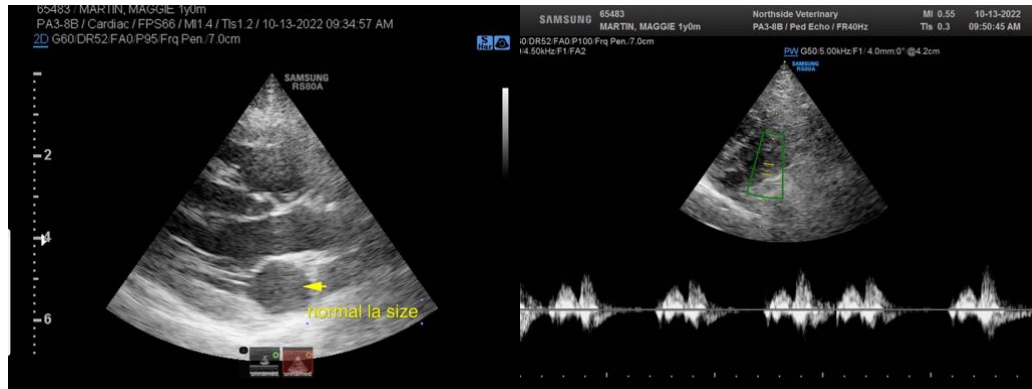
Spayed female

AGE

1 year

WEIGHT

14 lbs



INTERPRETED BY

Eric Lindquist, DMV
DABVP, Cert. IVUSS

The information and recommendations provided are based on the images presented by the referring veterinarian/sonographer. No evaluation can be communicated regarding pathology that was not visible in the image/video clips provided.

IMAGING PERFORMED BY

Dr. Griffin

Thank you for this referral. If the clinical or image interpretation does not parallel your findings or if I can be of any further assistance please contact me.

HOSPITAL NAME

Norhtside VC

Eric Lindquist, DMV, DABVP, Cert. IVUSS, CEO of SonoPath.com
info@SonoPath.com

REFERRING VET

Dr. Griffin

INVOICE

40085

DATE

10/13/22