


PATIENT

Hedwig Pal

PRESENTING CLINICAL SIGNS

Hedwig is a 10 year old CKC spaniel male with a history of hear murmur and CHF and is on pimo and fortekor and sos furosemeide , very stable dental is required , owner is very scared about anesthesia , he breaths quite heavy when stressed , ultrasound images are affected by this

SPECIES

Canine

ULTRASONOGRAPHIC EXAMINATION OF THE HEART
BREED

Cavalier King Charles

SEX

Neutered Male

AGE

10 Years

WEIGHT

17 kg

CANINE CARDIAC PARAMETERS	MR VMAX (m/s)	TR VMAX (m/s)	LA/AO (Boon method)	LA/AO (Heart Base; Swe)	FS (%)	EF (%)	EPSS (cm)
NORMAL PARAMETER	4.5-5.5	<2.7	1.3	<1.6	28-40	40-100	<0.6
PATIENT			1.15	--	35	80	0.1
CANINE CARDIAC PARAMETERS	HR (BPM)	AV VMAX (m/s)	PV MAX (m/s)	BODY WEIGHT (kg)	LA 2D short axis Base view (cm)	LVIDd Avg; 2D and m-mode short axis (cm)	LVIDs Avg; 2D and m-mode short axis (cm)
NORMAL PARAMETER	50-100	0.7-1.7	0.7-1.6	BELOW	BELOW	BELOW	BELOW
PATIENT	90	--	--		3.16	3.78	

INTERPRETED BY

Eric Lindquist, DMV

DABVP, Cert. IVUSS

IMAGING PERFORMED BY

Dr. Samad Khan

HOSPITAL NAME

The Veterinary Surgery

REFERRING VET

Dr. Samad Khan

Cardiac Presentation

The cardiac presentation revealed minor volume overload of the left ventricle, yet left atrial size was normal. The mitral valve was thickened, insufficiency likely the cause of the heart murmur. The right atrium and right ventricle were unremarkable. The tricuspid valve was mildly thickened. No pericardial or pleural effusion noted. Contractility appeared to adequate.

ULTRASONOGRAPHIC FINDINGS

- Compensated mitral insufficiency

INTERPRETATION OF THE FINDINGS & FURTHER RECOMMENDATIONS

There is minor anesthetic risk in this patient. Suggested protocol includes the following: Torbutrol pre-med, Propofol induction, Isoflurane maintenance. However, BUN, creatinine, blood pressures, sleeping respiratory rate should all be evaluated. SRR should be <25/min. Chest radiographs also recommended if not already performed. Recheck echo in 3-6 months. Right and left ventricular outflow velocities would be ideal.

INVOICE

42058

DATE

10/13/22



PATIENT

Hedwig Pal

SPECIES

Canine

BREED

Cavalier King Charles

SEX

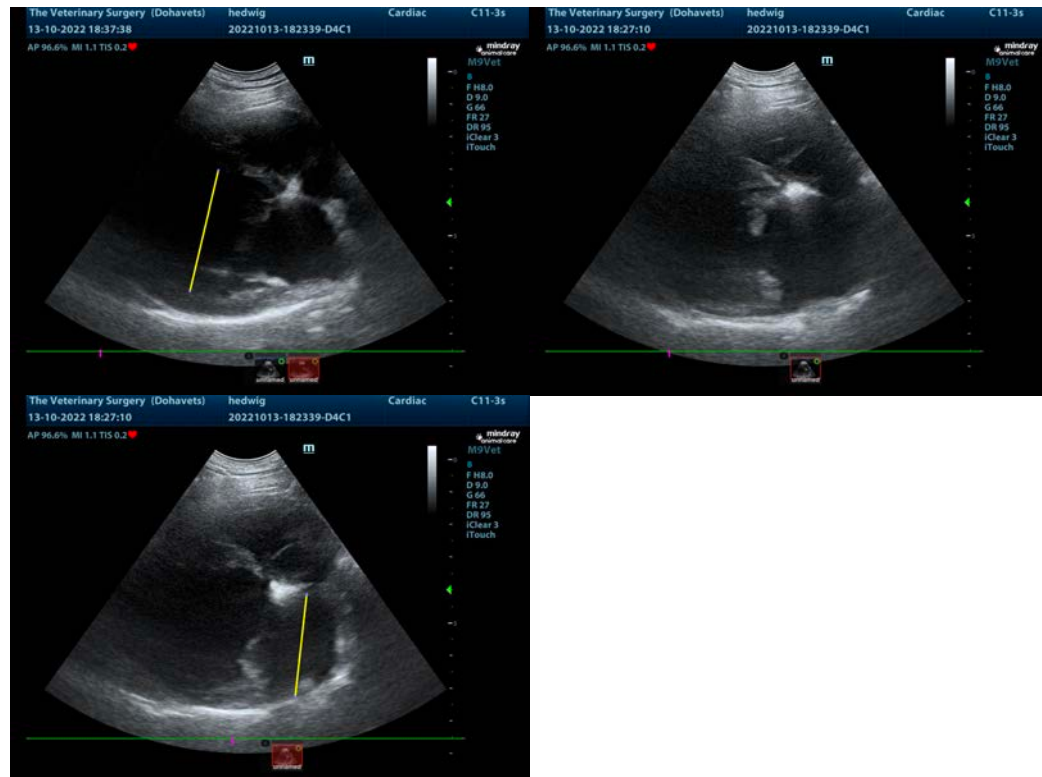
Neutered Male

AGE

10 Years

WEIGHT

17 kg



INTERPRETED BY

Eric Lindquist, DMV
DABVP, Cert. IVUSS

IMAGING PERFORMED BY

Dr. Samad Khan

HOSPITAL NAME

The Veterinary Surgery

REFERRING VET

Dr. Samad Khan

INVOICE

42058

DATE

10/13/22

The information and recommendations provided are based on the images presented by the referring veterinarian/sonographer. No evaluation can be communicated regarding pathology that was not visible in the image/video clips provided.

Thank you for this referral. If the clinical or image interpretation does not parallel your findings or if I can be of any further assistance please contact me.

Eric Lindquist, DMV, DABVP, Cert. IVUSS, CEO of SonoPath.com

info@SonoPath.com