



PATIENT

Sophie McGlynn

PRESENTING CLINICAL SIGNS

History: Mast cell tumor

SPECIES

Canine

BREED

Mix

SEX

Spayed Female

AGE

11 years

WEIGHT

57.5 lbs

INTERPRETED BY

Eric Lindquist, DMV
DABVP, Cert. IVUSS

IMAGING PERFORMED BY

Jenn

HOSPITAL NAME

Rockaway AH

REFERRING VET

Dr. Maniar

INVOICE

92360

DATE

10/13/21

ULTRASONOGRAPHIC EXAMINATION OF THE ABDOMEN

Urinary System

The **urinary bladder**, trigone, and pelvic urethra presented normal thicknesses and normal tone. The ureters were not visible which is normal. No uroliths or sediment were visualized and anechoic urine was present. No evidence of inflammatory or neoplastic changes was noted. Ureteral papillae were normal.

The **kidneys** revealed normal size and structure, corticomedullary definition and ratio for this age. The cortices presented largely uniform texture with normal echogenic relationship to liver and spleen. Medullary structure differed distinctly from the cortex and no evidence of pelvic dilation was present. The capsules were acceptably uniform without significant irregularities. The left kidney measured 6.24 cm.

Adrenal Glands

Both **adrenal glands** were visualized and recognized as having normal shape, size, position and echogenicity for this breed. The phrenic vasculature, glandular echogenicity and detail were unremarkable. Capsule, cortex, and medullary definition were normal for this age patient. The left adrenal gland measured 1.55 x 0.59 cm at the caudal pole and 0.44 cm at the cranial pole.

Spleen

The **spleen** was largely smooth with subtle heterogeneous parenchymal changes while maintaining normal echogenic relationship to the liver and kidney. These changes are consistent with normal age-related alteration. The capsule was smooth without noticeable impingement from within the spleen or from pathology in the adjacent abdomen. The splenic vasculature demonstrated normal volume without signs of congestion or significant contraction. No evidence of active acute or chronic inflammatory, neoplastic, or infarctual changes was noted.

Liver

The **liver** was enlarged with slightly disruptive nodular changes and increased portal markings. Generalized hepatomegaly was noted. The gallbladder was mildly over distended with suspended and dependent debris, yet not to the level of emerging mucocele. However, the sludge appears to be mildly excessive. No adjunctive inflammation was noted.



PATIENT

Gastrointestinal

Sophie McGlynn

Examination of the **gastrointestinal tract** revealed a stomach and intestine free of stasis, of normal wall thickness, acceptable curvilinear mural detail, and peristaltic activity. Small and large intestine demonstrated normal luminal chyme and stool consistency respectively. No obstructive or overt infiltrative disease was noted. No associated abnormal lymphatic activity was noted.

SPECIES

Canine

BREED

Mix

SEX

Spayed Female

Pancreas

The base and limbs of the **pancreas** were observed to be largely isoechoic to surrounding omental fat. Some parenchymal remodeling, however, with mild deviation from curvilinear normalcy was observed. Pancreatic duct and capsular irregularities were present consistent with age related changes. If pain upon imaging (+ Murphy sign) was present or if the patient is focally painful in subxiphoid palpation then low-grade smoldering chronic pancreatitis should be suspected.

AGE

11 years

ULTRASONOGRAPHIC FINDINGS

Vacuolar hepatopathy with remodeling.

Otherwise, geriatric abdomen.

WEIGHT

57.5 lbs

INTERPRETATION OF THE FINDINGS & FURTHER RECOMMENDATIONS

FNA of the liver is warranted especially if the liver enzymes are present. There was no overt evidence of lesions consistent with mast cell disease.

INTERPRETED BY

Eric Lindquist, DMV
DABVP, Cert. IVUSS

IMAGING PERFORMED BY

Jenn

HOSPITAL NAME

Rockaway AH

REFERRING VET

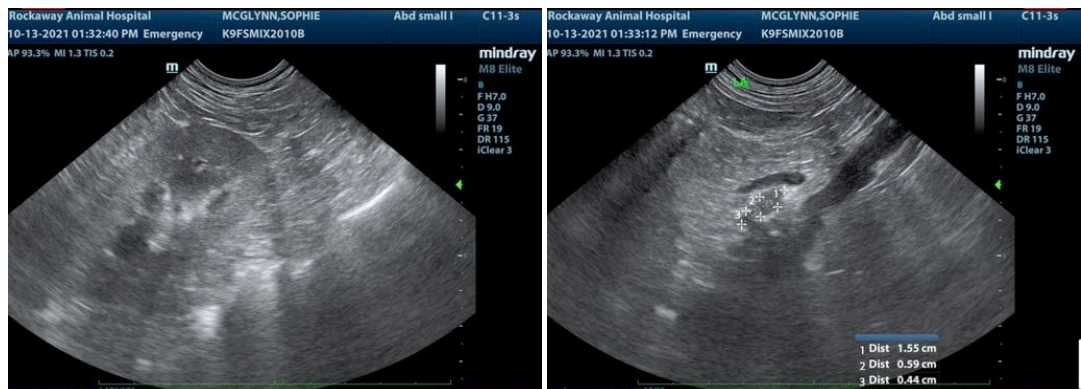
Dr. Maniar

INVOICE

92360

DATE

10/13/21





PATIENT

Sophie McGlynn

SPECIES

Canine

BREED

Mix

SEX

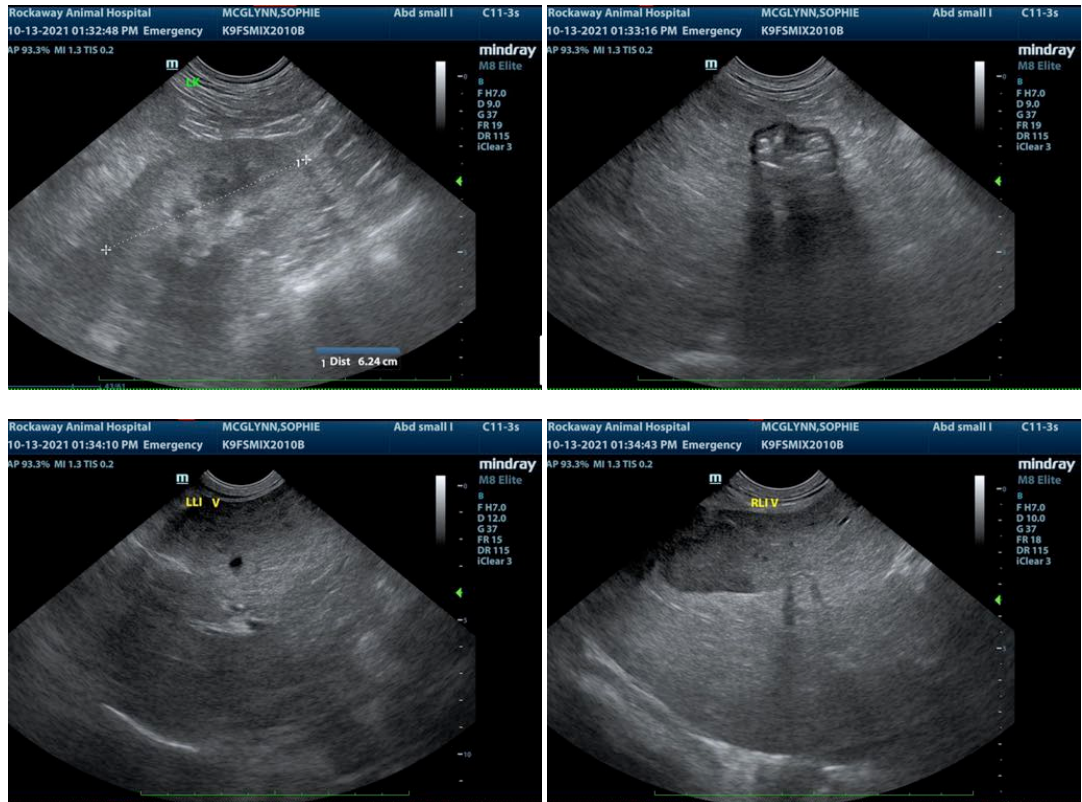
Spayed Female

AGE

11 years

WEIGHT

57.5 lbs



INTERPRETED BY

Eric Lindquist, DMV
DABVP, Cert. IVUSS

IMAGING PERFORMED BY

Jenn

HOSPITAL NAME

Rockaway AH

REFERRING VET

Dr. Maniar

INVOICE

92360

DATE

10/13/21

The information and recommendations provided are based on the images presented by the referring veterinarian. No evaluation can be communicated regarding pathology that was not visible in the image/video clips provided.

Thank you for this referral. If the clinical or image interpretation does not parallel your findings or if I can be of any further assistance please contact me.

Eric Lindquist, DMV, DABVP, Cert. IVUSS, CEO of SonoPath.com
info@SonoPath.com