



PATIENT

Wednesday George

SPECIES

Feline

BREED

DSH

SEX

Spayed Female

AGE

7 Years

WEIGHT

5.2 Pounds

PRESENTING CLINICAL SIGNS

Anorexic, ataxic, azotemic, heart murmur. Current meds: IVF, Unasyn iv.
 Abnormal PE/Chem/CBC/UA Results: BUN >140, Crea >24, Phos >15, K+ 6.2 (4.6H), wbc 32.13 (19.5H), Neu 30.55 (12.58H), USG 1.016, Prot 3+, Bld 2+, Cocci 2+

ULTRASONOGRAPHIC EXAMINATION OF THE HEART & ABDOMEN

| FELINE CARDIAC PARAMETERS | BODY WEIGHT (kg) | HR (BPM) | IVSd (cm) | LVIDd (cm) | LVWd (cm) | FS (%) | EF (%) |
|------------------------------------------------------------------------------------------------------------------------------------------|------------------|---------------------------|--------------------------------------------------|-----------------|-----------------|-----------|--------|
| NORMAL PARAMETER | ----- | 150-240 | 0.3-0.6 | 1.0-2.1 | 0.25-0.6 | 35-67 | 80-100 |
| PATIENT | | 168 | 0.56 | 0.79 | 0.61 | 49 | 85 |
| FELINE CARDIAC PARAMETERS | LA/AO (Boon) | LA/AO HEART BASE (Sisson) | LA 2D 4-chamber long axis AS to FW (Sisson) (cm) | LVOT VEL. (m/s) | RVOT VEL. (m/s) | IVRT (m/) | |
| NORMAL PARAMETER | <1.5 | 0.88-1.79 | 0.7-1.7 | <1.6 | <1.3 | 40-60 | |
| PATIENT | 1.3 | 1.29 | 1.1 | | 0.85 | NM | |
| Adapted from June Boon, Veterinary Echocardiography, 1998 Sisson D et al. JVIM 1991; 5: 232, Jacobs et al. Am J Vet Res 1985; 46:1705 | | | | | | | |

INTERPRETED BY

Eric Lindquist, DMV
 DABVP, Cert. IVUSS

IMAGING PERFORMED BY

Shari Reffi, CVT

HOSPITAL NAME

Newton Vet Hospital

REFERRING VET

Dr. Chun

INVOICE

26226

DATE

10/13/21

Cardiac Presentation

The echocardiogram in this patient demonstrated normal **left atrial** size based on 3 separate LA measurements. Trivial **mitral** insufficiency, not clinically significant. The **left ventricle** presented normal thicknesses with linear contour and was not dilated nor restricted. The **myocardium** presented normal echogenicity without subjective evidence of significant fibrotic or ischemic disease. **Contractility** of the ventricular walls was adequate and in normal range for this patient evidenced by the fractional shortening measurement and subjective evaluation of the different regions and angles of the myocardium. The **left ventricular outflow** tract demonstrated normal laminar flow and subjective structural integrity. The **right atrium** and auricle revealed normal size, structure and content. No evidence of masses was noted or chamber overload. Trivial **tricuspid** insufficiency noted. The **right ventricle** was of normal size (1/3 diameter of LV), chordae structure, myocardial echogenicity and thickness. **Pulmonic** tract assessment revealed normal valve structure, laminar flow, and diameter (approx. 1:1 pa/ao ratio). No visible **pericardial** or free pleura fluid was noted or extra cardiac pathology in the visible planes. The cranial **mediastinum and pericardial regions** were free of masses in the visible window.

Urinary System

The **urinary bladder** revealed multifocal small, non-shadowing concretions and debris. The patient may have passed calculi recently, causing the immediate crisis. The pelvic urethra was imaged 2.0 cm beyond the cystourethral junction. A slight amount of sand was present.

The **kidneys** presented a relatively uniform cortical hyperechogenicity when compared to the renal medulla, spleen and liver. No overt masses were noted. The ureters were not visible and assumed to be normal. These changes are most consistent with chronic interstitial nephritis yet infiltrative disease could not be entirely ruled out without biopsy though neoplasia is not suspected. Pelvic calculi noted



PATIENT

Wednesday George

and loss of corticomedullary definition noted. The right kidney measured 3.46 cm. The left kidney measured 3.36 cm. Poor blood flow to the kidneys noted, yet may be owing to hypovolemia.

Adrenal Glands

SPECIES

Feline

Both **adrenal glands** were visualized and recognized as having normal shape, size, position and echogenicity for this breed. The phrenic vasculature, glandular echogenicity and detail were unremarkable. Capsule, cortex, and medullary definition were normal for this age patient. The right adrenal gland measured 0.39 cm. The left adrenal gland measured 0.32 cm.

BREED

DSH

Spleen

The **spleen** in this patient was uniform, yet volume contracted. Hydration status should be assessed.

SEX

Spayed Female

Liver

The **liver** images submitted revealed subjectively normal liver size, contour, and structure. Parenchymal echogenicity was naturally coarse and hypoechoic to the spleen. Vascular and biliary tracts were of normal volume with no evidence of congestion. The gallbladder presented acceptably thin walls with primarily anechoic content. The cystic and common bile ducts were normal. No pathological hepatic lymphadenopathy was evident. No overt structural evidence of inflammatory, infiltrative or regenerative pathology was evident.

AGE

7 Years

Gastrointestinal

WEIGHT

5.2 Pounds

Examination of the **gastrointestinal tract** revealed a stomach and intestine free of stasis, of normal wall thickness, acceptable curvilinear mural detail, and peristaltic activity. Small and large intestine demonstrated normal luminal chyme and stool consistency respectively. No obstructive or overt infiltrative disease was noted. No associated abnormal lymphatic activity was noted.

INTERPRETED BY

Eric Lindquist, DMV
DABVP, Cert. IVUSS

Pancreas

The base and limbs of the **pancreas** were observed to be largely isoechoic to surrounding omental fat. Pancreatic duct and capsular contour were acceptably normal and parenchyma respected normal curvilinear patterns. No overt evidence of active inflammatory or neoplastic disease was noted.

IMAGING PERFORMED BY

Shari Reffi, CVT

ULTRASONOGRAPHIC FINDINGS

- Normal echocardiogram with trivial mitral and tricuspid insufficiency, not clinically significant
- Acute on chronic renal failure – possible history of passage of small calculi/sand
- Volume contracted spleen

HOSPITAL NAME

Newton Vet Hospital

INTERPRETATION OF THE FINDINGS & FURTHER RECOMMENDATIONS

72-hour aggressive IV fluid protocol recommended. Hydration should be assessed in this patient. No contraindication to fluid therapy regarding the echocardiogram. Prognosis is guarded. Causes of acute insult should be investigated such as toxin exposure or infectious disease. However, small calculi passage may have been an issue, as there is a large amount of debris in the bladder, likely inflammatory in origin. Urine culture and sensitivity indicated as well as blood pressure. Suspect that the patient may be hypotensive.

REFERRING VET

Dr. Chun

INVOICE

26226

DATE

10/13/21



PATIENT

Wednesday George

SPECIES

Feline

BREED

DSH

SEX

Spayed Female

AGE

7 Years

WEIGHT

5.2 Pounds

INTERPRETED BY

Eric Lindquist, DMV
DABVP, Cert. IVUSS

IMAGING PERFORMED BY

Shari Reffi, CVT

HOSPITAL NAME

Newton Vet Hospital

REFERRING VET

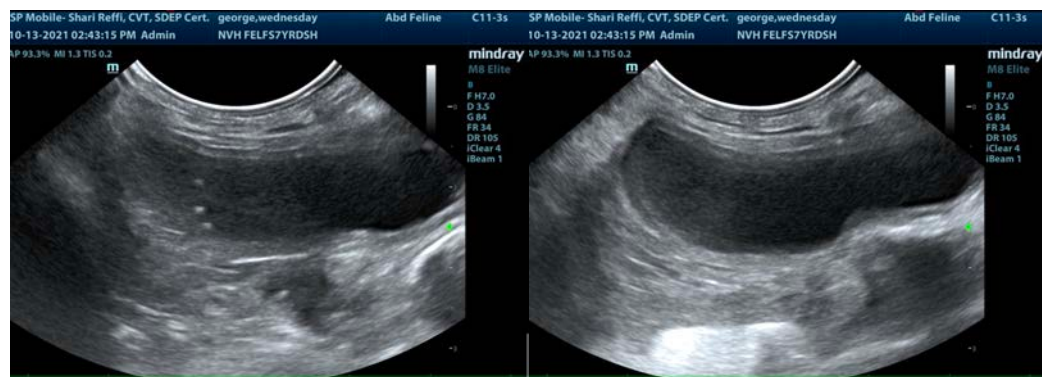
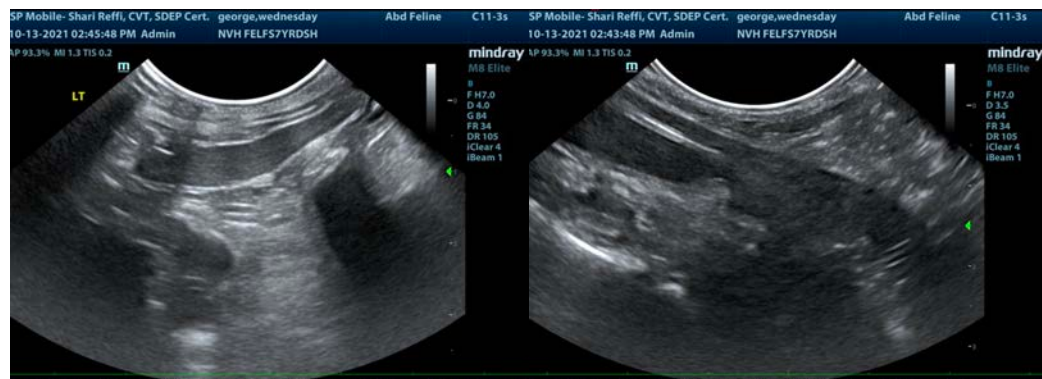
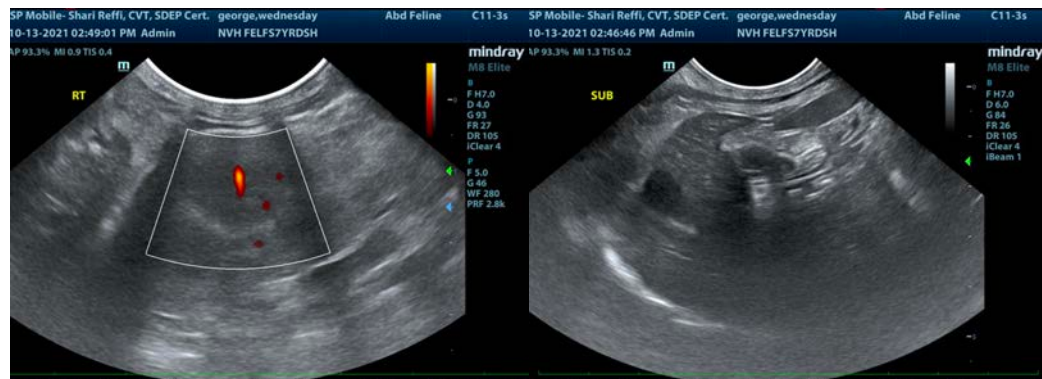
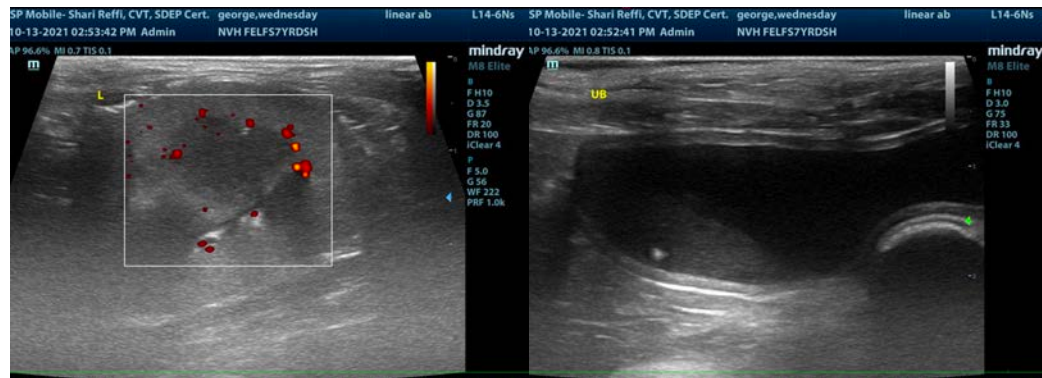
Dr. Chun

INVOICE

26226

DATE

10/13/21





PATIENT

Wednesday George

SPECIES

Feline

BREED

DSH

SEX

Spayed Female

AGE

7 Years

WEIGHT

5.2 Pounds

INTERPRETED BY

Eric Lindquist, DMV
DABVP, Cert. IVUSS

IMAGING PERFORMED BY

Shari Reffi, CVT

HOSPITAL NAME

Newton Vet Hospital

REFERRING VET

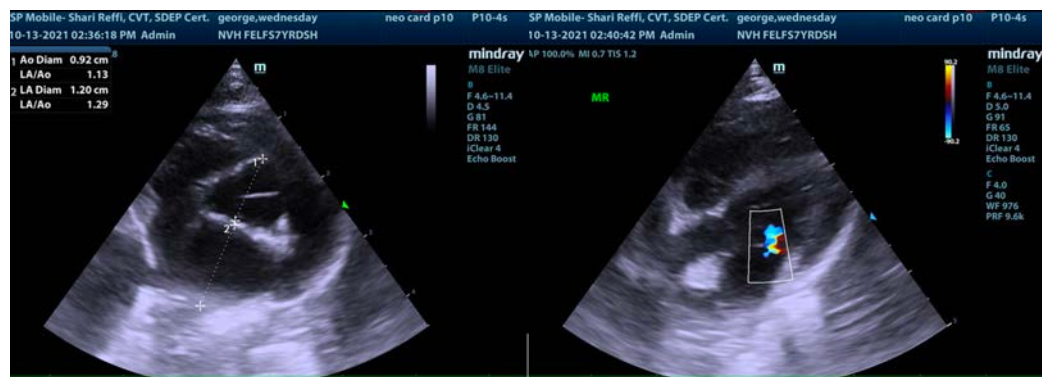
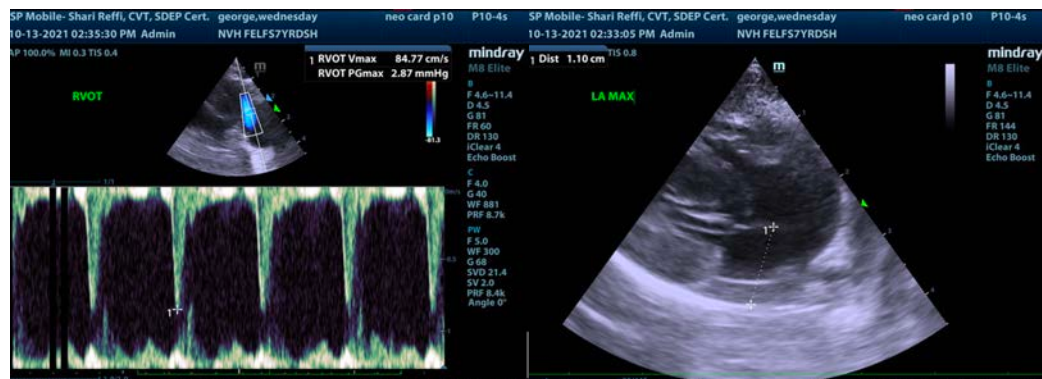
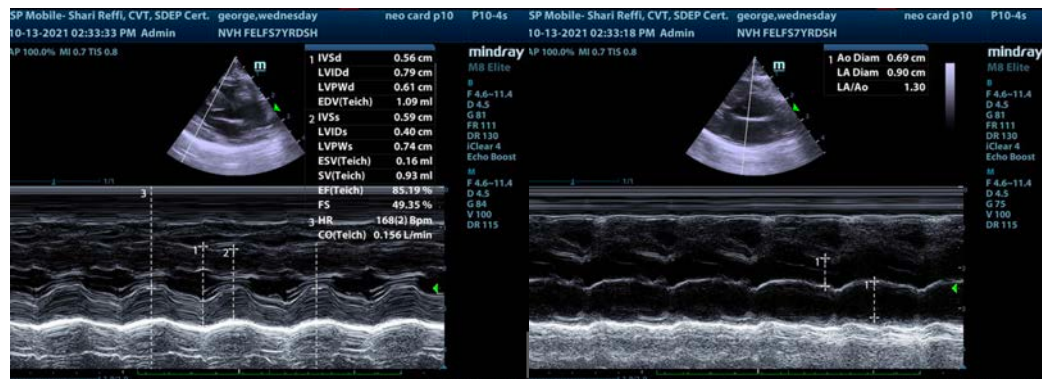
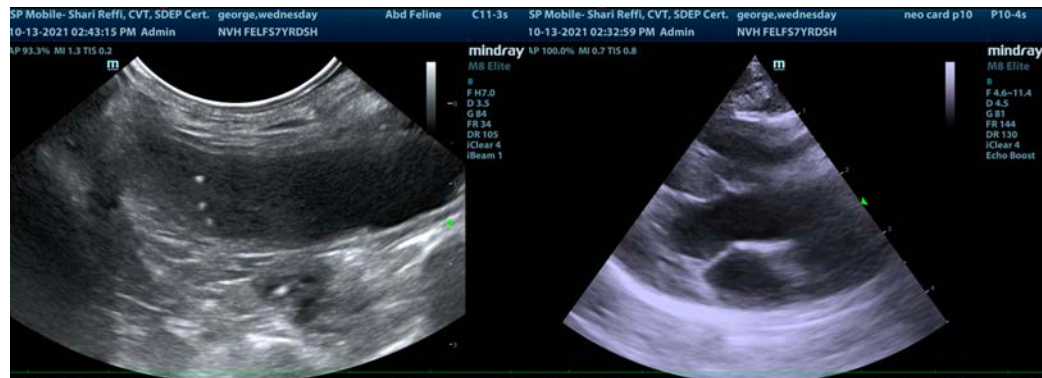
Dr. Chun

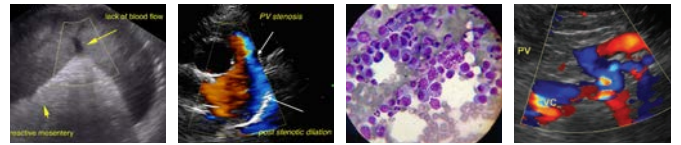
INVOICE

26226

DATE

10/13/21





PATIENT

Wednesday George

SPECIES

Feline

BREED

DSH

SEX

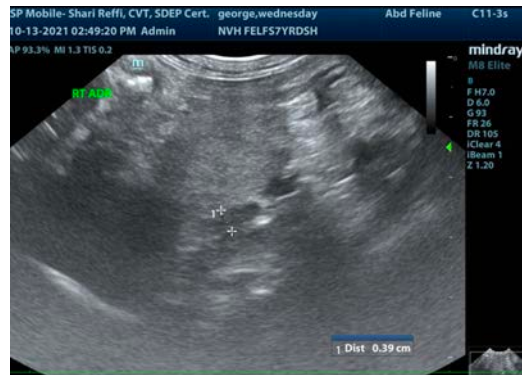
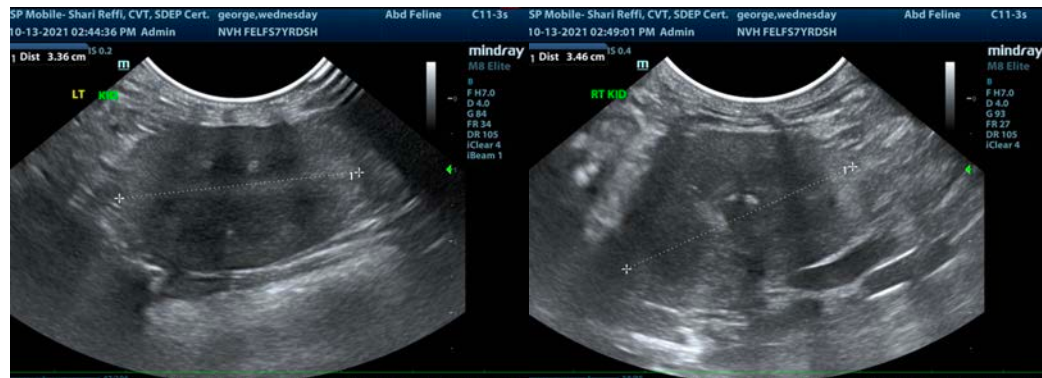
Spayed Female

AGE

7 Years

WEIGHT

5.2 Pounds



INTERPRETED BY

Eric Lindquist, DMV
DABVP, Cert. IVUSS

IMAGING PERFORMED BY

Shari Reffi, CVT

HOSPITAL NAME

Newton Vet Hospital

REFERRING VET

Dr. Chun

INVOICE

26226


DATE

10/13/21

The information and recommendations provided are based on the images presented by the referring veterinarian. No evaluation can be communicated regarding pathology that was not visible in the image/video clips provided.

Thank you for this referral. If the clinical or image interpretation does not parallel your findings or if I can be of any further assistance please contact me.

Eric Lindquist, DMV, DABVP, Cert. IVUSS, CEO of SonoPath.com
info@SonoPath.com



The following is an applicable excerpt from the *Curbside Guide to Diagnosis & Treatment of Sonographic Disease* offered by SonoPath.com Lindquist, Frank, Lobetti, and Modler.

An essential quick guide for every general practitioner and sonographer.

<https://sonopath.com/products/curbside-guide-editing-due-release-12012015>

Acute Renal Failure

<http://www.sonopath.com/ARF>



PATIENT

Wednesday George

SPECIES

Feline

BREED

DSH

SEX

Spayed Female

AGE

7 Years

WEIGHT

5.2 Pounds

INTERPRETED BY

Eric Lindquist, DMV
DABVP, Cert. IVUSS

IMAGING PERFORMED BY

Shari Reffi, CVT

HOSPITAL NAME

Newton Vet Hospital

REFERRING VET

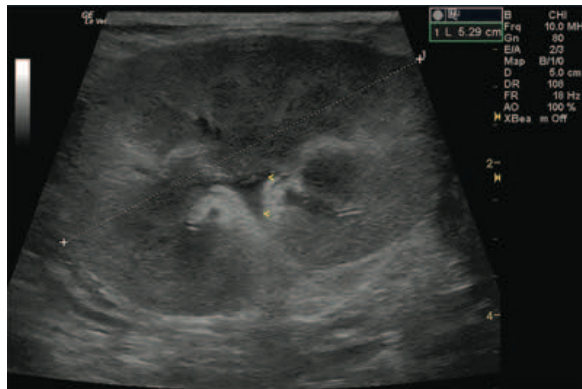Dr. Chun

INVOICE

26226

DATE

10/13/21



Long axis of the kidney in a cat with a renal transplant and acute renal failure. Note the generalized swelling of the kidney with loss of corticomedullary definition. The renal pelvis shows mild dilation with anechoic content (arrow heads). The renal crest and sinus are hyperechoic.

Description: Acute renal failure (ARF)—also referred to as acute kidney injury—is defined as a rapid deterioration in renal function that results in the accumulation of metabolic waste in the body. It is characterized by an impaired regulation of water and solute balances, and may be due to prerenal, postrenal, and/or primary renal causes. Prerenal azotemia reflects a reduced glomerular filtration rate (GFR), which is a consequence of renal hypoperfusion; it is not the result of structural renal damage. Immediate restoration of renal blood flow will reverse the azotemia over a period of time; however, if the hypoperfusion is severe or prolonged, or if there is prior renal dysfunction, acute primary renal failure due to ischemic acute tubular necrosis will be induced. Postrenal azotemia occurs when urine flow is obstructed or the excretory pathway is ruptured and there is subsequent urine resorption. Persistent urinary obstruction may cause irreversible renal damage. Early detection of postrenal azotemia will result in complete restoration of renal function. Acute tubular necrosis accounts for the majority of acute primary renal failure cases and is characterized by an abrupt and sustained reduction in GFR due to an ischemic or toxic renal insult. The conditions that incite ischemia are the same as those for prerenal azotemia; however, the duration of the ischemia is important. Nephrotoxins are a frequent cause of tubular necrosis. The high rates of blood flow and metabolic activity in the kidneys as well as their excretory function predispose dogs and cats to the toxic effects of drugs as well as endogenous or exogenous toxins.

Clinical Signs: The clinical course in acute tubular necrosis can be divided into three phases: an initiating phase, a maintenance phase, and a recovery phase. The initiating phase, which is marked by the onset of renal injury, is the period in which there is the greatest potential for preventing or reversing tubular damage and the progression to overt renal failure because it is during this period that renal cell damage develops. The challenge, however, is that the initiating phase may only become evident in retrospect as it generally lacks characteristic signs. The maintenance phase is characterized by the onset of oliguria (i.e., urine production is less than 1ml/kg/hour). The onset of this phase typically occurs during the first 24 hours, but may be delayed for up to 1 week. The duration of this phase is highly variable, but usually persists for up to 2 weeks. It is characterized by: fluid and electrolyte imbalances, including an alteration in hydration; hyponatremia; hyperkalemia; high anion gap metabolic acidosis; hypocalcemia; hyperphosphatemia; and azotemia. Clinical signs include gastrointestinal, hematological, and neurological manifestations of renal failure. The recovery phase commences when the GFR increases, which consequently slows down and reverses the azotemia. There is a progressive increase in urine volume, and although the tubular function begins to improve, it nevertheless remains impaired. Diuresis persists because of the diminished ability of the tubules to reabsorb sodium and respond to vasopressin. Clinical manifestations observed in the maintenance phase persist into the recovery phase. In some patients, infections and/or gastrointestinal bleeding may occur. Sites of infection include the respiratory



PATIENT

Wednesday George

tract, operative sites, and the urinary tract. Septicemia may also occur and is sometimes the result of intravenous and urinary indwelling catheters.

SPECIES

Feline

Diagnostics: Extraordinary disorders that produce prerenal azotemia are associated with concentrated, hypersthenuric urine, which contains a relatively low concentration of sodium and high concentration of creatinine. ARF is typically characterized by enlarged or swollen kidneys, elevated hematocrit, and azotemia. Urine is isosthenuric or minimally concentrated, and contains high concentrations of creatinine. Proteinuria or glycosuria may also accompany this condition. The sediment will show casts and RTE cells. Proteinuria or glycosuria may also accompany this condition. The sediment will show casts and RTE cells. Complete anuria is usually associated with postrenal azotemia. Features that are typical for acute tubular necrosis include: anuria in the absence of a urinary tract obstruction or rupture; severe proteinuria; significant hematuria with red cell casts; and prolonged oliguria. In these cases, a diagnostic renal biopsy is indicated.

BREED

DSH

SEX

Spayed Female

AGE

7 Years

Treatment: Most patients with ARF are volume depleted. Fluid therapy is indicated to correct dehydration, which will restore adequate renal perfusion and may prevent further renal damage. If the etiology was prerenal in origin, then urine volume will increase. In the maintenance phase, fluid therapy should be directed toward maintaining fluid balance and preventing both overhydration and dehydration. In cases of renal disease it is important that only maintenance needs and ongoing losses are attended to as overhydration can develop if there is reduced renal function. Insensible losses are calculated at 20 ml/kg/day. Aggressive fluid therapy during the recovery phase may perpetuate polyuria. As the urine volume stabilizes, the volume of fluid administered should be reduced correspondingly. Because dehydration may occur during this phase, one should monitor body weight and clinically assess the hydration status as fluid therapy is being reduced. Oliguric patients who are unresponsive to fluid volume replacement can be treated with mannitol, furosemide, and/or dopamine in an attempt to increase GFR and urine volume. Hyperkalemia is commonly associated with the maintenance phase of ARF. Concentrations greater than 6 mmol/l may require treatment with sodium bicarbonate, dextrose, insulin and/or calcium gluconate. Hemodialysis should be considered in patients with severe, persistent uremia, acidosis, or hyperkalemia. It may also be used to treat overhydration and hasten the elimination of nephrotoxins.

WEIGHT

5.2 Pounds

INTERPRETED BY

Eric Lindquist, DMV
DABVP, Cert. IVUSS

IMAGING PERFORMED BY

Shari Reffi, CVT

HOSPITAL NAME

Newton Vet Hospital

REFERRING VET

Dr. Chun

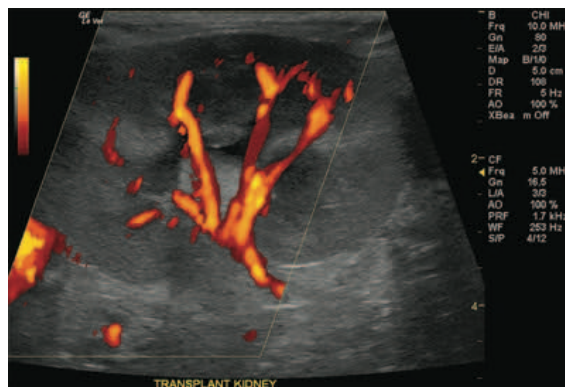Conclusion: Because ARF is frequently iatrogenic and associated with nephrotoxic drugs or inadequate fluid therapy, prevention is the best therapy.

INVOICE

26226

DATE

10/13/21



Long axis of the kidney of the same cat as in the previous title image. Note the non-uniform power Doppler signal distribution with significant hypovascularity of the cranial pole compatible with regional infarction and transplant failure.



PATIENT

Wednesday George

SPECIES

Feline

BREED

DSH

SEX

Spayed Female

AGE

7 Years

WEIGHT

5.2 Pounds

INTERPRETED BY

Eric Lindquist, DMV
DABVP, Cert. IVUSS

**IMAGING
PERFORMED BY**

Shari Reffi, CVT

HOSPITAL NAME

Newton Vet Hospital

REFERRING VET

Dr. Chun

INVOICE

26226

DATE

10/13/21

References:

Acierno MJ, Maeckelbergh V. Continuous renal replacement therapy. *Compend Contin Educ Vet* 2008;30:264-72.

Grauer GF. Early detection of renal damage and disease in dogs and cats. *Vet Clin North Am Small Anim Pract* 2005;35:581-96.

Labato MA. Strategies for management of acute renal failure. *Vet Clin North Am Small Anim Pract* 2001;31:1265-87.

Ross L. Acute kidney injury in dogs and cats. *Vet Clin North Am Small Anim Pract* 2011;41:1-14.