



PATIENT

Sadie Glowaski

SPECIES

Canine

BREED

American Eskimo X

SEX

Spayed Female

AGE

10 Years

WEIGHT

13.6 kg

INTERPRETED BY

Eric Lindquist, DMV
DABVP, Cert. IVUSS

IMAGING PERFORMED BY

Dr. Belan

HOSPITAL NAME

McKnight 24-Hour

REFERRING VET

Dr. Gruffydd

INVOICE

13695

DATE

10/12/21

PRESENTING CLINICAL SIGNS

History: Vomiting diarrhea lethargy and cranial abdominal pain Patient on methadone for pain control
Abnormal PE/Chem/CBC/UA Results: Mod elevation liver enzymes severe elevation of amylase lipase

ULTRASONOGRAPHIC EXAMINATION OF THE ABDOMEN

Urinary System

The **urinary bladder** was structurally unremarkable, however, did reveal a 1.08 cm non-obstructive calculus The pelvic urethra was unremarkable.

The **kidneys** revealed largely normal size and structure, corticomedullary definition and ratio (cortex 1/3 of medulla) were essentially maintained with some age-related loss of curvilinear patterns regarding the capsule and C/M junction. The cortices presented largely uniform texture with some increased echogenicity expected for his age patient. Medullary structure differed distinctly from that of the cortex and no evidence of pelvic dilation was present. Mineralization was noted in the kidneys. The right kidney measured 5.6 cm. The left kidney measured 5.0 cm.

Adrenal Glands

Both **adrenal glands** were visualized and recognized as having normal shape, size, position and echogenicity for this breed. The phrenic vasculature, glandular echogenicity and detail were unremarkable. Capsule, cortex, and medullary definition were normal for this age patient. The left adrenal gland measured 0.53 cm at maximum width. The right adrenal gland measured 0.6 cm at maximum width.

Spleen

The **spleen** was largely smooth with subtle heterogeneous parenchymal changes while maintaining normal echogenic relationship to the liver and kidney. These changes are consistent with mild normal age-related alteration. The capsule was smooth without noticeable impingement from within the spleen or from pathology in the adjacent abdomen. The splenic vasculature demonstrated normal volume without signs of congestion or significant contraction. No evidence of active acute or chronic inflammatory, neoplastic, or infarctual changes were noted.

Liver

The **liver** revealed multifocal hypoechoic nodular changes with an overt hyperechoic mass (2.3 cm). Increased portal markings were noted throughout the liver with various nodular changes.

The **gallbladder** was mildly over distended with suspended and dependent debris, yet not to the level of emerging mucocele, yet sludge appears to be mildly excessive. No adjunctive inflammation was noted.

Gastrointestinal

The **upper gastrointestinal** tract revealed variable thickening and edematous wall. Soft stool was noted in the colon. No evidence of foreign body or gastrointestinal neoplasia.

Pancreas



PATIENT

Sadie Glowaski

The **pancreas** revealed extensive mixed hypoechoic parenchymal changes with hyperechoic surrounding fat extending for a region of approximately 4.0 cm. Areas of negative color flow uptake noted throughout the pancreas suggestive for pancreatic necrosis. Ultrasound guided FNA of the pancreas would be ideal.

SPECIES

Canine

Free Abdomen

The mesenteric **lymph node** (up to 0.62 cm) presented normal length to width ratio with slight, swollen contour. There was no loss of parenchymal detail. This is most consistent with reactive lymphadenitis or lymphatic hyperplasia.

BREED

American Eskimo X

ULTRASONOGRAPHIC FINDINGS

SEX

Spayed Female

- Extensive right limb pancreatitis, pancreatic neoplasia possible
- Hepatic neoplasia suspected yet may be low grade. Low grade carcinoma possible
- Age-related renal changes with mineralization
- Bladder calculus, non-obstructive
- Age-related splenic changes
- Upper gastrointestinal tract, variable thickening and edematous wall with soft stool in the colon

AGE

10 Years

INTERPRETATION OF THE FINDINGS & FURTHER RECOMMENDATIONS

WEIGHT

13.6 kg

FNA of the hypoechoic portion of the pancreas from the right approach. SDEP 14 or 15 approach would be appropriate. FNA of the general liver and liver mass recommended as well. Aggressive treatment for pancreatitis warranted in this patient with plasma expanders, broad spectrum antibiotics and pain management. Plasma transfusion would be ideal. Recheck sonogram in 72 hours. Guarded prognosis.

INTERPRETED BY

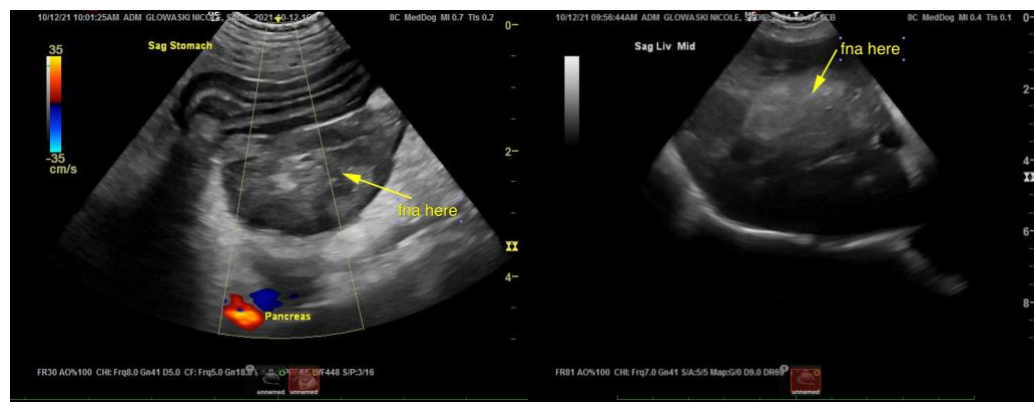
Eric Lindquist, DMV
DABVP, Cert. IVUSS

IMAGING PERFORMED BY

Dr. Belan

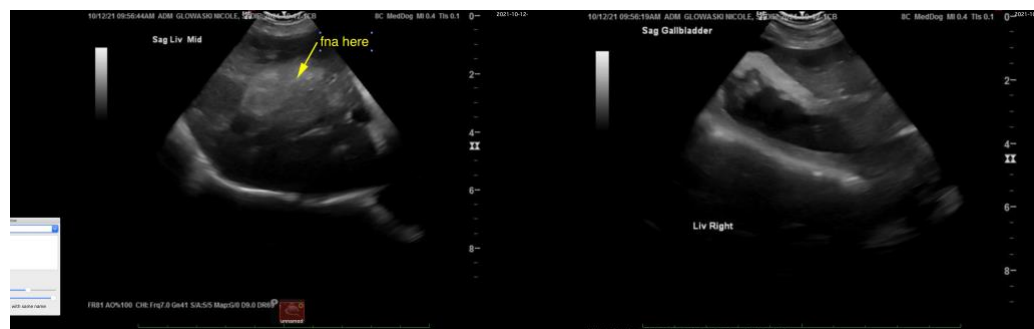HOSPITAL NAME

McKnight 24-Hour



REFERRING VET

Dr. Gruffydd



INVOICE

13695

DATE

10/12/21



PATIENT

Sadie Glowaski

SPECIES

Canine

BREED

American Eskimo X

SEX

Spayed Female

AGE

10 Years

WEIGHT

13.6 kg

INTERPRETED BY

Eric Lindquist, DMV
DABVP, Cert. IVUSS

IMAGING PERFORMED BY

Dr. Belan

HOSPITAL NAME

McKnight 24-Hour

REFERRING VET

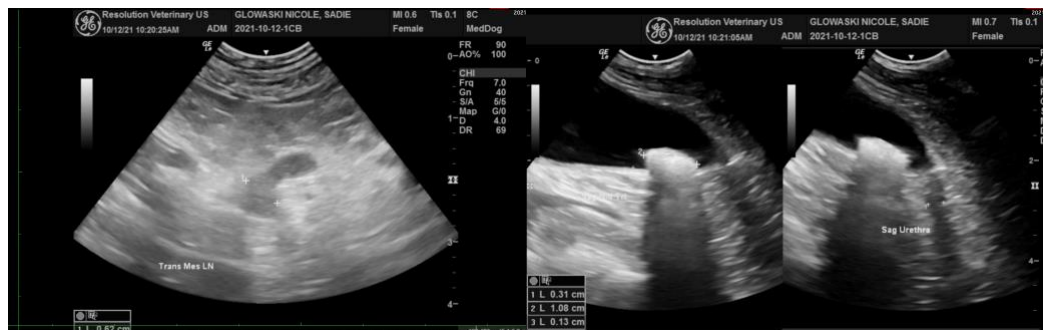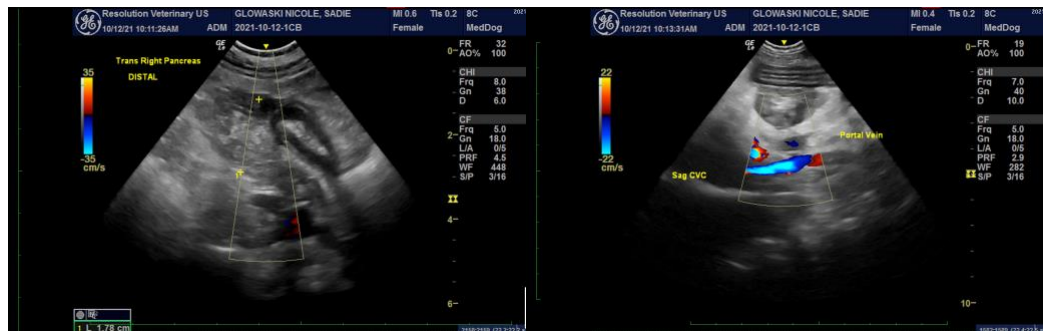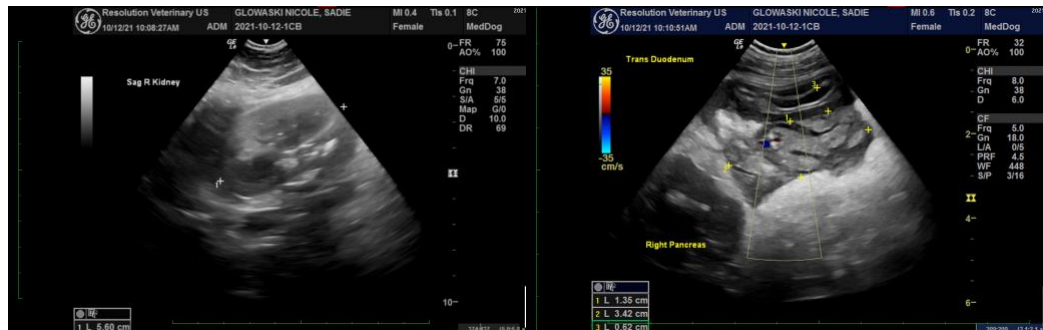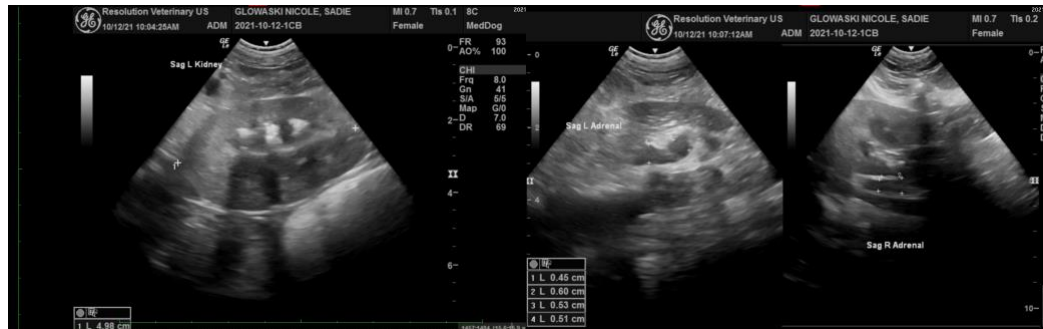Dr. Gruffydd

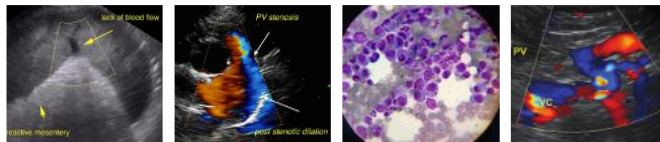
INVOICE

13695

DATE

10/12/21





PATIENT

Sadie Glowaski

SPECIES

Canine

BREED

American Eskimo X

SEX

Spayed Female

AGE

10 Years

WEIGHT

13.6 kg

INTERPRETED BY

Eric Lindquist, DMV
DABVP, Cert. IVUSS

IMAGING PERFORMED BY

Dr. Belan

HOSPITAL NAME

McKnight 24-Hour

REFERRING VET

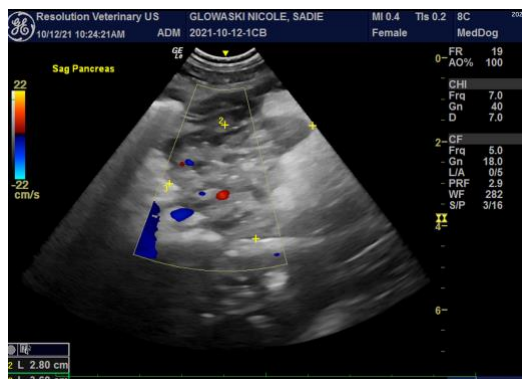
Dr. Gruffydd

INVOICE

13695

DATE

10/12/21



The information and recommendations provided are based on the images presented by the referring veterinarian. No evaluation can be communicated regarding pathology that was not visible in the image/video clips provided.

Thank you for this referral. If the clinical or image interpretation does not parallel your findings or if I can be of any further assistance please contact me.

Eric Lindquist, DMV, DABVP, Cert. IVUSS, CEO of SonoPath.com
info@SonoPath.com