



**PATIENT**

June McCartney

**SPECIES**

Feline

**BREED**

DMH

**SEX**

Spayed Female

**AGE**

13 Years

**WEIGHT**

3.3 kg

**INTERPRETED BY**

Eric Lindquist, DMV  
DABVP, Cert. IVUSS

**IMAGING PERFORMED BY**

Anna Wepprich

**HOSPITAL NAME**

Wilvet Salem

**REFERRING VET**

Brittany Gardener

**INVOICE**

13702

**DATE**

10-12-21

**PRESENTING CLINICAL SIGNS**

History: Weight loss and vomiting over last 24 hours fever

Abnormal PE/Chem/CBC/UA Results: leukocytosis, Crea 3.3 (was normal in June 2021) rDVM UA- casts and dilute USG suspect pyelonephritis

**ULTRASONOGRAPHIC EXAMINATION OF THE ABDOMEN**

**Urinary System**

The **urinary bladder**, trigone, and pelvic urethra presented normal thicknesses and normal tone. The ureters were not visible which is normal. No uroliths or sediment were visualized and anechoic urine was present. No evidence of inflammatory or neoplastic changes were noted. Ureteral papillae were normal.

The **kidneys** revealed largely normal size and structure, corticomedullary definition and ratio (cortex 1/3 of medulla) were essentially maintained with some minor age-related loss of curvilinear patterns regarding the capsule and C/M junction. The cortices presented largely uniform texture with some increased echogenicity expected for his age patient. Medullary structure differed distinctly from that of the cortex. The right kidney measured 3.5 cm. The left kidney measured 2.5 cm. Slight pyelectasia was noted in both kidneys.

**Adrenal Glands**

Both **adrenal glands** were visualized and recognized as having normal shape, size, position and echogenicity for this breed. The phrenic vasculature, glandular echogenicity and detail were unremarkable. Capsule, cortex, and medullary definition were normal for this age patient. The left adrenal gland measured 0.5 cm. The right adrenal gland measured 0.4 cm.

**Spleen**

The **spleen** presented a smooth homogeneous parenchyma hyperechoic to liver and renal cortical parenchyma. The capsule was smooth without noticeable expansion or deviation from within the spleen or adjacent pathology. The splenic vasculature demonstrated normal volume without signs of congestion or thrombosis. No sonographic evidence of acute or chronic inflammatory, neoplastic, or infarctual changes were noted.

**Liver**

The **liver** images from right and left intercostal as well as subcostal views revealed subjectively normal liver size, contour, and structure. Some minor age-related parenchymal remodeling was noted but likely not clinically significant at this time. Vascular and biliary tracts were of normal volume and no evidence of congestion was noted. The gallbladder presented some dependent debris with essentially normal contour. The cystic and common bile ducts were normal. No overt evidence of active inflammatory, infiltrative or regenerative pathology was noted but should be paired with current or past LE elevations regarding any clinical significance to this presentation. The hepatic lymph nodes were unremarkable.

**Gastrointestinal**

The **gastrointestinal tract** revealed minor variable thickening and minor echogenic submucosal changes most consistent with low grade end result of chronic GI disease such as IBD and may be



**PATIENT**

June McCartney

related to malassimilation of nutrients if any weight loss is present. No obvious neoplastic patterns were noted and luminal content as unremarkable.

**SPECIES**

Feline

**Pancreas**

The base and limbs of the **pancreas** were observed to be largely isoechoic to surrounding omental fat. Some parenchymal remodeling, however, with mild deviation from curvilinear normalcy was observed. Pancreatic duct and capsular irregularities were present consistent with age related changes. If pain upon imaging (+ Murphy sign) was present or if the patient is focally painful in subxyphoid palpation then low-grade smoldering chronic pancreatitis should be suspected.

**BREED**

DMH

**SEX**

Spayed Female

**ULTRASONOGRAPHIC FINDINGS**

- Moderate degenerative renal changes with slight pyelectasia
- Age-related renal, hepatic, GI and pancreatic changes

**AGE**

13 Years

**INTERPRETATION OF THE FINDINGS & FURTHER RECOMMENDATIONS**

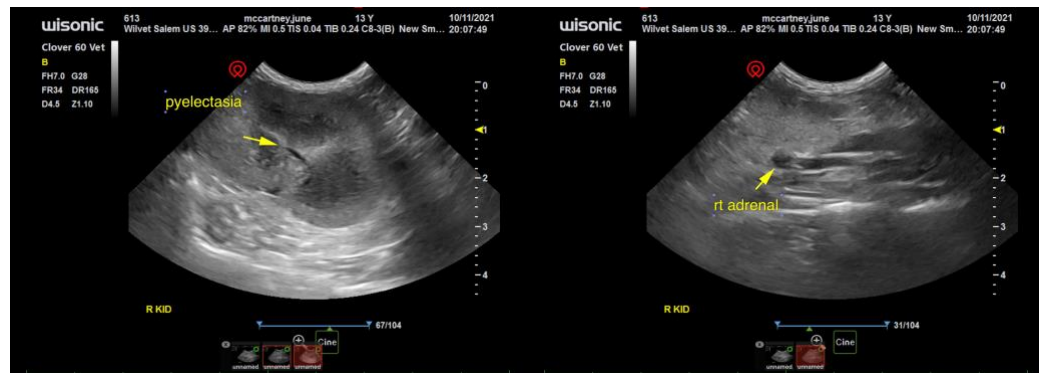Assessment for any evidence of UTI warranted. The cause of weight loss is unclear. Structurally unremarkable inflammatory bowel or other forms of GI insult suspected. Maldigestion panel, three view chest radiographs and full CNS examination is recommended to examine for occult disease that could be responsible for the weight loss. Evaluation for competitive eating environments should also be considered.

**WEIGHT**

3.3 kg

**INTERPRETED BY**

Eric Lindquist, DMV  
DABVP, Cert. IVUSS

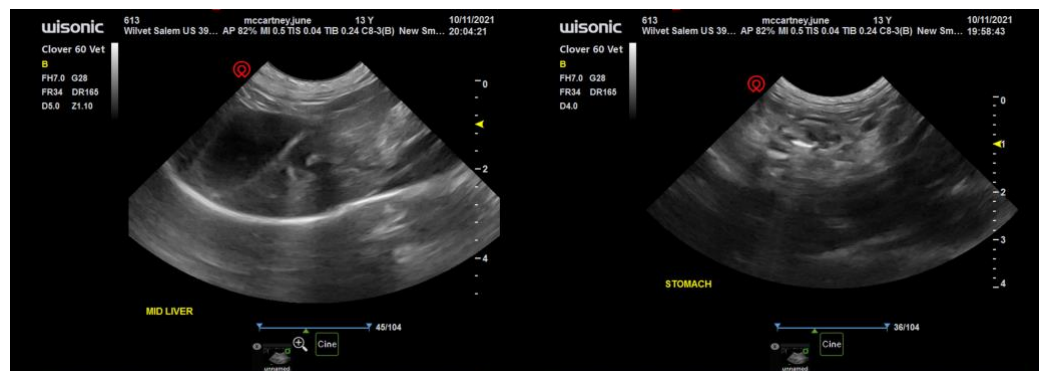


**IMAGING PERFORMED BY**

Anna Weprich

**HOSPITAL NAME**

Wilvet Salem



**REFERRING VET**

Brittany Gardener

**INVOICE**

13702

**DATE**

10-12-21



## PATIENT

June McCartney

## SPECIES

Feline

## BREED

DMH

## SEX

Spayed Female

## AGE

13 Years

## WEIGHT

3.3 kg

## INTERPRETED BY

Eric Lindquist, DMV  
DABVP, Cert. IVUSS

## IMAGING PERFORMED BY

Anna Wepprich

## HOSPITAL NAME

Wilvet Salem

## REFERRING VET

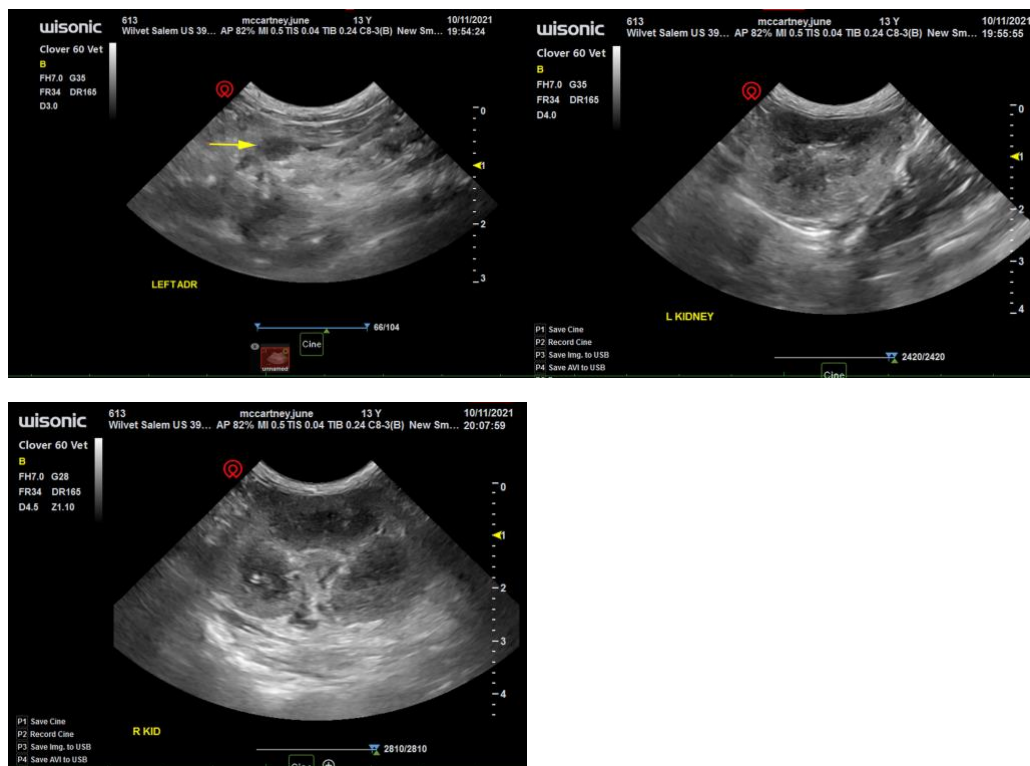
Brittany Gardener

## INVOICE

13702

## DATE

10-12-21



**The information and recommendations provided are based on the images presented by the referring veterinarian. No evaluation can be communicated regarding pathology that was not visible in the image/video clips provided.**

Thank you for this referral. If the clinical or image interpretation does not parallel your findings or if I can be of any further assistance please contact me.

**Eric Lindquist**, DMV, DABVP, Cert. IVUSS, CEO of SonoPath.com  
info@SonoPath.com