



PATIENT

Gigi Schlesinger

SPECIES

Canine

BREED

Morkie

SEX

Spayed Female

AGE

9 Years

WEIGHT

14 Pounds

PRESENTING CLINICAL SIGNS

History: Difficulty breathing, cardiomegaly on x-rays, Heart murmur 3/6

ULTRASONOGRAPHIC EXAMINATION OF THE HEART

CANINE CARDIAC PARAMETERS	MR VMAX (m/s)	TR VMAX (m/s)	LA/AO (Boon method)	LA/AO (Heart Base; Swe)	FS (%)	EF (%)	EPSS (cm)
NORMAL PARAMETER	4.5-5.5	<2.7	1.3	<1.6	28-40	40-100	<0.6
PATIENT	6.84	3.11	1.2	1.1	50	83	NM
CANINE CARDIAC PARAMETERS	HR (BPM)	AV VMAX (m/s)	PV MAX (m/s)	BODY WEIGHT (kg)	LA 2D short axis Base view (cm)	LVIDd Avg; 2D and m-mode short axis (cm)	LVIDs Avg; 2D and m-mode short axis (cm)
NORMAL PARAMETER	50-100	0.7-1.7	0.7-1.6	BELOW	BELOW	BELOW	BELOW
PATIENT	160	--	1.11	--	2.2	2.18	--

Cardiac Presentation

The echocardiogram in this patient demonstrated normal **left atrial** size based on 3 different LA measurement methods. Chamber volumes and echogenicity were normal. The cranial and caudal **mitral** valve leaflets presented vegetative thickening consistent with endocardiosis. Doppler indicated measurable insufficiency. The **left ventricle** presented thicknesses with linear contour and was not dilated nor restricted. The **myocardium** presented normal echogenicity without subjective evidence of significant fibrotic or ischemic disease. **Contractility** of the ventricular walls was adequate and in normal range for this patient evidenced by the fractional shortening measurement and subjective evaluation of the different regions of the myocardium. The **left ventricular outflow** tract demonstrated normal laminar flow and subjective structural integrity. The **right atrium** and auricle revealed normal size, structure and content. No evidence of masses was noted or chamber overload. **Tricuspid** insufficiency consistent with mild pulmonary hypertension at 3.11 m/s. The **right ventricle** was of normal size (1/3 diameter of LV), chordae structure, myocardial echogenicity and thickness. **Pulmonic** tract assessment revealed normal valve structure, laminar flow, and diameter (approx. 1:1 pa/ao ratio). No visible **pericardial** or free pleura fluid was noted. No echographically detectable evidence of infiltrative disease was visible. The cranial **mediastinum and pericardial regions** were free of masses in the visible window. Hepatic veins were not dilated.

ULTRASONOGRAPHIC FINDINGS

- Stage B-1 valvular disease
- Mild pulmonary hypertension

INTERPRETATION OF THE FINDINGS & FURTHER RECOMMENDATIONS

INVOICE

13706

DATE

10/12/21

INTERPRETED BY

Eric Lindquist, DMV
DABVP, Cert. IVUSS

IMAGING PERFORMED BY

Eric Lindquist, DMV
DABVP, Cert. IVUSS

HOSPITAL NAME

Franklin Lakes AH

REFERRING VET

Dr. Mastrascusa



PATIENT

Gigi Schlesinger

EKG and blood pressures +/- Holter monitor indicated in this patient. No cardiac therapy recommended at this time as no volume overload is present and the pulmonary hypertension is minor and unlikely to be causing the clinical signs given that no hepatic vein dilation is present. Assessment of BUN, creatinine, USG, chest radiographs and blood pressure as well as clinical exam ideal in 7-10 days. Basal respiratory rate should be <20/min. If anesthesia is necessary, there is no overt contraindication to an anesthetic procedure. Suggested protocol includes Torbutrol premed, Propofol induction, and Isoflurane maintenance. Recheck echocardiogram in 6 months or earlier if murmur grade increases or clinical signs initiate.

SPECIES

Canine

BREED

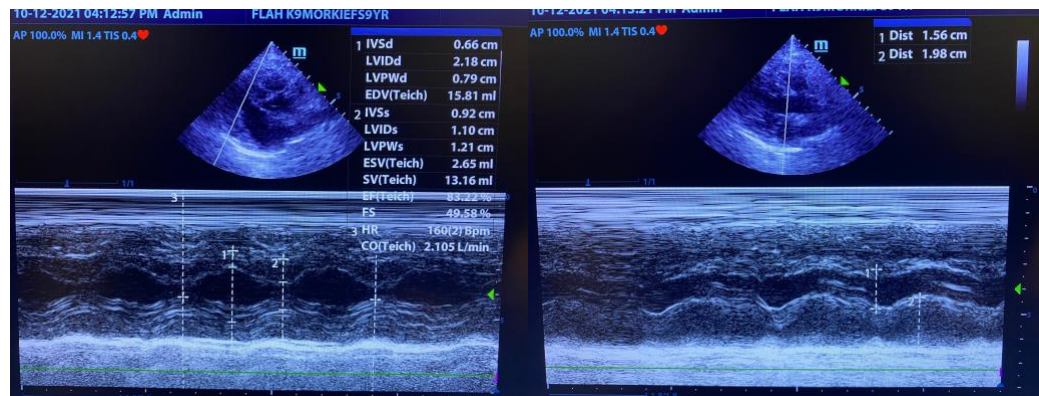
Morkie

SEX

Spayed Female

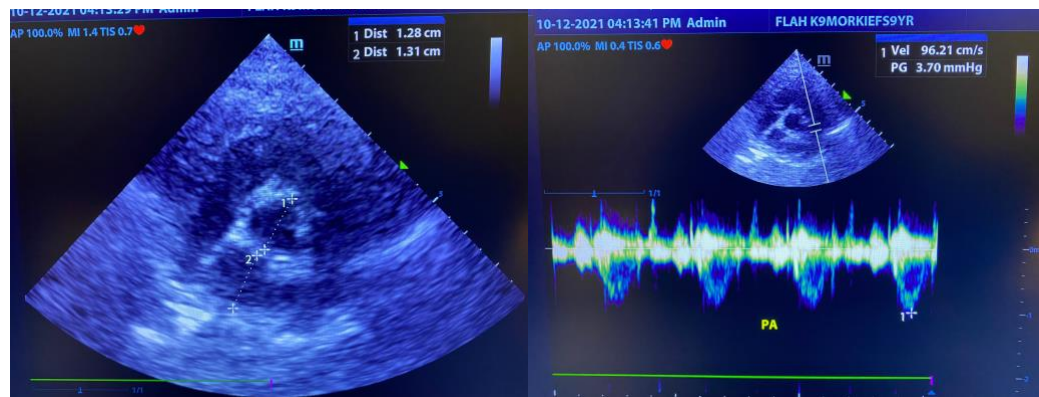
AGE

9 Years



WEIGHT

14 Pounds

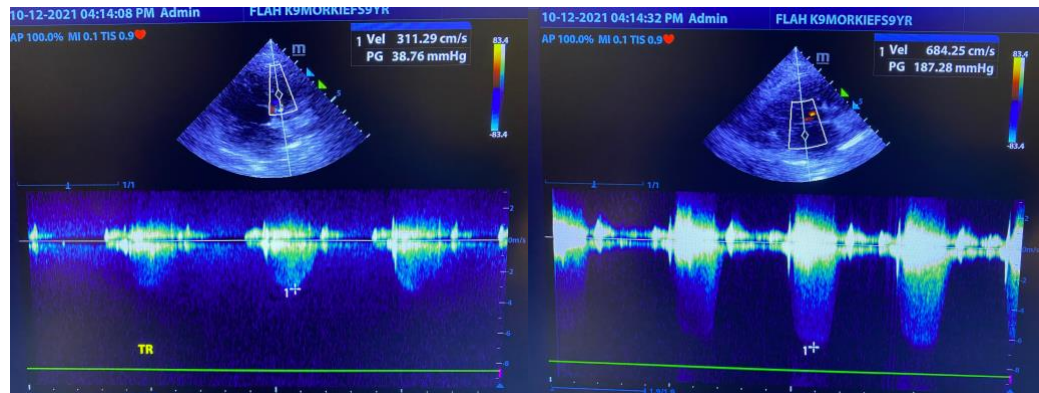


INTERPRETED BY

Eric Lindquist, DMV
DABVP, Cert. IVUSS

IMAGING PERFORMED BY

Eric Lindquist, DMV
DABVP, Cert. IVUSS



HOSPITAL NAME

Franklin Lakes AH

REFERRING VET

Dr. Mastrascusa

INVOICE

13706

DATE

10/12/21



PATIENT

Gigi Schlesinger

SPECIES

Canine

BREED

Morkie

SEX

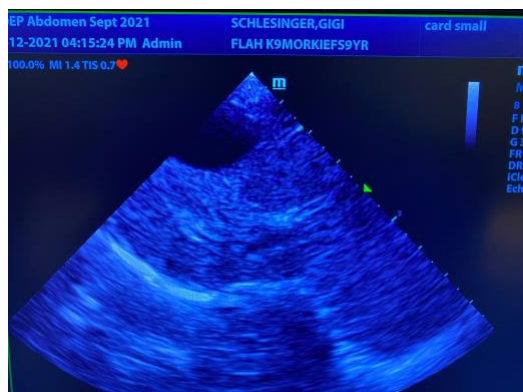
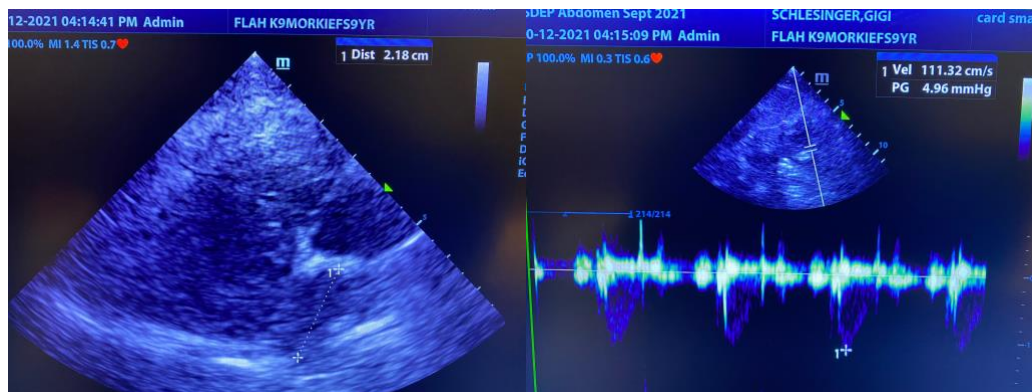
Spayed Female

AGE

9 Years

WEIGHT

14 Pounds



INTERPRETED BY

Eric Lindquist, DMV
DABVP, Cert. IVUSS

IMAGING PERFORMED BY

Eric Lindquist, DMV
DABVP, Cert. IVUSS

HOSPITAL NAME

Franklin Lakes AH

REFERRING VET

Dr. Mastrascusa

INVOICE

13706

DATE

10/12/21

The information and recommendations provided are based on the images presented by the referring veterinarian. No evaluation can be communicated regarding pathology that was not visible in the image/video clips provided.

Thank you for this referral. If the clinical or image interpretation does not parallel your findings or if I can be of any further assistance please contact me.

Eric Lindquist, DMV, DABVP, Cert. IVUSS, CEO of SonoPath.com
info@SonoPath.com