



PATIENT

Gerber Baby Cruz

PRESENTING CLINICAL SIGNS

History: Uterus large on x-rays. Current meds: amix.clav, carprofen 25mg

SPECIES

Canine

ULTRASONOGRAPHIC EXAMINATION OF THE ABDOMEN

Urinary System

BREED

French Bulldog

The **urinary bladder**, trigone, and pelvic urethra presented normal thicknesses and normal tone. The ureters were not visible which is normal. No uroliths or sediment were visualized and anechoic urine was present. No evidence of inflammatory or neoplastic changes was noted. Ureteral papillae were normal.

SEX

Female

The uterus was thickened in this patient with areas of localized lochia. There were no overt mummified fetuses noted. The luminal material in the uterus is excessive for 1 week post whelping.

AGE

2 years

The **kidneys** revealed normal size and structure, corticomedullary definition and ratio for this age. The cortices presented largely uniform texture with normal echogenic relationship to liver and spleen. Medullary structure differed distinctly from the cortex and no evidence of pelvic dilation was present. The capsules were acceptably uniform without significant irregularities. The right kidney measured 5.84 cm. The left kidney measured 5.2 cm.

WEIGHT

Adrenal Glands

INTERPRETED BY

Eric Lindquist, DMV
DABVP, Cert. IVUSS

Both **adrenal glands** were visualized and recognized as having normal shape, size, position and echogenicity for this breed. The phrenic vasculature, glandular echogenicity and detail were unremarkable. Capsule, cortex, and medullary definition were normal for this age patient. The left adrenal gland measured 1.86 x 0.59 cm at the caudal pole and 0.54 cm at the cranial pole. The right adrenal gland measured 2.84 x 0.31 cm at the caudal pole and 0.56 cm at the cranial pole.

IMAGING PERFORMED BY

Jessica Miller, RDMS

Spleen

The **spleen** presented a smooth homogeneous parenchyma hyperechoic to liver and renal cortical parenchyma. The capsule was smooth without noticeable expansion or deviation from within the spleen or adjacent pathology. The splenic vasculature demonstrated normal volume without signs of congestion or thrombosis. No sonographic evidence of acute or chronic inflammatory, neoplastic, or infarctual changes was noted.

HOSPITAL NAME

North Warren AH

REFERRING VET

Dr. Corrado

Liver

The **liver** images submitted revealed subjectively normal liver size, contour, and structure. Parenchymal echogenicity was naturally coarse and hypoechoic to the spleen. Vascular and biliary tracts were of normal volume with no evidence of congestion. The gallbladder presented acceptably thin walls with primarily anechoic content. The cystic and common bile ducts were normal. No pathological hepatic lymphadenopathy was evident. No overt structural evidence of inflammatory, infiltrative or regenerative pathology was evident.

INVOICE

92332

DATE

10/12/21



PATIENT

Gastrointestinal

Gerber Baby Cruz

Examination of the **gastrointestinal tract** revealed a stomach and intestine free of stasis, of normal wall thickness, acceptable curvilinear mural detail, and peristaltic activity. Small and large intestine demonstrated normal luminal chyme and stool consistency respectively. No obstructive or overt infiltrative disease was noted. No associated abnormal lymphatic activity was noted.

SPECIES

Canine

BREED

French Bulldog

Pancreas

The base and limbs of the **pancreas** were observed to be largely isoechoic to surrounding omental fat. Pancreatic duct and capsular contour were acceptably normal and parenchyma respected normal curvilinear patterns. No overt evidence of active inflammatory or neoplastic disease was noted.

SEX

Female

ULTRASONOGRAPHIC FINDINGS

Thickened uterus with areas of localized lochia.

AGE

2 years

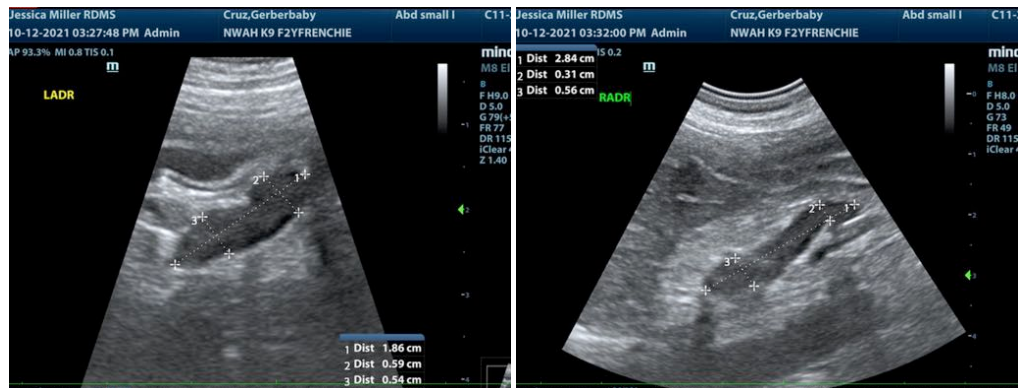
INTERPRETATION OF THE FINDINGS & FURTHER RECOMMENDATIONS

WEIGHT

If vaginal discharge is present then underlying metritis may be developing. Coverage with broad spectrum antibiotics that are safe for lactation would be indicated. Medical management for uterine liberation is recommended. Recheck sonogram is recommended in 48-72 hours to ensure adequate medical resolution.

INTERPRETED BY

Eric Lindquist, DMV
DABVP, Cert. IVUSS



IMAGING PERFORMED BY

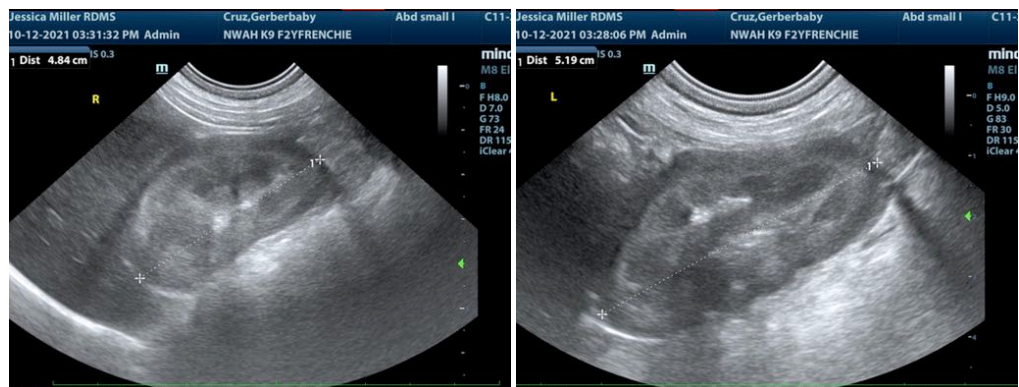
Jessica Miller, RDMS

HOSPITAL NAME

North Warren AH

REFERRING VET

Dr. Corrado



INVOICE

92332

DATE

10/12/21



PATIENT

Gerber Baby Cruz

SPECIES

Canine

BREED

French Bulldog

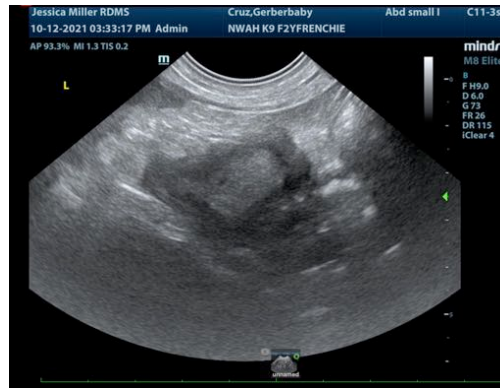
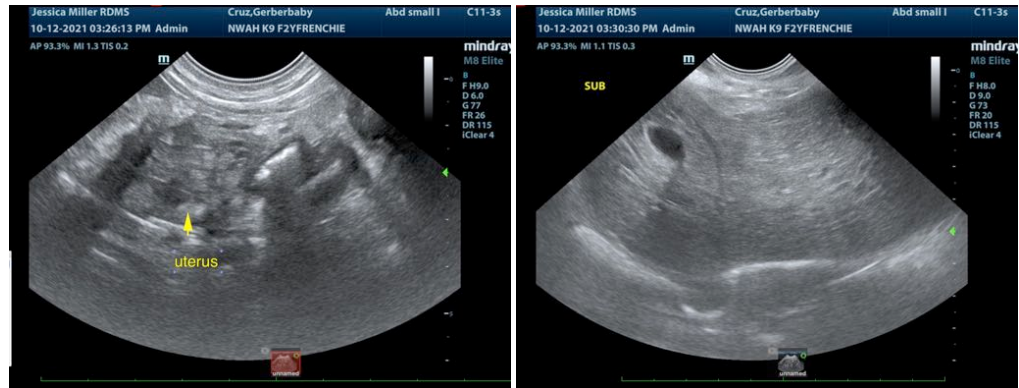
SEX

Female

AGE

2 years

WEIGHT



INTERPRETED BY

Eric Lindquist, DMV
DABVP, Cert. IVUSS

IMAGING PERFORMED BY

Jessica Miller, RDMS

HOSPITAL NAME

North Warren AH

REFERRING VET

Dr. Corrado

INVOICE

92332

DATE

10/12/21

The information and recommendations provided are based on the images presented by the referring veterinarian. No evaluation can be communicated regarding pathology that was not visible in the image/video clips provided.

Thank you for this referral. If the clinical or image interpretation does not parallel your findings or if I can be of any further assistance please contact me.

Eric Lindquist, DMV, DABVP, Cert. IVUSS, CEO of SonoPath.com
info@SonoPath.com