



PATIENT

Dexter Corvalan

SPECIES

Canine

BREED

Mini Australian
Shepherd

SEX

Neutered Male

AGE

8 Years 11 Months

WEIGHT

26 Pounds

INTERPRETED BY

Eric Lindquist, DMV
DABVP, Cert. IVUSS

**IMAGING
PERFORMED BY**

Dr. Agnes Rupley

HOSPITAL NAME

All Pets Medical Center

REFERRING VET

Dr. Agnes Rupley

INVOICE

26219

DATE

10/12/21

PRESENTING CLINICAL SIGNS

PRESENTED FOR: Medical progress ultrasound for follow up on previously identified mass in liver.
Prior U/S 8/9/21 – Left lateral liver lesion.

ULTRASONOGRAPHIC EXAMINATION OF THE ABDOMEN

Urinary System

The **urinary bladder**, trigone, and pelvic urethra presented normal thicknesses and normal tone. The ureters were not visible which is normal. No uroliths or sediment were visualized and anechoic urine was present. No evidence of inflammatory or neoplastic changes were noted. Ureteral papillae were normal.

The **kidneys** revealed normal size and structure, corticomedullary definition and ratio for this age. The cortices presented largely uniform texture with normal echogenic relationship to liver and spleen. Medullary structure differed distinctly from the cortex and no evidence of pelvic dilation was present. The capsules were acceptably uniform without significant irregularities. The left kidney measured 3.9 cm. The right kidney measured 4.47 cm.

Adrenal Glands

The **left adrenal gland** was visualized and recognized as having normal shape, size, position and echogenicity for this breed. The phrenic vasculature, glandular echogenicity and detail were unremarkable. Capsule, cortex, and medullary definition were normal for this age patient. The left adrenal gland measured 0.57 cm.

The **right adrenal gland** was not visualized.

Spleen

The **spleen** presented a smooth homogeneous parenchyma hyperechoic to liver and renal cortical parenchyma. The capsule was smooth without noticeable expansion or deviation from within the spleen or adjacent pathology. The splenic vasculature demonstrated normal volume without signs of congestion or thrombosis. No sonographic evidence of acute or chronic inflammatory, neoplastic, or infarctual changes were noted.

Liver

The **liver** revealed slight increased portal markings and slight coarse architecture. Prior nodule noted was not visualized. The gallbladder presented acceptably thin walls with primarily anechoic content. The cystic and common bile ducts were normal. No pathological hepatic lymphadenopathy was evident. No overt structural evidence of inflammatory, infiltrative or regenerative pathology was evident.

Gastrointestinal

Examination of the **gastrointestinal tract** revealed a stomach and intestine free of stasis, of normal wall thickness, acceptable curvilinear mural detail, and peristaltic activity. Small and large intestine demonstrated normal luminal chyme and stool consistency respectively. No obstructive or overt infiltrative disease was noted. No associated abnormal lymphatic activity was noted.

Pancreas

The base and limbs of the **pancreas** were observed to be largely isoechoic to surrounding omental fat. Pancreatic duct and capsular contour were acceptably normal and parenchyma respected normal curvilinear patterns. No overt evidence of active inflammatory or neoplastic disease was noted.



PATIENT

Dexter Corvalan

ULTRASONOGRAPHIC FINDINGS

- Unremarkable abdomen

SPECIES

Canine

INTERPRETATION OF THE FINDINGS & FURTHER RECOMMENDATIONS

No evidence of significant disease. The nodule noted on the prior sonogram was no longer visible. At times, hyperplastic or lipogranulomatous changes can appear and then resolve.

BREED

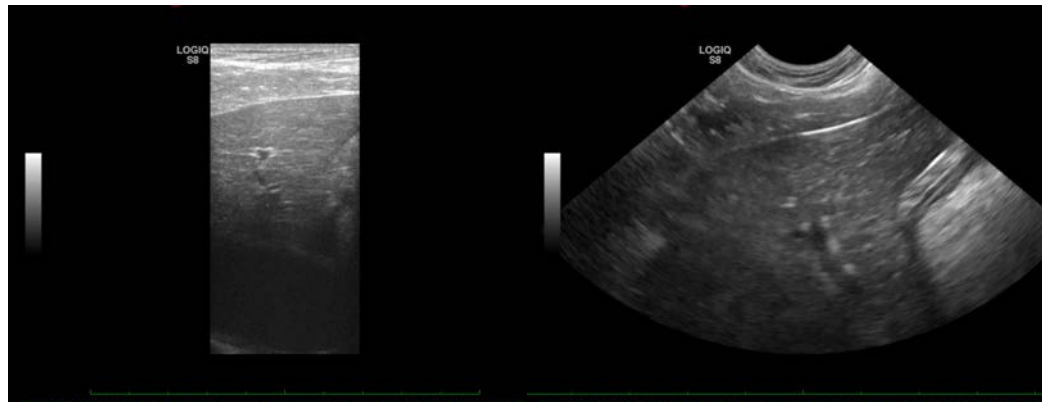
Mini Australian Shepherd

SEX

Neutered Male

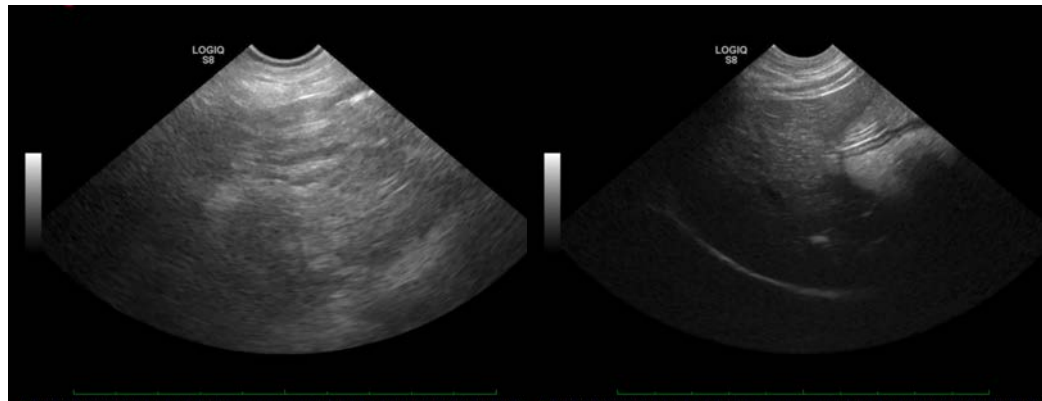
AGE

8 Years 11 Months



WEIGHT

26 Pounds



INTERPRETED BY

Eric Lindquist, DMV
DABVP, Cert. IVUSS

IMAGING PERFORMED BY

Dr. Agnes Rupley

HOSPITAL NAME

All Pets Medical Center

REFERRING VET

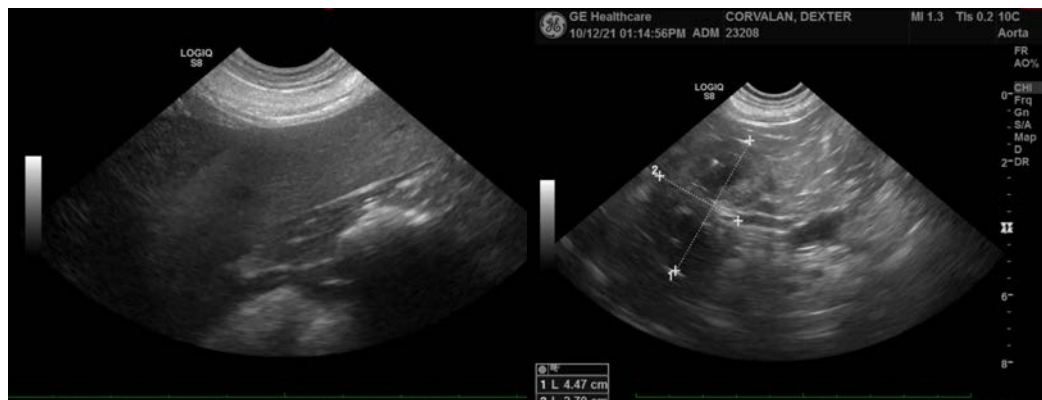Dr. Agnes Rupley

INVOICE

26219

DATE

10/12/21





PATIENT

Dexter Corvalan

SPECIES

Canine

BREED

Mini Australian
Shepherd

SEX

Neutered Male

AGE

8 Years 11 Months

WEIGHT

26 Pounds

INTERPRETED BY

Eric Lindquist, DMV
DABVP, Cert. IVUSS

**IMAGING
PERFORMED BY**

Dr. Agnes Rupley

HOSPITAL NAME

All Pets Medical Center

REFERRING VET

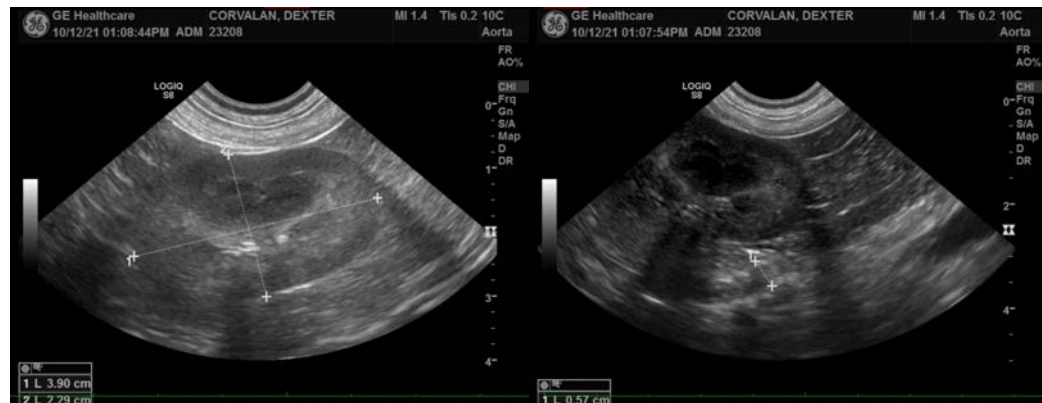Dr. Agnes Rupley

INVOICE

26219

DATE

10/12/21



The information and recommendations provided are based on the images presented by the referring veterinarian. No evaluation can be communicated regarding pathology that was not visible in the image/video clips provided.

Thank you for this referral. If the clinical or image interpretation does not parallel your findings or if I can be of any further assistance please contact me.

Eric Lindquist, DMV, DABVP, Cert. IVUSS, CEO of SonoPath.com
info@SonoPath.com