



**PATIENT**

Harley Marantz

**PRESENTING CLINICAL SIGNS**

Presented for low blood sugar

**SPECIES**

Feline

**ULTRASONOGRAPHIC EXAMINATION OF THE ABDOMEN**

**Urinary System**

The **urinary bladder**, trigone, and pelvic urethra presented normal thicknesses and normal tone. The ureters were not visible which is normal. No uroliths or sediment were visualized and anechoic urine was present. No evidence of inflammatory or neoplastic changes were noted. Ureteral papillae were normal.

**BREED**

Ragdoll

**SEX**

Spayed Female

The **kidneys** were swollen with pericapsular inflammatory pattern and slight pyelectasia, consistent with nephritis. Blood flow to the kidneys appeared to be adequate on power doppler assessment. The left kidney measured 4.91 cm. Slight pericapsular fluid and inflammation noted around the right kidney.

**Adrenal Glands**

The regions of the **adrenal glands** were unremarkable.

**AGE**

13 Years

**Spleen**

The **spleen** in this patient was uniform, yet volume contracted. Hydration status should be assessed.

**WEIGHT**

14.7 Pounds

**Liver**

The **liver** revealed lobar biliary mineralization with increased portal markings. The gallbladder and common bile duct were unremarkable. Minor amount of gallbladder sand noted without obstructive pattern.

**INTERPRETED BY**

Eric Lindquist, DMV

**Gastrointestinal**

Examination of the **gastrointestinal tract** revealed a stomach and intestine free of stasis, of normal wall thickness, acceptable curvilinear mural detail, and peristaltic activity. Small and large intestine demonstrated normal luminal chyme and stool consistency respectively. No obstructive or overt infiltrative disease was noted. No associated abnormal lymphatic activity was noted.

DABVP, Cert. IVUSS

**IMAGING PERFORMED BY**

Jenn

**Pancreas**

The pancreas presented undulating contour with hypoechoic parenchyma, primarily in the right limb.

**HOSPITAL NAME**

Rockaway AH

**ULTRASONOGRAPHIC FINDINGS**

- Fairly aggressive nephritis presentation with concurrent pancreatitis – possibility of emerging renal neoplasia/lymphoma.
- Volume contracted spleen
- Lobar biliary mineralization and gallbladder sand

**REFERRING VET**

Dr. Maniar

**INTERPRETATION OF THE FINDINGS & FURTHER RECOMMENDATIONS**

**INVOICE**

41941

Coagulation panel and 25-gauge FNA of the right kidney indicated with full urinary workup. Consideration for sepsis warranted, given the hypoglycemia. Recheck sonogram in 3-5 days post-treatment.

**DATE**

10/10/22



**PATIENT**

Harley Marantz

**SPECIES**

Feline

**BREED**

Ragdoll

**SEX**

Spayed Female

**AGE**

13 Years

**WEIGHT**

14.7 Pounds

**INTERPRETED BY**

Eric Lindquist, DMV  
DABVP, Cert. IVUSS

**IMAGING PERFORMED BY**

Jenn

**HOSPITAL NAME**

Rockaway AH

**REFERRING VET**

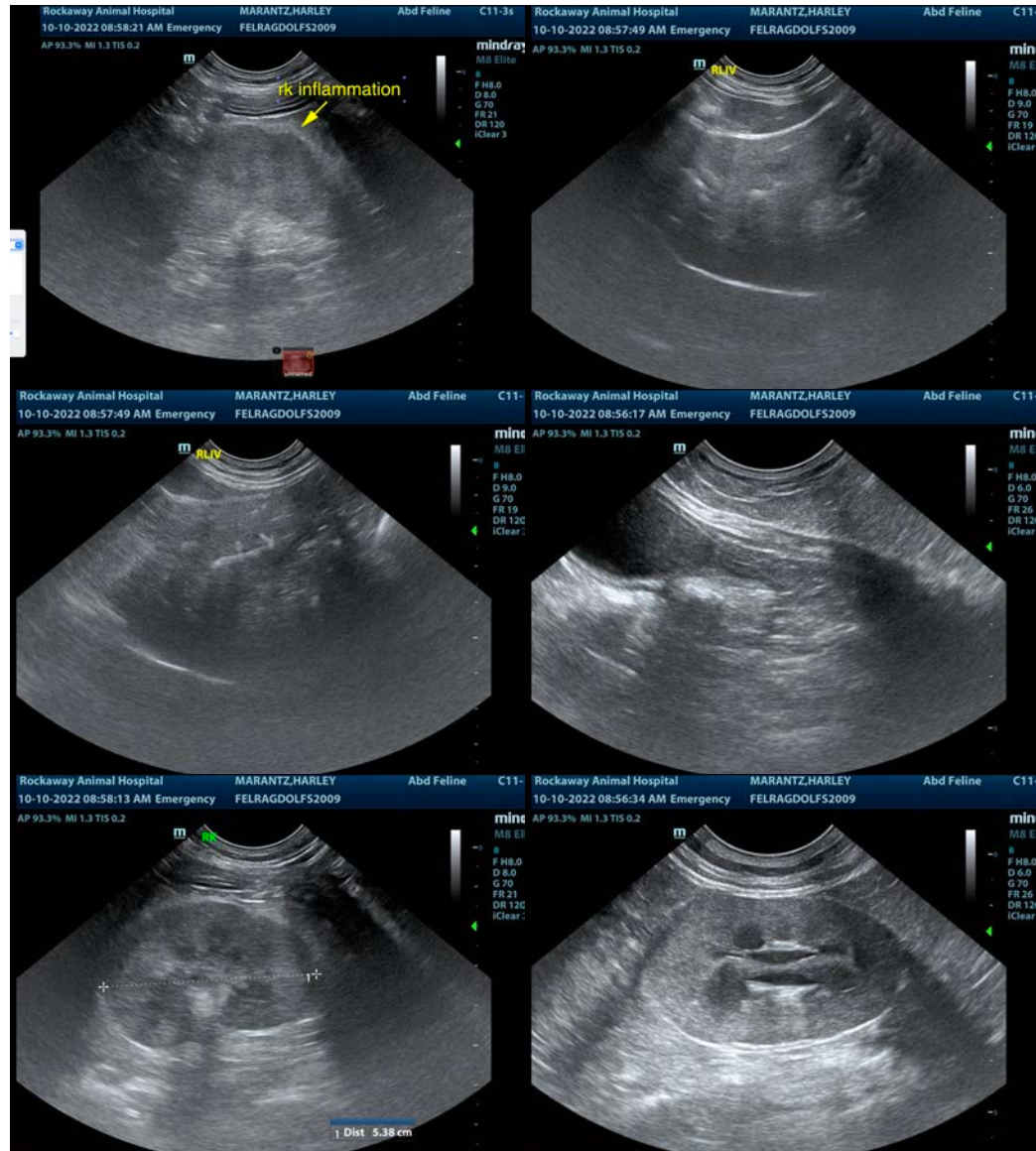
Dr. Maniar

**INVOICE**

41941

**DATE**

10/10/22



The information and recommendations provided are based on the images presented by the referring veterinarian/sonographer. No evaluation can be communicated regarding pathology that was not visible in the image/video clips provided.

Thank you for this referral. If the clinical or image interpretation does not parallel your findings or if I can be of any further assistance please contact me.

Eric Lindquist, DMV, DABVP, Cert. IVUSS, CEO of SonoPath.com

[info@SonoPath.com](mailto:info@SonoPath.com)