



**PATIENT**

Benelli Lake

**PRESENTING CLINICAL SIGNS**

wobbly, ataxic, acute onset possible Addisons based on ACTH stim, Has whipworm and tapeworm

**SPECIES**

Canine

**ULTRASONOGRAPHIC EXAMINATION OF THE HEART & ABDOMEN**

**BREED**

Weimaraner

CANINE CARDIAC PARAMETERS	MR VMAX (m/s)	TR VMAX (m/s)	LA/AO (Boon method)	LA/AO (Heart Base; Swe)	FS (%)	EF (%)	EPSS (cm)
NORMAL PARAMETER	4.5-5.5	<2.7	1.3	<1.6	28-40	40-100	<0.6
PATIENT			NM	1.02	35	80	0.29
CANINE CARDIAC PARAMETERS	HR (BPM)	AV VMAX (m/s)	PV MAX (m/s)	BODY WEIGHT (kg)	LA 2D short axis Base view (cm)	LVIDd Avg; 2D and m-mode short axis (cm)	LVIDs Avg; 2D and m-mode short axis (cm)
NORMAL PARAMETER	50-100	0.7-1.7	0.7-1.6	BELOW	BELOW	BELOW	BELOW
PATIENT	110	1.5	1.14		2.8	3.0	

**SEX**

Male

**AGE**

4 Months

**WEIGHT**

38 Pounds

**Cardiac Presentation**

**INTERPRETED BY**

Eric Lindquist, DMV

DABVP, Cert. IVUSS

**IMAGING PERFORMED BY**

Jenn

**HOSPITAL NAME**

Rockaway AH

**REFERRING VET**

Dr. Maniar

**INVOICE**

41951

**DATE**

10/10/22

The echocardiogram in this patient demonstrated normal **left atrial** size based on 3 separate methods of LA evaluation. The cranial and caudal **mitral** valve leaflets presented normal linear structure, extension in systole, and union in diastole with normal kinesis. The **left ventricle** presented thicknesses with linear contour and was not dilated nor restricted. The **myocardium** presented normal echogenicity without subjective evidence of significant fibrotic or ischemic disease. **Contractility** of the ventricular walls was adequate and in normal range for this patient evidenced by the fractional shortening measurement and subjective evaluation of the different regions of the myocardium. The **left ventricular outflow** tract demonstrated normal laminar flow and subjective structural integrity. The **right atrium** and auricle revealed normal size, structure and content. No evidence of masses was noted. **Tricuspid** valvular assessment demonstrated adequate linear morphology and kinesis. The **right ventricle** was of normal size (1/3 diameter of LV), chordae structure, myocardial echogenicity and thickness. **Pulmonary outflow** tract assessment revealed normal valve structure, laminar flow, and diameter (approx.1:1 pa/ao ratio). No visible **pericardial** or free pleura fluid was noted. The cranial **mediastinum and pericardial and extra-cardiac regions** were free of masses in the visible window.

**Urinary System**

The **urinary bladder**, trigone, and pelvic urethra presented normal thicknesses and normal tone. The ureters were not visible which is normal. No uroliths or sediment were visualized and anechoic urine was present. No evidence of inflammatory or neoplastic changes were noted. Ureteral papillae were normal.

The **kidneys** revealed normal size and structure, corticomedullary definition and ratio for this age. The cortices presented largely uniform texture with normal echogenic relationship to liver and spleen.

Medullary structure differed distinctly from the cortex and no evidence of pelvic dilation was present.



**PATIENT**

Benelli Lake

The capsules were acceptably uniform without significant irregularities. The right kidney measured 5.71 cm. The left kidney measured 6.11 cm.

**Adrenal Glands**

**SPECIES**

Canine

Both **adrenal glands** were visualized and recognized as having normal shape, size, position and echogenicity for this breed. The phrenic vasculature, glandular echogenicity and detail were unremarkable. Capsule, cortex, and medullary definition were normal for this age patient. The right adrenal gland measured 1.68 cm x 0.74 cm at the caudal pole and 1.33 cm at the cranial pole. The left adrenal gland measured 1.8 cm x 0.47 cm at the caudal pole and 0.37 cm at the cranial pole.

**BREED**

Weimaraner

**Spleen**

**SEX**

Male

The **spleen** presented a smooth homogeneous parenchyma hyperechoic to liver and renal cortical parenchyma. The capsule was smooth without noticeable expansion or deviation from within the spleen or adjacent pathology. The splenic vasculature demonstrated normal volume without signs of congestion or thrombosis. No sonographic evidence of acute or chronic inflammatory, neoplastic, or infarctual changes were noted.

**AGE**

4 Months

**Liver**

**WEIGHT**

38 Pounds

The **liver** images submitted revealed subjectively normal liver size, contour, and structure. Parenchymal echogenicity was naturally coarse and hypoechoic to the spleen. Vascular and biliary tracts were of normal volume with no evidence of congestion. The gallbladder presented acceptably thin walls with primarily anechoic content. The cystic and common bile ducts were normal. No pathological hepatic lymphadenopathy was evident. No overt structural evidence of inflammatory, infiltrative or regenerative pathology was evident.

**Gastrointestinal**

**INTERPRETED BY**

Eric Lindquist, DMV

Examination of the **gastrointestinal tract** revealed a stomach and intestine free of stasis, of normal wall thickness, acceptable curvilinear mural detail, and peristaltic activity. Small and large intestine demonstrated normal luminal chyme and stool consistency respectively. No obstructive or overt infiltrative disease was noted. No associated abnormal lymphatic activity was noted.

DABVP, Cert. IVUSS

**IMAGING PERFORMED BY**

Jenn

**Pancreas**

**HOSPITAL NAME**

Rockaway AH

The base and limbs of the **pancreas** were observed to be largely isoechoic to surrounding omental fat. Pancreatic duct and capsular contour were acceptably normal and parenchyma respected normal curvilinear patterns. No overt evidence of active inflammatory or neoplastic disease was noted.

**ULTRASONOGRAPHIC FINDINGS**

- Normal echocardiogram, no evidence of pathology
- Structurally normal abdomen, no evidence of pathology

**REFERRING VET**

Dr. Maniar

**INTERPRETATION OF THE FINDINGS & FURTHER RECOMMENDATIONS**

No overt cause of the ataxia noted. Full CNS examination warranted. EKG indicated +/- holter monitor to assess for paroxysmal arrhythmia, yet structure and function of the heart and abdomen appear normal.

**INVOICE**

41951

**DATE**

10/10/22



**PATIENT**

Benelli Lake

**SPECIES**

Canine

**BREED**

Weimaraner

**SEX**

Male

**AGE**

4 Months

**WEIGHT**

38 Pounds

**INTERPRETED BY**

Eric Lindquist, DMV

DABVP, Cert. IVUSS

**IMAGING PERFORMED BY**

Jenn

**HOSPITAL NAME**

Rockway AH

**REFERRING VET**

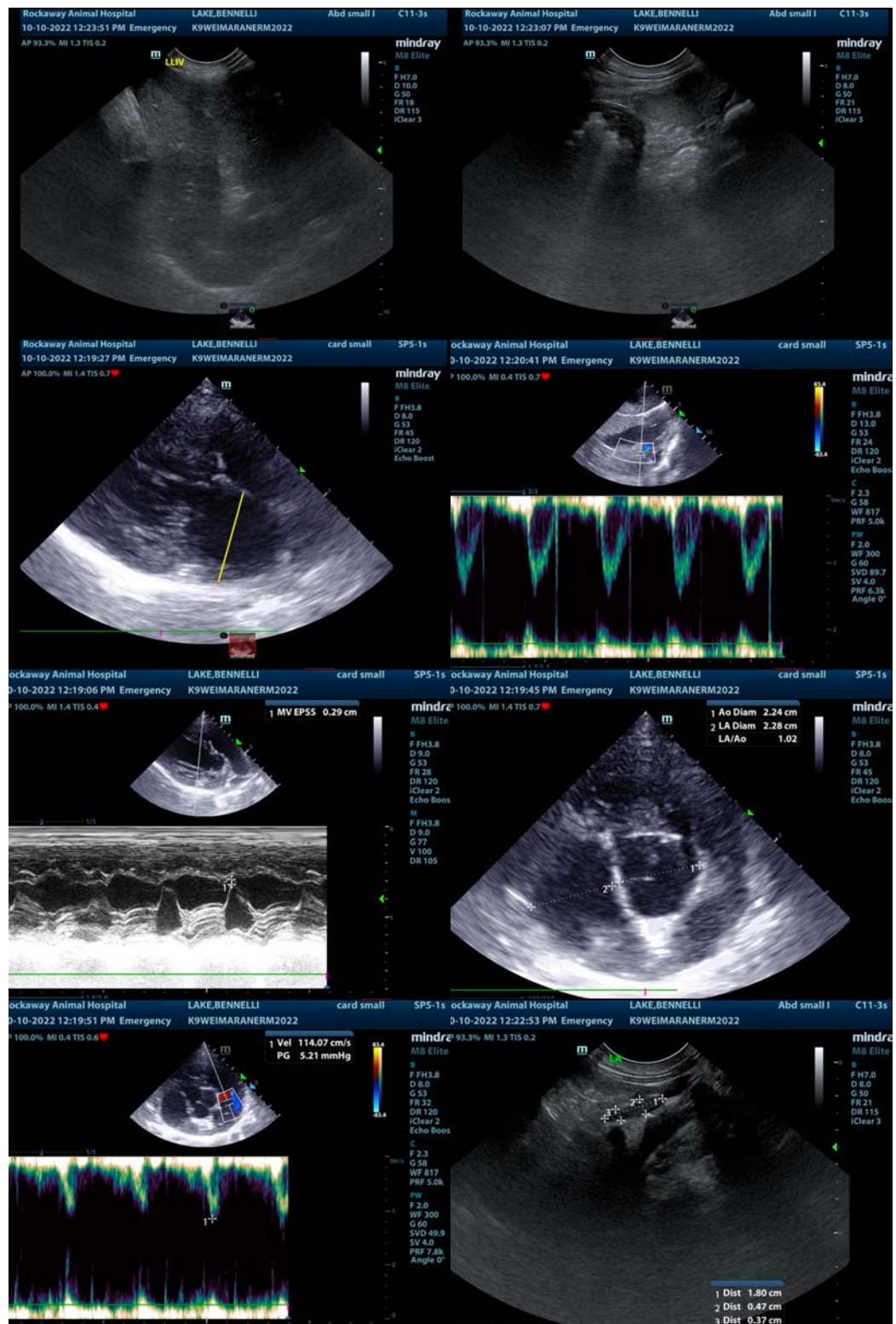
Dr. Maniar

**INVOICE**

41951

**DATE**

10/10/22





**PATIENT**

Benelli Lake

**SPECIES**

Canine

**BREED**

Weimaraner

**SEX**

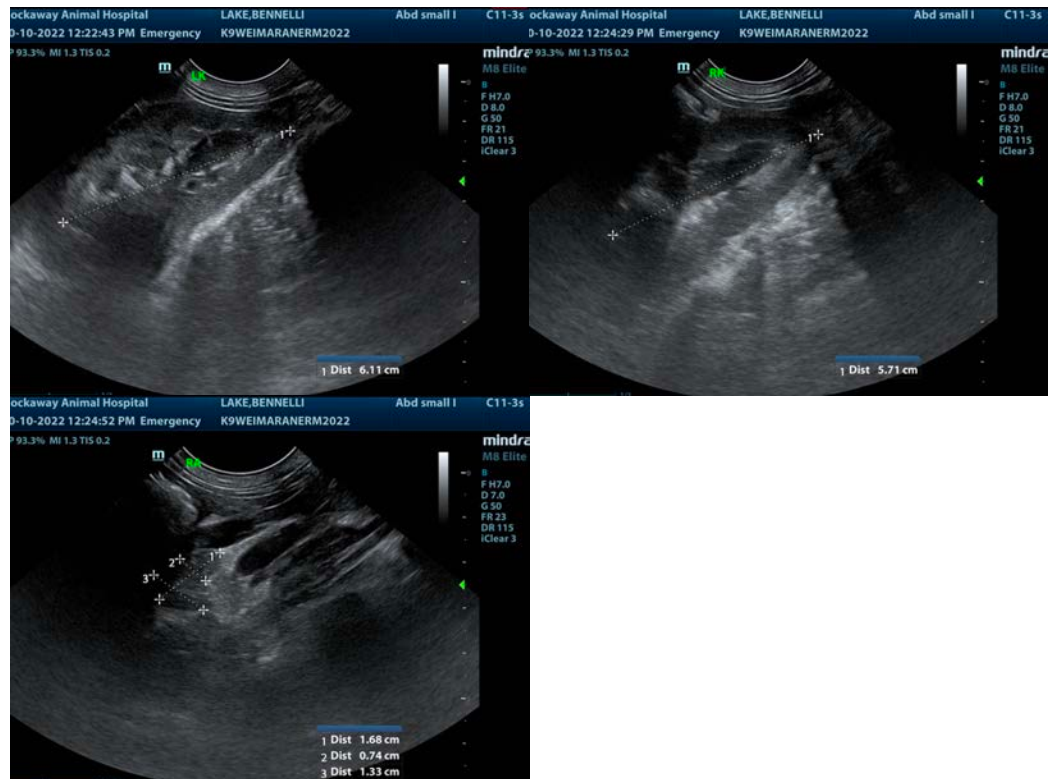
Male

**AGE**

4 Months

**WEIGHT**

38 Pounds



**INTERPRETED BY**

Eric Lindquist, DMV  
DABVP, Cert. IVUSS

**IMAGING PERFORMED BY**

Jenn

**HOSPITAL NAME**

Rockaway AH

**REFERRING VET**

Dr. Maniar

**INVOICE**

41951

**DATE**

10/10/22

The information and recommendations provided are based on the images presented by the referring veterinarian/sonographer. No evaluation can be communicated regarding pathology that was not visible in the image/video clips provided.

Thank you for this referral. If the clinical or image interpretation does not parallel your findings or if I can be of any further assistance please contact me.

Eric Lindquist, DMV, DABVP, Cert. IVUSS, CEO of SonoPath.com

[info@SonoPath.com](mailto:info@SonoPath.com)