



PATIENT

Winx VanLeuvan

SPECIES

Feline

BREED

Domestic Shorthair

SEX

Neutered Male

AGE

10 years

WEIGHT

9.5 Pounds

INTERPRETED BY

Eric Lindquist, DMV
DABVP, Cert. IVUS

IMAGING PERFORMED BY

Rebekah Jakum, CVT
ARDMS/RVT

HOSPITAL NAME

Littlestown VH

REFERRING VET

Dr. Kubala

INVOICE

13426

DATE

10.1.2021

PRESENTING CLINICAL SIGNS

History: Decreased appetite, weight loss

Medication: Convenia, Baytril, Lasix

ULTRASONOGRAPHIC EXAMINATION OF THE CHEST

Spleen

The **spleen** was enlarged and irregular with heterogeneous parenchymal changes, strongly suggestive for infiltrative disease. Splenic maximum width was 1.5 cm.

Liver

The **liver** was enlarged, heterogeneous, diffusely hyperechoic with attenuating sound beam with macronodular changes. The gallbladder and common bile duct were unremarkable.

Chest

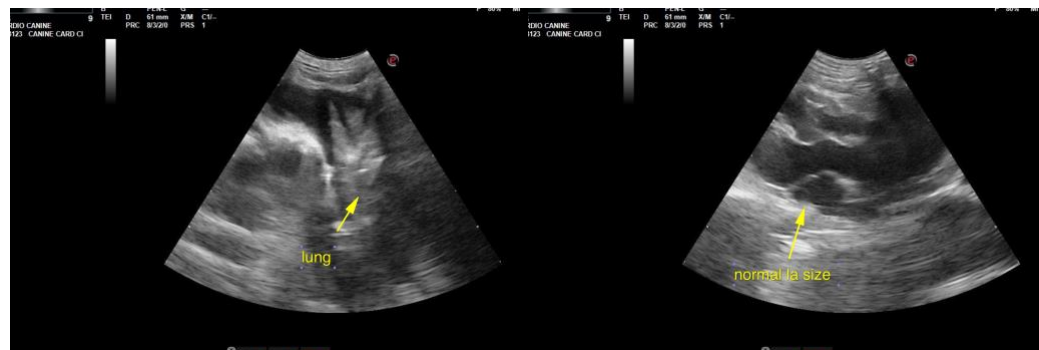A rapid view of the **heart** revealed volume contraction, normal wall thicknesses and contractility, surrounded by a large amount of non-cardiogenic pleural effusion. Given the splenohepatic presentation, I suspect metastatic disease to the chest. Minor pleural irregularities noted with suspended debris within the chest. Variable lung consolidations also noted. The left atrial size is normal to subnormal in this patient confirming no cardiogenic source to the pleural effusion. The right caudal lung revealed irregular consolidation, strongly suggestive for primary metastatic neoplasia.

ULTRASONOGRAPHIC FINDINGS

- Thoracic neoplastic pattern suspected
- Splenohepatomegaly

INTERPRETATION OF THE FINDINGS & FURTHER RECOMMENDATIONS

FNA of the spleen, liver and pleurocentesis with cytospin indicated.





PATIENT

Winx VanLeuvan

SPECIES

Feline

BREED

Domestic Shorthair

SEX

Neutered Male

AGE

10 years

WEIGHT

9.5 Pounds

INTERPRETED BY

Eric Lindquist, DMV
DABVP, Cert. IVUS

**IMAGING
PERFORMED BY**

Rebekah Jakum, CVT
ARDMS/RVT

HOSPITAL NAME

Littlestown VH

REFERRING VET

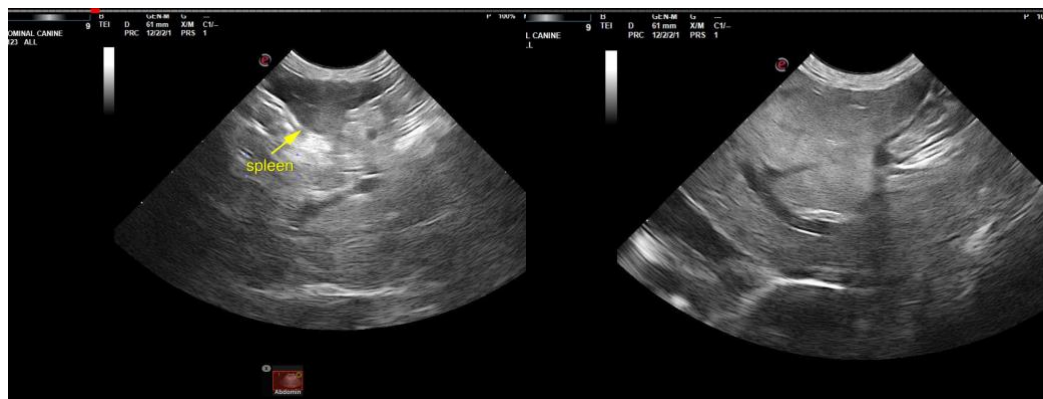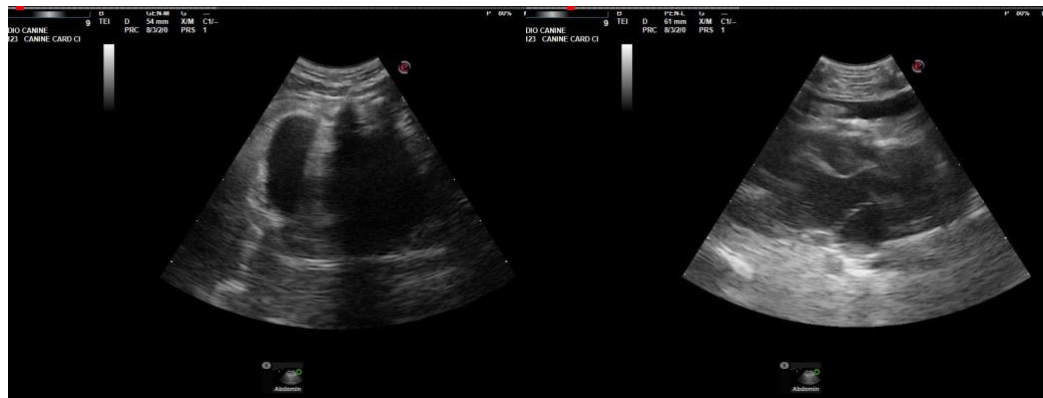
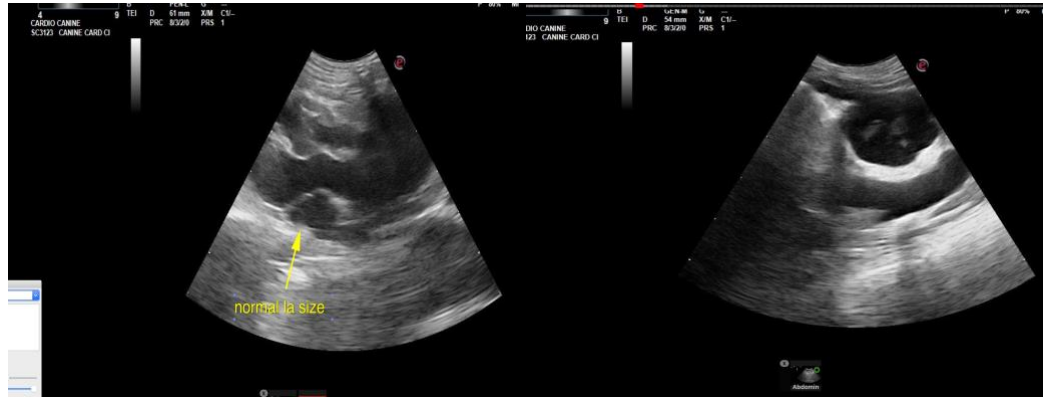Dr. Kubala

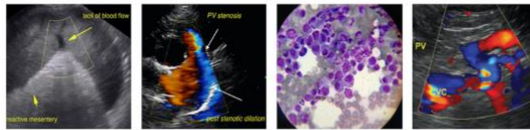
INVOICE

13426

DATE

10.1.2021





PATIENT

Winx VanLeuvan

SPECIES

Feline

BREED

Domestic Shorthair

SEX

Neutered Male

AGE

10 years

WEIGHT

9.5 Pounds

INTERPRETED BY

Eric Lindquist, DMV
DABVP, Cert. IVUSS

**IMAGING
PERFORMED BY**

Rebekah Jakum, CVT
ARDMS/RVT

HOSPITAL NAME

Littlestown VH

REFERRING VET

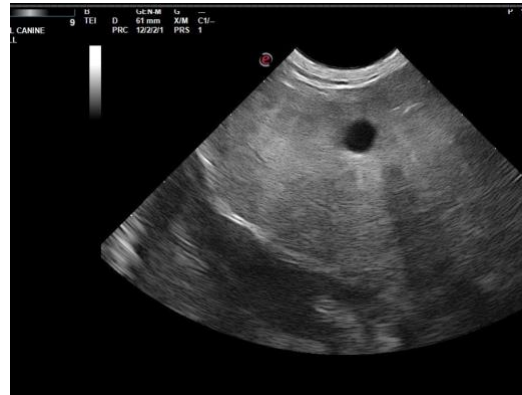Dr. Kubala

INVOICE

13426

DATE

10.1.2021



The information and recommendations provided are based on the images presented by the referring veterinarian. No evaluation can be communicated regarding pathology that was not visible in the image/video clips provided.

Thank you for this referral. If the clinical or image interpretation does not parallel your findings or if I can be of any further assistance please contact me.

Eric Lindquist, DMV, DABVP, Cert. IVUSS, CEO of SonoPath.com
Eric.Lindquist@SonoPath.com