

PATIENT PRESENTING CLINICAL SIGNS

Timer Schlorman wellogram screen for Gallbladder Mucocele

SPECIES ULTRASONOGRAPHIC EXAMINATION OF THE ABDOMEN

Canine Urinary System

The **urinary bladder**, trigone, and pelvic urethra presented normal thicknesses and normal tone. The ureters were not visible which is normal. No uroliths or sediment were visualized and anechoic urine was present. No evidence of inflammatory or neoplastic changes were noted. Ureteral papillae were normal. The pelvic urethra was imaged 2.0 cm beyond the cystourethral junction. The residual prostate measured 5.0 mm.

BREED

Shetland Sheepdog

SEX

Neutered Male

The **kidneys** revealed normal size and structure, corticomedullary definition and ratio for this age. The cortices presented largely uniform texture with normal echogenic relationship to liver and spleen. Medullary structure differed distinctly from the cortex and no evidence of pelvic dilation was present. The capsules were acceptably uniform without significant irregularities. The right kidney measured 4.79 cm. The left kidney measured 4.8 cm.

AGE

5 Years

Adrenal Glands

Both **adrenal glands** were visualized and recognized as having normal shape, size, position and echogenicity for this breed. The phrenic vasculature, glandular echogenicity and detail were unremarkable. Capsule, cortex, and medullary definition were normal for this age patient. The left adrenal gland measured 1.74 cm x 0.54 cm at the cranial pole and 0.42 cm at the caudal pole. The right adrenal gland measured 1.86 cm x 1.0 cm at the cranial pole and 0.62 cm at the caudal pole.

WEIGHT

28 Pounds

Spleen

The **spleen** presented a smooth homogeneous parenchyma hyperechoic to liver and renal cortical parenchyma. The capsule was smooth without noticeable expansion or deviation from within the spleen or adjacent pathology. The splenic vasculature demonstrated normal volume without signs of congestion or thrombosis. No sonographic evidence of acute or chronic inflammatory, neoplastic, or infarctual changes were noted.

INTERPRETED BY

Eric Lindquist, DMV,
DABVP, Cert. IVUSS

Liver

The **liver** images submitted revealed subjectively normal liver size, contour, and structure. Parenchymal echogenicity was naturally coarse and hypoechoic to the spleen. Vascular and biliary tracts were of normal volume with no evidence of congestion. The gallbladder presented normal flattened teardrop appearance. Minor physiological debris present. No evidence of mucocele formation.

IMAGING PERFORMED BY

Jenna Walsh, CVT

HOSPITAL NAME

Creswell Vet Hospital

REFERRING VET

Dr. Schlorman

Gastrointestinal

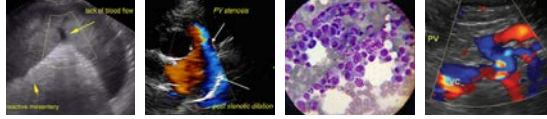
Examination of the **gastrointestinal tract** revealed a stomach and intestine free of stasis, of normal wall thickness, acceptable curvilinear mural detail, and peristaltic activity. Small and large intestine demonstrated normal luminal chyme and stool consistency respectively. No obstructive or overt infiltrative disease was noted. No associated abnormal lymphatic activity was noted.

DATE

10/1/21

INVOICE

26018



PATIENT *Pancreas*

Timer Schlorman

The base and limbs of the **pancreas** were observed to be largely isoechoic to surrounding omental fat. Pancreatic duct and capsular contour were acceptably normal and parenchyma respected normal curvilinear patterns. No overt evidence of active inflammatory or neoplastic disease was noted.

SPECIES

Canine

ULTRASONOGRAPHIC FINDINGS

- Normal abdomen

BREED

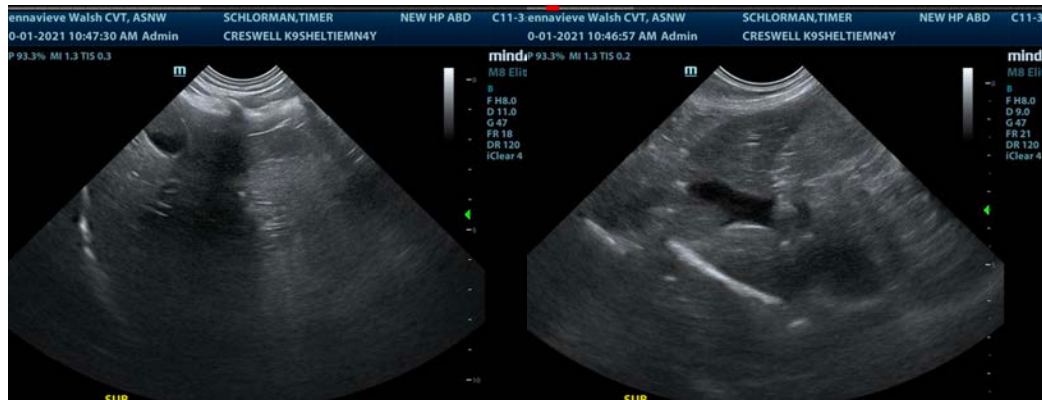
Shetland Sheepdog

INTERPRETATION OF THE FINDINGS & FURTHER RECOMMENDATIONS

No evidence of mucocele formation or other pathology.

SEX

Neutered Male

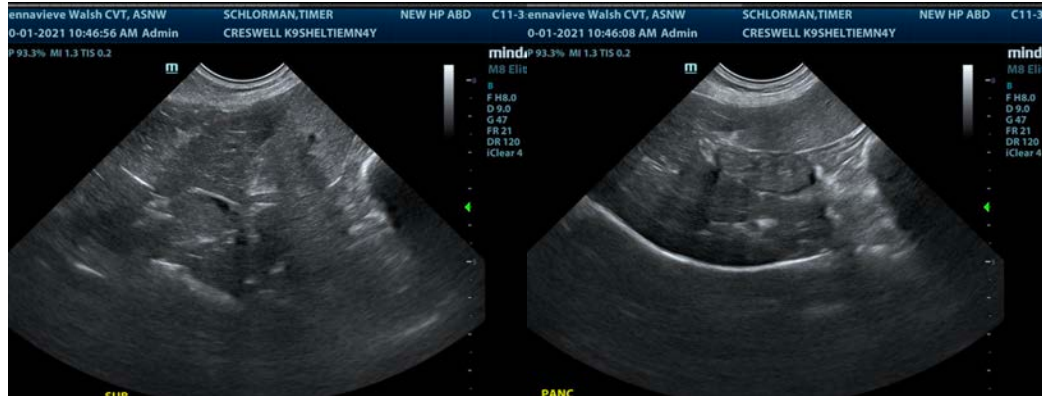


AGE

5 Years

WEIGHT

28 Pounds



INTERPRETED BY

Eric Lindquist, DMV,
DABVP, Cert. IVUS

IMAGING PERFORMED BY

Jenna Walsh, CVT

HOSPITAL NAME

Creswell Vet Hospital

REFERRING VET

Dr. Schlorman

DATE

10/1/21

INVOICE

26018



PATIENT

Timer Schlorman

SPECIES

Canine

BREED

Shetland Sheepdog

SEX

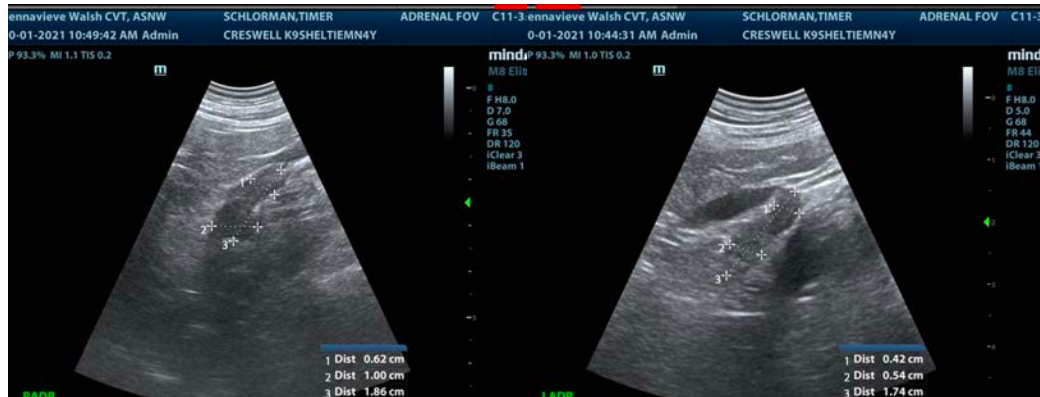
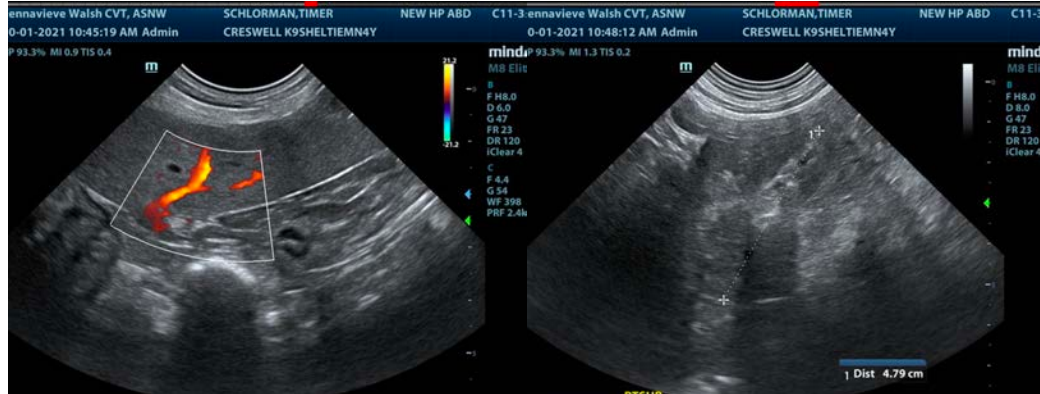
Neutered Male

AGE

5 Years

WEIGHT

28 Pounds



INTERPRETED BY

Eric Lindquist, DMV,
DABVP, Cert. IVUSS

IMAGING PERFORMED BY

Jenna Walsh, CVT

HOSPITAL NAME

Creswell Vet Hospital

REFERRING VET

Dr. Schlorman

DATE

10/1/21

INVOICE

26018

The information and recommendations provided are based on the images presented by the referring veterinarian. No evaluation can be communicated regarding pathology that was not visible in the image/video clips provided.

Thank you for this referral. If the clinical or image interpretation does not parallel your findings or if I can be of any further assistance please contact me.

Eric Lindquist, DMV, DABVP, Cert. IVUSS

CEO of SonoPath.com

Eric.Lindquist@SonoPath.com