


PATIENT

Spike Daniels

SPECIES

Canine

BREED

Chinese Crested

SEX

Neutered Male

AGE

10 Years

WEIGHT

13.8 Pounds

INTERPRETED BY

 Eric Lindquist, DMV
 DABVP, Cert. IVUSS

IMAGING PERFORMED BY

Dr. Ebersole

HOSPITAL NAME

Scanvet

REFERRING VET

Dr. Sanders

INVOICE

26000

DATE

10/1/21

PRESENTING CLINICAL SIGNS

Patient presented to E. clinic for coughing/choking on 9/21. Chest rads showed cardiomegaly and perihilar edema. Received IV Lasix and recommended cardiology work-up. Currently on Lasix 12.5mg BID and Enalapril 1.25mg BID. O has noticed rapid breathing at home. *Had been on a grain-free diet; recently changed to a grain inclusive diet. No sedation given.

Abnormal PE/Chem/CBC/UA Results: PE: clinically much improved, no heart murmur. BAR HW4DX: Neg Rads (from recheck with RDVM, after starting Lasix): Attached, improvement in perihilar edema. VHS 11.5

ULTRASONOGRAPHIC EXAMINATION OF THE HEART

CANINE CARDIAC PARAMETERS	MR VMAX (m/s)	TR VMAX (m/s)	LA/AO (Boon method)	LA/AO (Heart Base; Swe)	FS (%)	EF (%)	EPSS (cm)
NORMAL PARAMETER	4.5-5.5	<2.7	1.3	<1.6	28-40	40-100	<0.6
PATIENT	5.0		1.5	>2.5	15	30	1.0
CANINE CARDIAC PARAMETERS	HR (BPM)	AV VMAX (m/s)	PV MAX (m/s)	BODY WEIGHT (kg)	LA 2D short axis Base view (cm)	LVIDd Avg; 2D and m-mode short axis (cm)	LVIDs Avg; 2D and m-mode short axis (cm)
NORMAL PARAMETER	50-100	0.7-1.7	0.7-1.6				
PATIENT		1.0	0.4		3.5	3.5	

Cardiac Presentation

The cardiac presentation revealed significant volume overload in all 4 chambers with hypocontractility and excessive EPSS. No pericardial or pleural effusion noted. Mitral and tricuspid insufficiency present. Myocardial insufficiency present. Hepatic veins were dilated, indicative of right-sided as well as left-sided heart failure.

ULTRASONOGRAPHIC FINDINGS

- DCM type presentation

INTERPRETATION OF THE FINDINGS & FURTHER RECOMMENDATIONS

The cardiac presentation is consistent with dilated cardiomyopathy. However, given that this is abnormal for the breed, complicating factors such as myocarditis and nutritional cardiomyopathy/taurine deficiency or grain-free diet issues may be playing a role. I recommend adding Pimobendan to the protocol at 0.3 mg/kg BID and continuing with ACE inhibitor 0.5 mg/kg SID progressing to BID, Lasix 2-3 mg/kg BID, and Spironolactone 1-2 mg/kg BID. Taurine supplementation warranted. Taurine levels should be indicated and assessment for possible causes of myocarditis would also be indicated such as bartonella, lyme disease and similar. Prognosis is guarded. Recheck echo in one week. The patient may necessitate Sildenafil as well. Assessment of BUN, creatinine, USG, chest radiographs and blood pressure as well as clinical exam ideal in 7-10 days. Basal respiratory rate should be <20/min.



PATIENT

Spike Daniels

SPECIES

Canine

BREED

Chinese Crested

SEX

Neutered Male

AGE

10 Years

WEIGHT

13.8 Pounds

INTERPRETED BY

Eric Lindquist, DMV
DABVP, Cert. IVUSS

IMAGING PERFORMED BY

Dr. Ebersole

HOSPITAL NAME

Scanvet

REFERRING VET

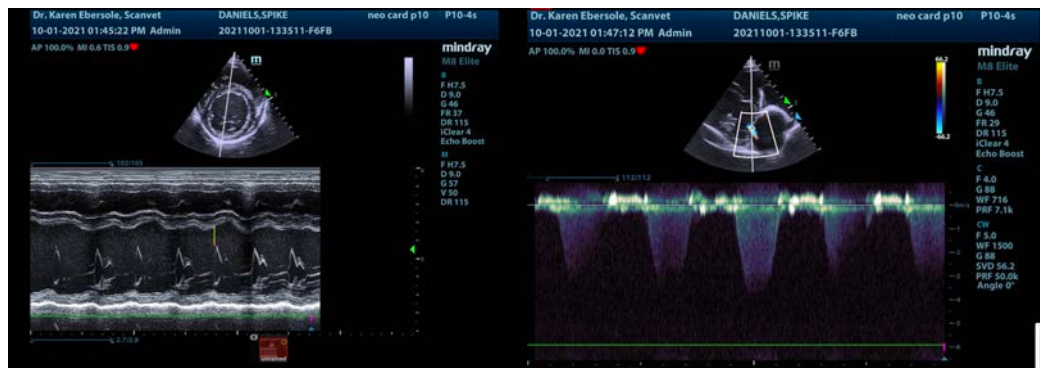
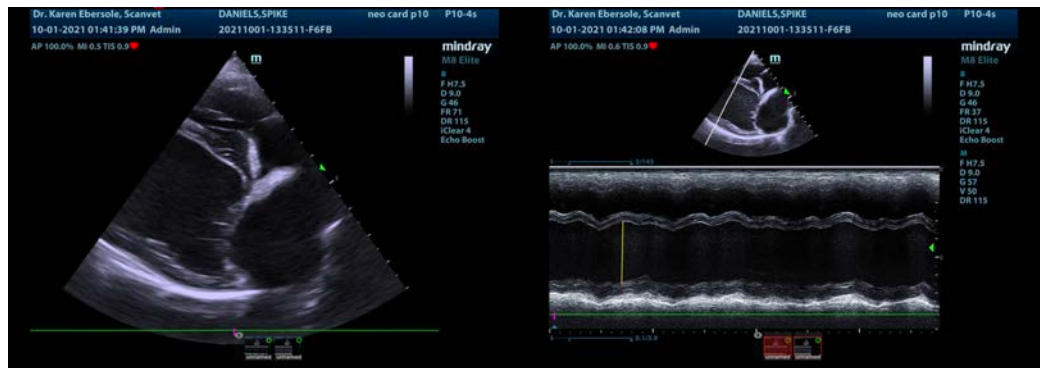
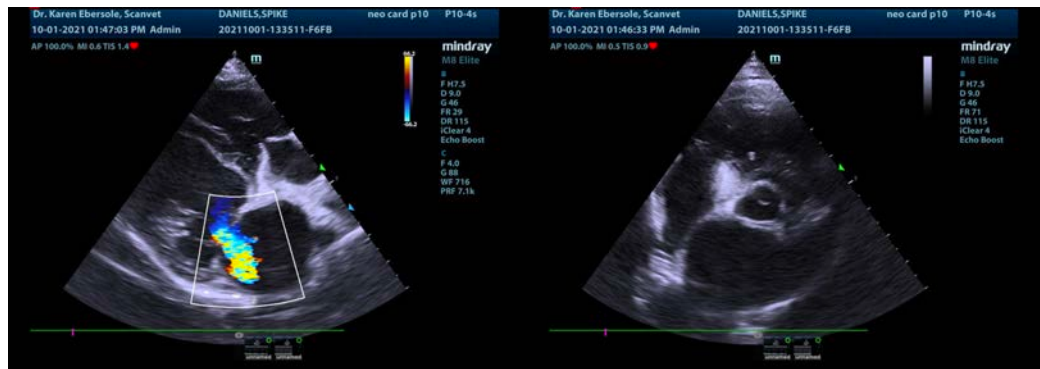
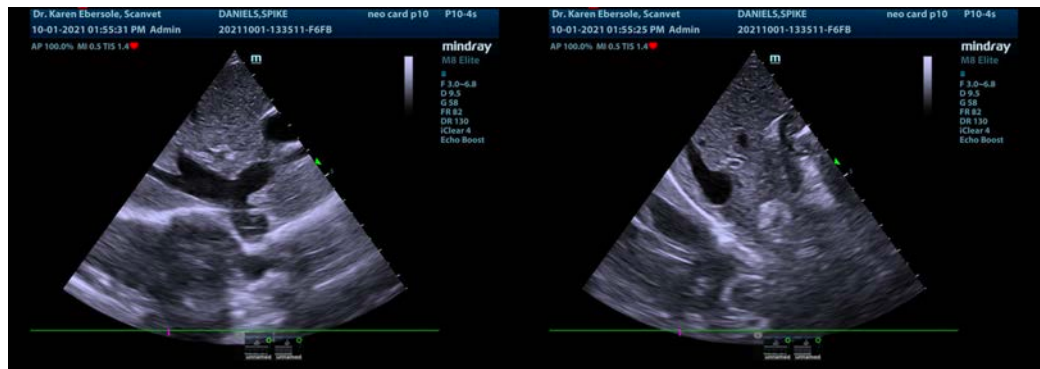
Dr. Sanders

INVOICE

26000

DATE

10/1/21





PATIENT

Spike Daniels

SPECIES

Canine

BREED

Chinese Crested

SEX

Neutered Male

AGE

10 Years

WEIGHT

13.8 Pounds

INTERPRETED BY

Eric Lindquist, DMV
DABVP, Cert. IVUSS

IMAGING PERFORMED BY

Dr. Ebersole

HOSPITAL NAME

Scanvet

REFERRING VET

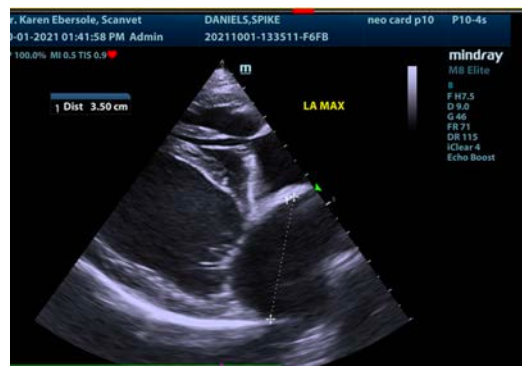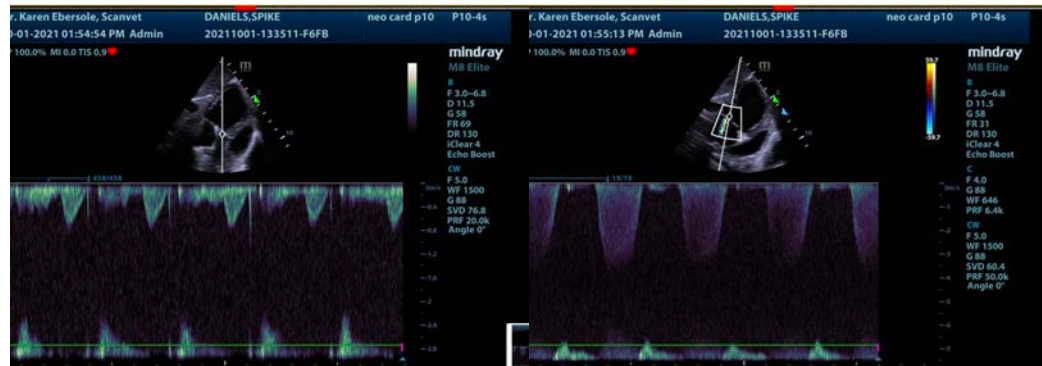
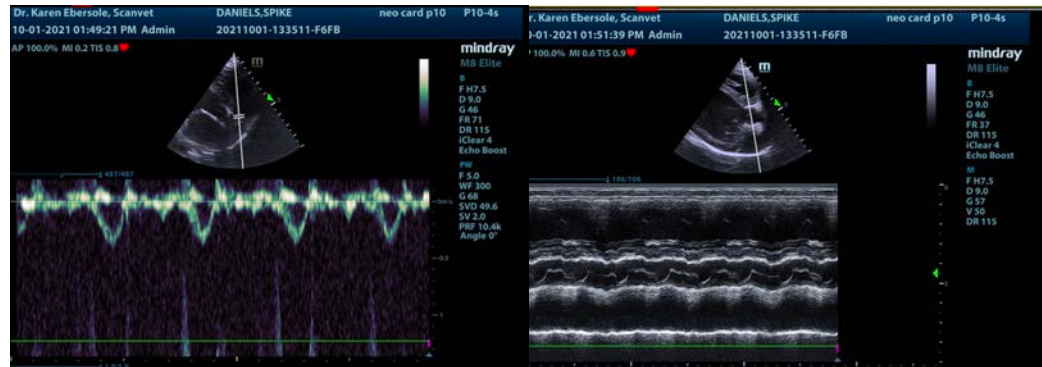
Dr. Sanders

INVOICE

26000

DATE

10/1/21



The information and recommendations provided are based on the images presented by the referring veterinarian. No evaluation can be communicated regarding pathology that was not visible in the image/video clips provided.

Thank you for this referral. If the clinical or image interpretation does not parallel your findings or if I can be of any further assistance please contact me.

Eric Lindquist, DMV, DABVP, Cert. IVUSS, CEO of SonoPath.com
info@SonoPath.com