


PATIENT

Rooney Ducharme

PRESENTING CLINICAL SIGNS

Dyspneic referred from GP with diagnosis of aspiration pneumonia. History does not support. Suspect infiltrative pulmonary process or mediastinal mass

Abnormal PE/Chem/CBC/UA Results: Non diagnostic

SPECIES

Canine

ULTRASONOGRAPHIC EXAMINATION OF THE HEART
BREED

German Shepherd

SEX

Spayed Female

AGE

12 Years

WEIGHT

32 kg

CANINE CARDIAC PARAMETERS	MR VMAX (m/s)	TR VMAX (m/s)	LA/AO (Boon method)	LA/AO (Heart Base; Swe)	FS (%)	EF (%)	EPSS (cm)
NORMAL PARAMETER	4.5-5.5	<2.7	1.3	<1.6	28-40	40-100	<0.6
PATIENT			NM		30		NM
CANINE CARDIAC PARAMETERS	HR (BPM)	AV VMAX (m/s)	PV MAX (m/s)	BODY WEIGHT (kg)	LA 2D short axis Base view (cm)	LVIDd Avg; 2D and m-mode short axis (cm)	LVIDs Avg; 2D and m-mode short axis (cm)
NORMAL PARAMETER	50-100	0.7-1.7	0.7-1.6				
PATIENT						3.77	

INTERPRETED BY

 Eric Lindquist, DMV
 DABVP, Cert. IVUSS

Cardiac Presentation

A large amount of respiratory interference was noted in this patient. The heart appeared volume contracted. Contractility appeared normal. Left ventricular internal diameter was normal. Microconsolidations and B-lines are noted in the lung fields, consistent with primary respiratory disease. Minimal visibility of the heart noted owing to lung interference. However, wall structure, right atrium and auricle, pericardium were all normal. No evidence of neoplasia. Tissue consolidation noted in the right cranial thorax, possibility lymph node and lung origin. Slight areas of pleural effusion also noted.

IMAGING PERFORMED BY

Dr. Belan

HOSPITAL NAME

Chris Belan VS

ULTRASONOGRAPHIC FINDINGS

- Suspect thoracic neoplastic process – non-cardiogenic

INTERPRETATION OF THE FINDINGS & FURTHER RECOMMENDATIONS

Primary lung disease such as pneumonitis/pneumonia, pulmonary thromboembolic disease or pulmonary neoplasia should be considered. Lung lobe torsion possible. Ultrasound guided FNA of the accessible tissue consolidation indicated. Pleurocentesis and cytospin warranted. Treatment should be based on cytospin results.

REFERRING VET

Dr. Zhao

INVOICE

25999

DATE

10/1/21



PATIENT

Rooney Ducharme

SPECIES

Canine

BREED

German Shepherd

SEX

Spayed Female

AGE

12 Years

WEIGHT

32 kg

INTERPRETED BY

Eric Lindquist, DMV
DABVP, Cert. IVUSS

IMAGING PERFORMED BY

Dr. Belan

HOSPITAL NAME

Chris Belan VS

REFERRING VET

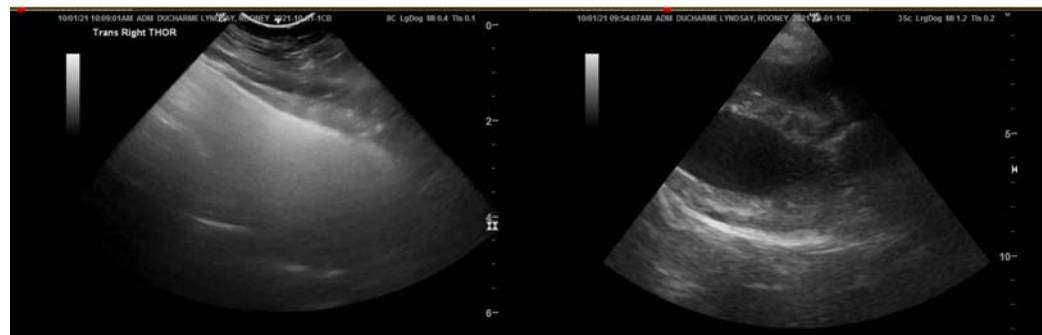
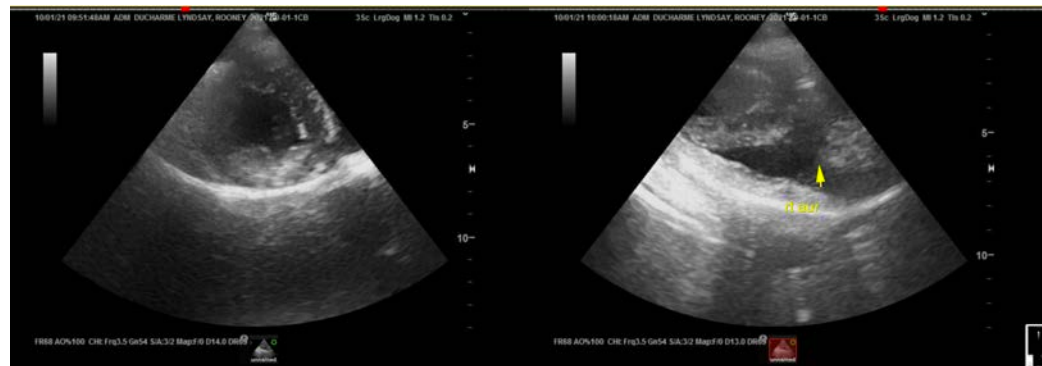
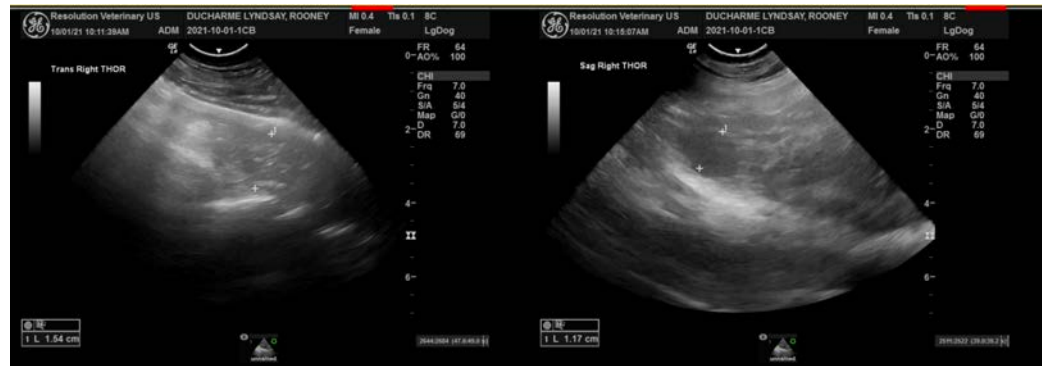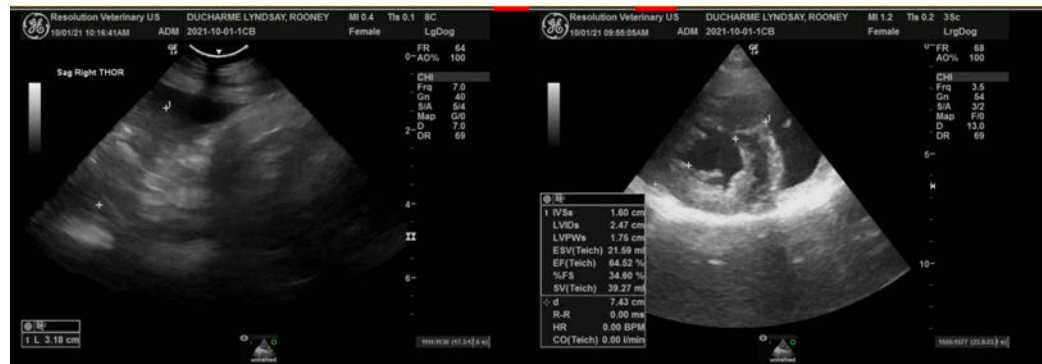Dr. Zhao

INVOICE

25999

DATE

10/1/21





PATIENT

Rooney Ducharme

The information and recommendations provided are based on the images presented by the referring veterinarian. No evaluation can be communicated regarding pathology that was not visible in the image/video clips provided.

SPECIES

Canine

Thank you for this referral. If the clinical or image interpretation does not parallel your findings or if I can be of any further assistance please contact me.

BREED

German Shepherd

Eric Lindquist, DMV, DABVP, Cert. IVUSS, CEO of SonoPath.com

info@SonoPath.com

SEX

Spayed Female

AGE

12 Years

WEIGHT

32 kg

INTERPRETED BY

Eric Lindquist, DMV
DABVP, Cert. IVUSS

**IMAGING
PERFORMED BY**

Dr. Belan

HOSPITAL NAME

Chris Belan VS

REFERRING VET

Dr. Zhao

INVOICE

25999

DATE

10/1/21