

PATIENT PRESENTING CLINICAL SIGNS

Myguyyo Vanba-Scott

Murmur Gr 2, 75/40 56MAP 85\44 63 MAP,108BPM/ 15bpm/ 85/44 63MAP. No current meds.
Abnormal PE/Chem/CBC/UA Results: n.a

SPECIES ULTRASONOGRAPHIC EXAMINATION OF THE HEART

Canine

BREED

American Bulldog

SEX

Intact Male

AGE

7 Months

WEIGHT

19.5 kg

CANINE CARDIAC PARAMETERS	MR VMAX (m/s)	TR VMAX (m/s)	LA/AO (Boon method)	LA/AO (Heart Base; Swe)	FS (%)	EF (%)	EPSS (cm)
NORMAL PARAMETER	4.5-5.5	<2.7	1.3	<1.6	28-40	40-100	<0.6
PATIENT		1.5	NM	1.2	20	40	0.2
CANINE CARDIAC PARAMETERS	HR (BPM)	AV VMAX (m/s)	PV MAX (m/s)	BODY WEIGHT (kg)	LA 2D short axis Base view (cm)	LVIDd Avg; 2D and m-mode short axis (cm)	LVIDs Avg; 2D and m-mode short axis (cm)
NORMAL PARAMETER	50-100	0.7-1.7	0.7-1.6				
PATIENT		2.3	1.45		2.94	3.66	

Cardiac Presentation

INTERPRETED BY

Eric Lindquist, DMV DABVP, Cert. IVUSS

IMAGING PERFORMED BY

Crystal Hill

HOSPITAL NAME

Graham AH

REFERRING VET

Dr. Graham

INVOICE

26015

DATE

10/1/21

The echocardiogram in this patient demonstrated normal **left atrial** size based on 3 separate methods of LA evaluation. The cranial and caudal **mitral valve** leaflets presented normal linear structure, extension in systole, and union in diastole with normal kinesis. The **left ventricle** presented thicknesses with linear contour and was not dilated nor restricted. The **myocardium** presented normal echogenicity without subjective evidence of significant fibrotic or ischemic disease. **Contractility** of the ventricular walls was adequate and in normal range for this patient evidenced by the fractional shortening measurement and subjective evaluation of the different regions of the myocardium. **Aortic velocity** was mildly excessive. The aortic valve appeared mildly thickened. Turbulence was noted at the left ventricular outflow tract. The **right atrium** and auricle revealed normal size, structure and content. No evidence of masses was noted. Trivial **tricuspid** insufficiency noted at 1.5 m/sec. The **right ventricle** was of normal size (1/3 diameter of LV), chordae structure, myocardial echogenicity and thickness. Turbulence was noted at the pulmonic outflow as well on color flow assessment, yet spectral doppler revealed acoustic interference. No visible **pericardial** or free pleura fluid was noted. The cranial **mediastinum and pericardial and extra-cardiac regions** were free of masses in the visible window. A large amount of respiratory interference noted in this patient.

ULTRASONOGRAPHIC FINDINGS

- Suspect subaortic stenosis

INTERPRETATION OF THE FINDINGS & FURTHER RECOMMENDATIONS

Recommend sedation of this patient with heavy Torbutrol pre-med +/- Propofol and further imaging of the left ventricular outflow tract and right ventricular outflow tract in particular to assess for subaortic +/- pulmonic stenosis.



PATIENT
Myguyyo Vanba-Scott

SPECIES
Canine

BREED
American Bulldog

SEX
Intact Male

AGE
7 Months

WEIGHT
19.5 kg

INTERPRETED BY
Eric Lindquist, DMV
DABVP, Cert. IVUS

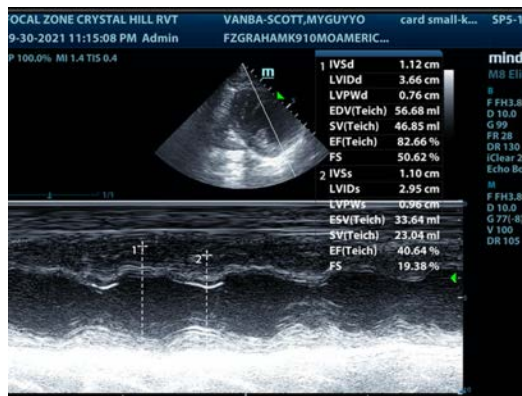
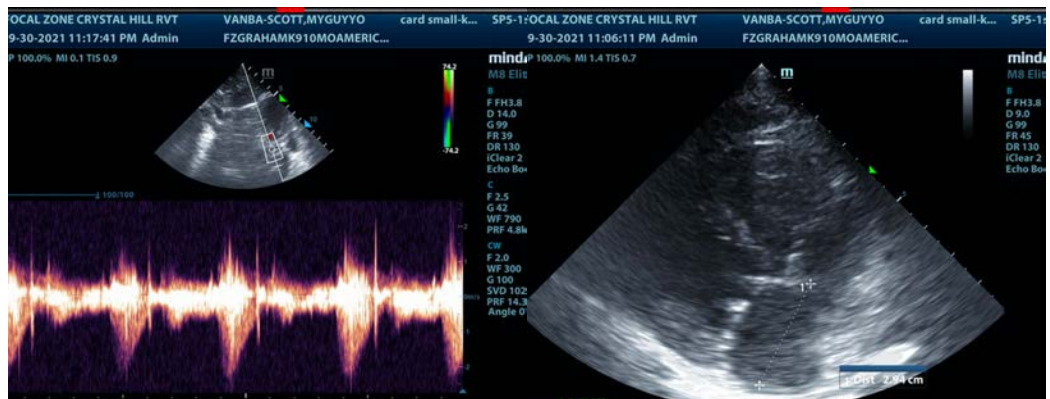
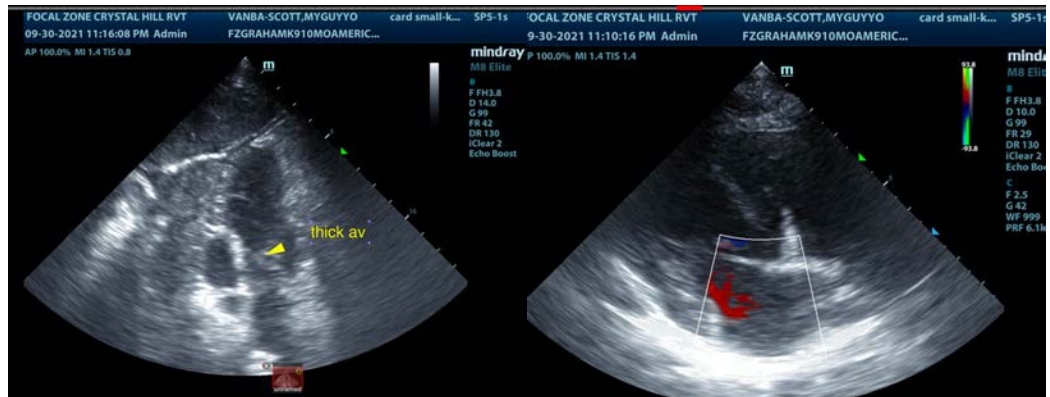
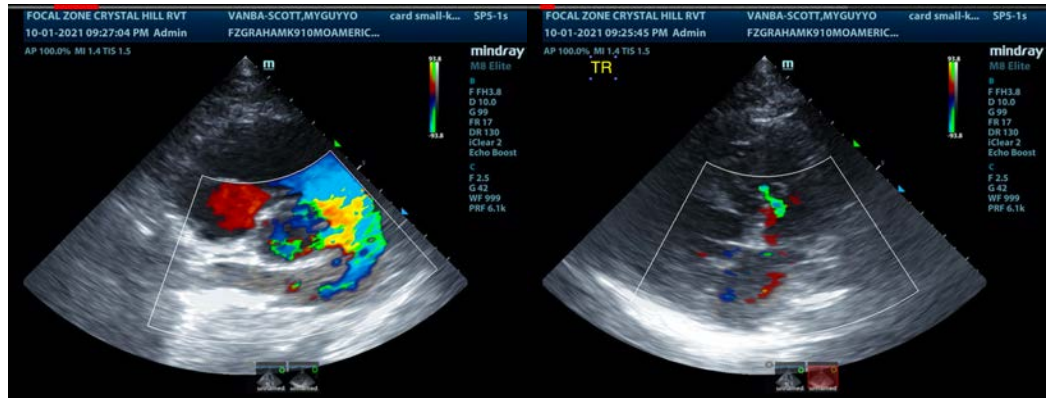
IMAGING PERFORMED BY
Crystal Hill

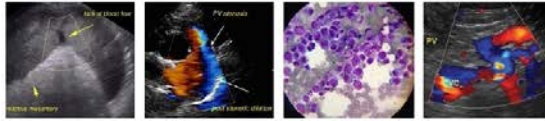
HOSPITAL NAME
Graham AH

REFERRING VET
Dr. Graham

INVOICE
26015

DATE
10/1/21





PATIENT

Myguyyo Vanba-Scott

The information and recommendations provided are based on the images presented by the referring veterinarian. No evaluation can be communicated regarding pathology that was not visible in the image/video clips provided.

SPECIES

Canine

Thank you for this referral. If the clinical or image interpretation does not parallel your findings or if I can be of any further assistance please contact me.

BREED

American Bulldog

Eric Lindquist, DMV, DABVP, Cert. IVUSS, CEO of SonoPath.com
Eric.Lindquist@SonoPath.com

SEX

Intact Male

AGE

7 Months

WEIGHT

19.5 kg

INTERPRETED BY

Eric Lindquist, DMV
DABVP, Cert. IVUSS

IMAGING PERFORMED BY

Crystal Hill

HOSPITAL NAME

Graham AH

REFERRING VET

Dr. Graham

INVOICE

26015

DATE

10/1/21